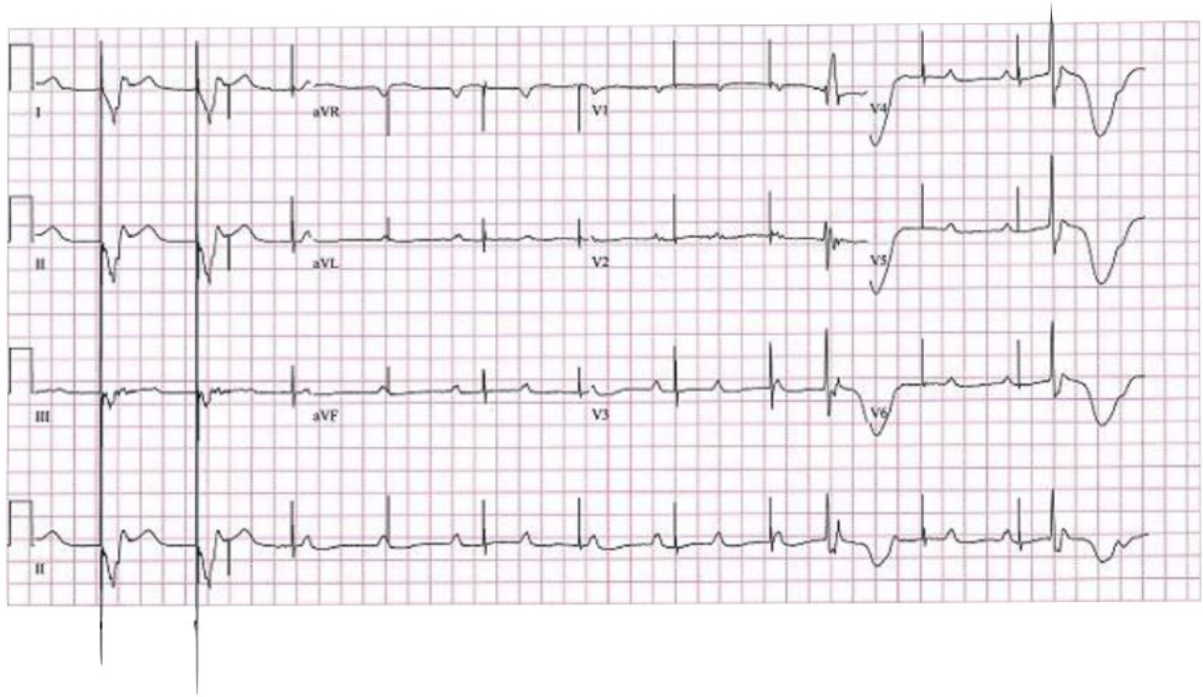


SAQ 8

A 16 year old boy with a congenital heart problem presents to ED with episodes of syncope. This is his ECG.



a) Describe the ECG (5 marks)

Paced rhythm rate 75 bpm

Loss of capture

Period of ventricular standstill

Occasional ventricular ectopic/escape beats

P waves rate 75 – 100 bpm, complete heart block

b. Name 5 possible causes for this ECG (5 marks)

Lead breakage or displacement causing pacemaker failure

Fibrosis causing pacemaker failure

Electrolyte abnormality

Toxicological causes – Ca channel/B blocker/digoxin toxicity

Failure to capture/needs check of threshold for capture