

## THE FRONT AND SIDES OF THE THIGH

- Function of the pelvic girdle:
  - Transmits weight of trunk to lower limb
  - Provides boney framework for attachment of muscles which act on proximal lower limb.
- Hip = innominate bone
- Acetabulum = socket of hip joint, in innominate bone
- Acetabulum is composed of:
  - Ischium
  - Ilium
  - Pubis
- Separated by **triradiate cartilage** in children, in Y-shape formation.
- During puberty, triradiate cartilage disappears.
- Triradiate cartilage allows the acetabulum to alter in shape as femur head changes shape in puberty.
  
- Adults – acetabulum is deep hemispherical boney socket.
- Hip joint = acetabulum + head of femur
- Hip joint is a **ball and socket joint**

### **FEMUR:**

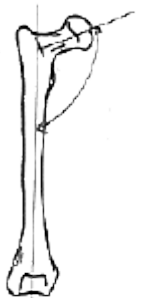
- Ball shaped head
- Narrow oblique neck (susceptible to fracture)
  
- Head develops from **2ndry ossification centre** which appears during the 1<sup>st</sup> year of postnatal life.
- Fusion of the head with the shaft occurs at about 16-18 years old.

### **Angle of inclination:**

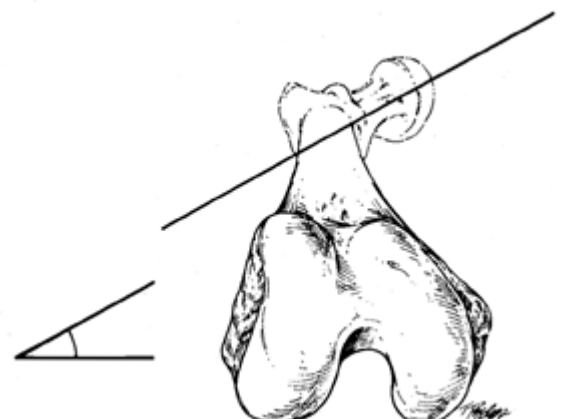
- The **angle of inclination** is the angle between the neck and shaft of the femur
- Should be between **116° – 140°**
- Congenital and aquired conditions can affect the angle of inclination
- < 116° – **coxa vara**
- > 140° – **coxa valga**

### **Angle of femoral torsion:**

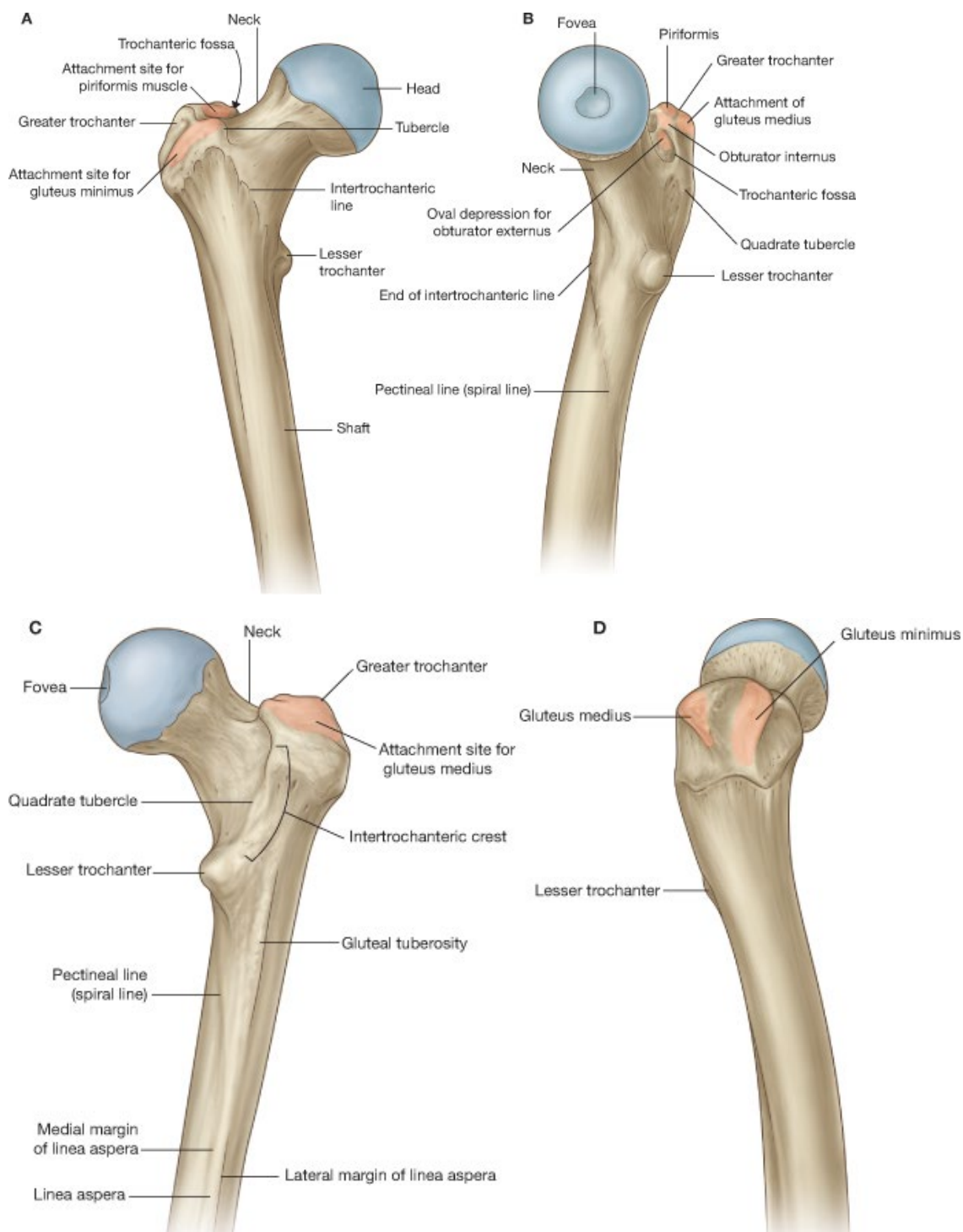
- If line is drawn between the **lateral and medial femoral condyles**.
- Shaft is viewed 'end-on' and it can be seen that the femoral neck does not project in this line.
- Projects **anteromedially** and angle of approx. **20°**
- If this is altered – **torsion** is said to exist.



ADULT  
(126 - 128)



- Upper end of the femoral shaft has 2 bony prominences: **greater & lesser trochanters**
- Anteriorly, the **intertrochanteric line** links the 2 trochanters.
- Posteriorly, the trochanters are linked by a more marked **intertrochanteric crest**.
- **Trochanteric fossa** exists in the back of the greater trochanter, at the foot of the intertrochanteric crest.
- No bony landmarks on the front of the shaft of the femur
- Back of the shaft has long rough crest of bone – **linea aspera**
- Above, the linea aspera divides into:
  - **Medially: spiral line**
  - **Laterally: gluteal tuberosity**
- Below, the linea aspera divides into:
  - **2 supracondylar lines**

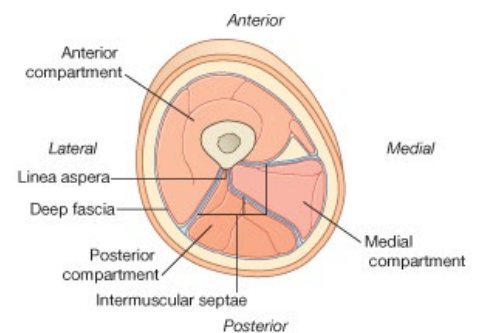
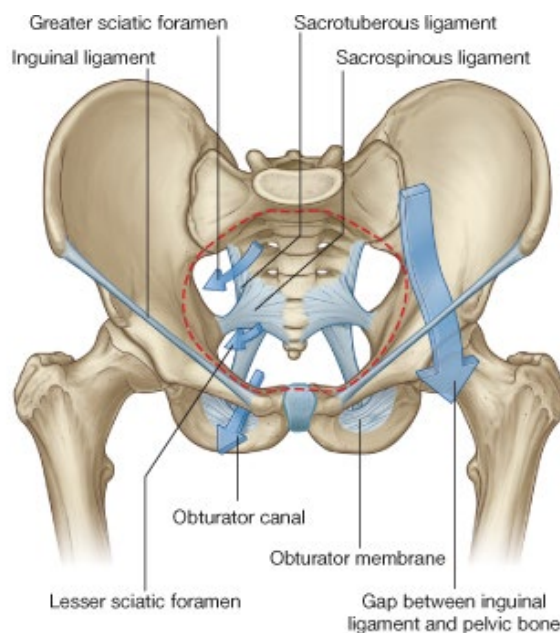


**Looking at femur anteriorly:**

- Front of greater trochanter = **gluteus minimus**
- Back of greater trochanter = **gluteus medius**

**NERVES AND VESSELS IN LOWER LIMB:**

- Nerves and vessels enter the lower limb in one of 3 ways:
- **Femoral nerve & vessels:**
- Travel in front of the thigh (which is mainly extensors of the knee joint)
- Enters thigh through elongated interval between inguinal ligament and the bone of the pelvis below it.
- **Obturator nerves and vessels to medial aspect of thigh:**
- Muscles on medial thigh are adductors of the hip joint.
- Enter and leave this part of the thigh through the obturator foramen
- **Sciatic nerve & gluteal vessels to posterior thigh:**
- Mainly extensor muscles of the thigh, & flexors of the knee
- Travels through the greater sciatic foramen

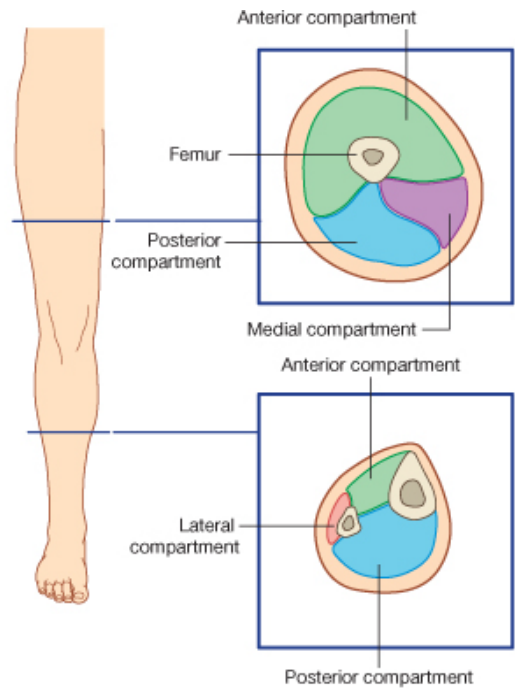


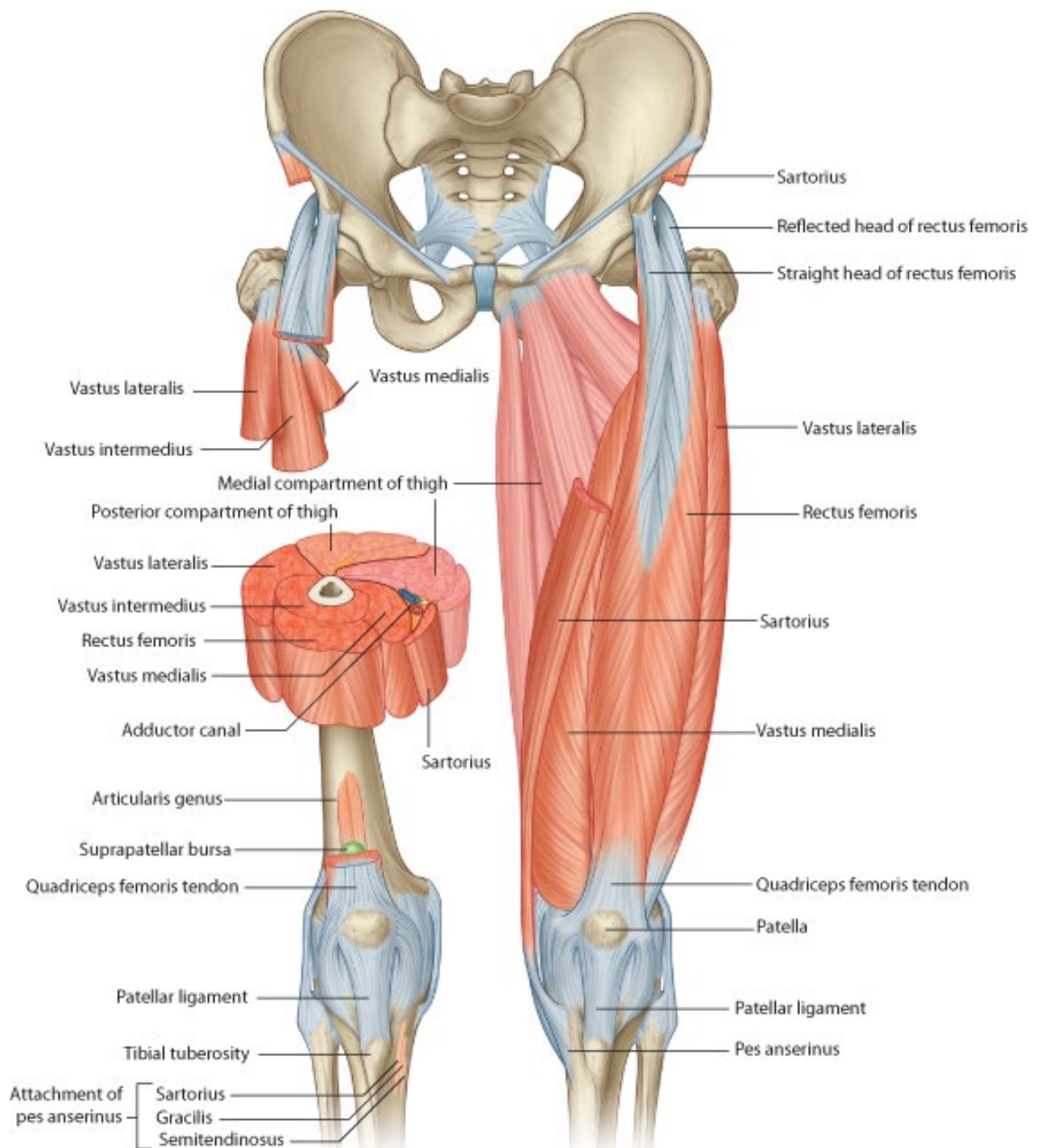
**REGIONAL DIVISIONS OF THE THIGH:**

- Front & sides
- Gluteal region
- Hip joint
- Popliteal region (behind knee)

**FRONT AND SIDES OF THE THIGH:**

- **Medial muscles:**
  - **Adductors of hip joint**
  - **Weak medial rotators of femur**
  - Supplied mainly by **obturator nerve**
- Adductor muscles form a flat muscular septum on medial side of thigh.
- **Lateral muscle:**
- Fibrous septum extends from linea aspera posteriorly, between the muscles to the deep fascia of the thigh.
- Sheet of fascia is called the **lateral intermuscular septum**
- Lateral intermuscular septum → shaft of femur → sheet of adductor muscle
- Together form **musculo-osseofascial partition** stretching across the thigh.
- In front of partition: extensor mass of muscle
- Behind the partition: flexor mass of muscle





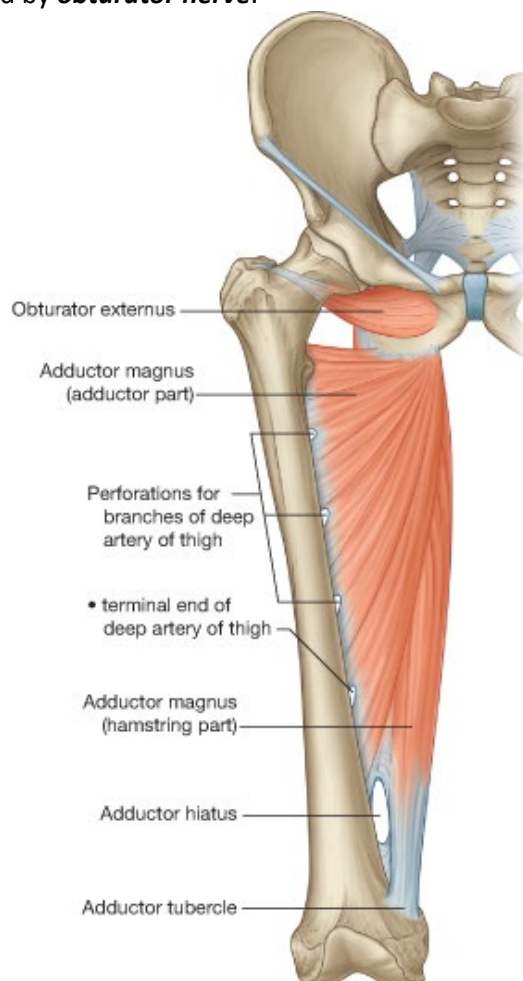
### ADDUCTOR MUSCLES:

- **Medial muscles of the thigh**
- Arise from the **pubis + ischium**
- Stretch to **back of femur** (except gracilis which inserts into medial aspect of tibia)
- Arranged as 3 strata:

### Deepest strata

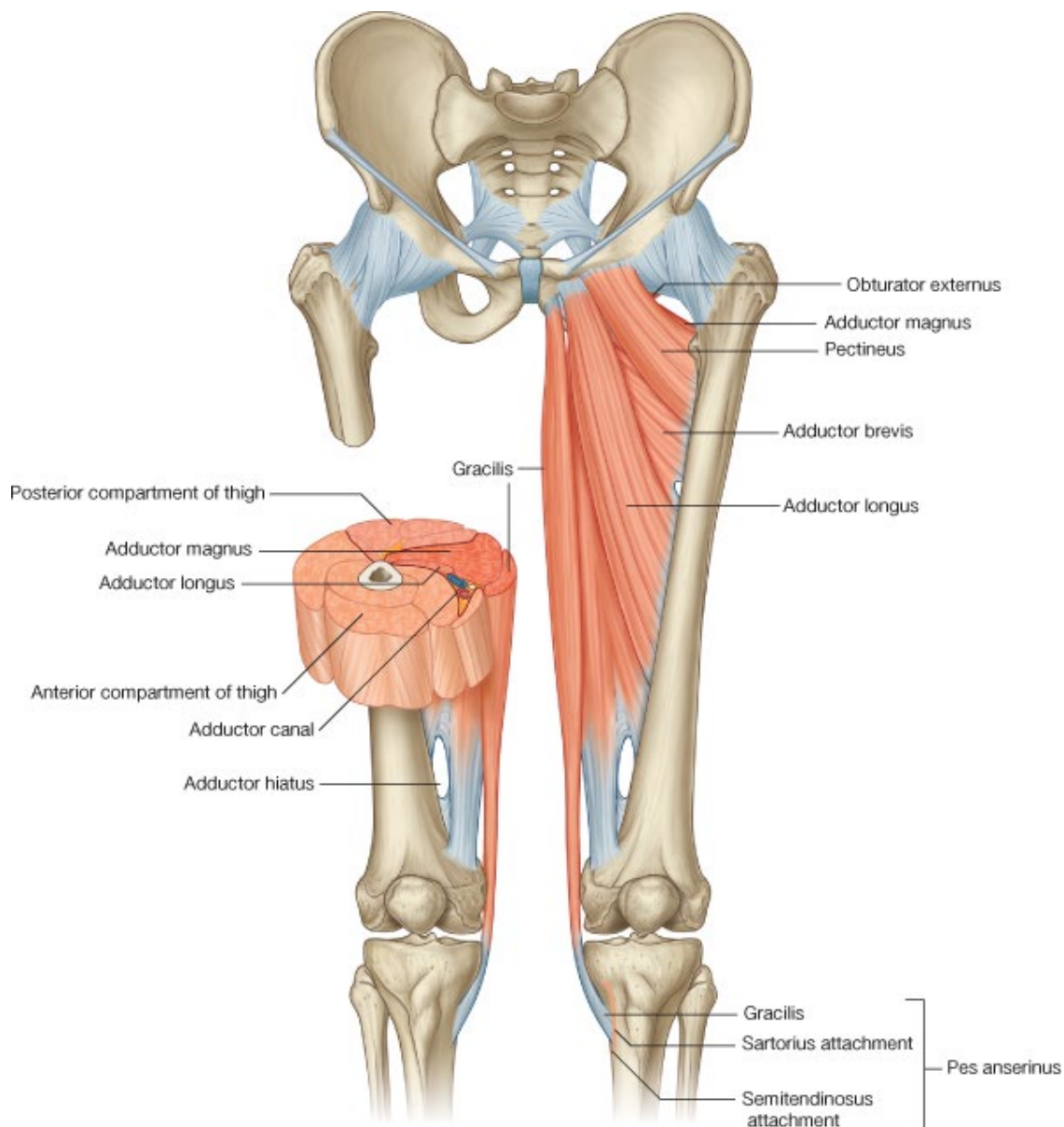
- Bulkiest & most complete
- Mainly **adductor magnus**

- Arises from:
  - Inferior pubic ramus
  - Ischial tuberosity
- Inserts into
  - Linea aspera & supracondylar ridge
  - Adductor tubercle on lower femur shaft
- Elongated gap in lower adductor magnus – **adductor hiatus**
- **Femoral vessels** pass through adductor hiatus to pass from front of thigh to back of knee.
- Action: **adduction of thigh at hip joint**
- Innervation: **obturator nerve**
- Lower adductor magnus can also weakly extend the thigh.
- These muscle fibres are supplied from behind by the **sciatic nerve** (normal adductor innervation is obturator nerve)
- **Obturator externus**
- Arises from external surface of obturator membrane & bone surrounding obturator foramen
- Passes below and behind the neck of femur and the hip joint, to insert into the **trochanteric fossa**.
- **Lateral rotator of the thigh**
- Supplied by **obturator nerve**.





- **Gracilis**
- Long slender muscle skirting most medial side of adductor group
- Extends from **pubis** → past knee joint → **tibia**
- Spans both hip and knee joints:
  - **Adducts hip joint**
  - **Flexes knee joint**
- Supplied by **obturator nerve**



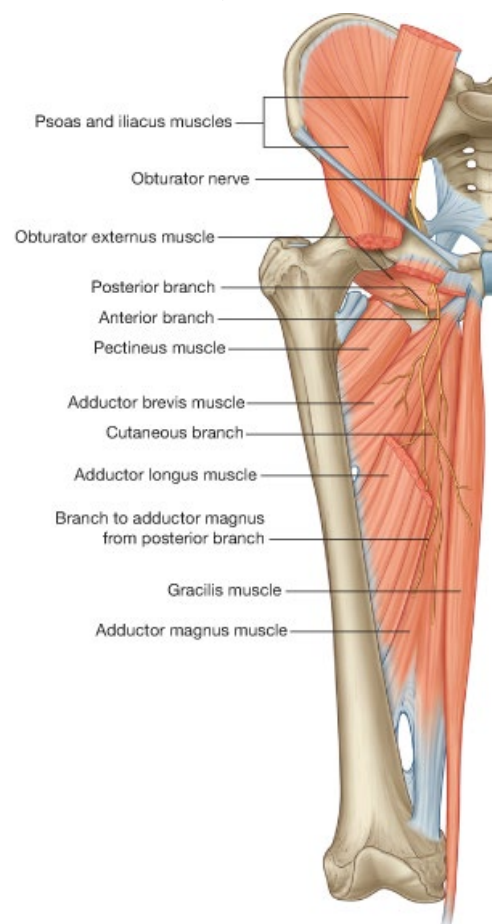
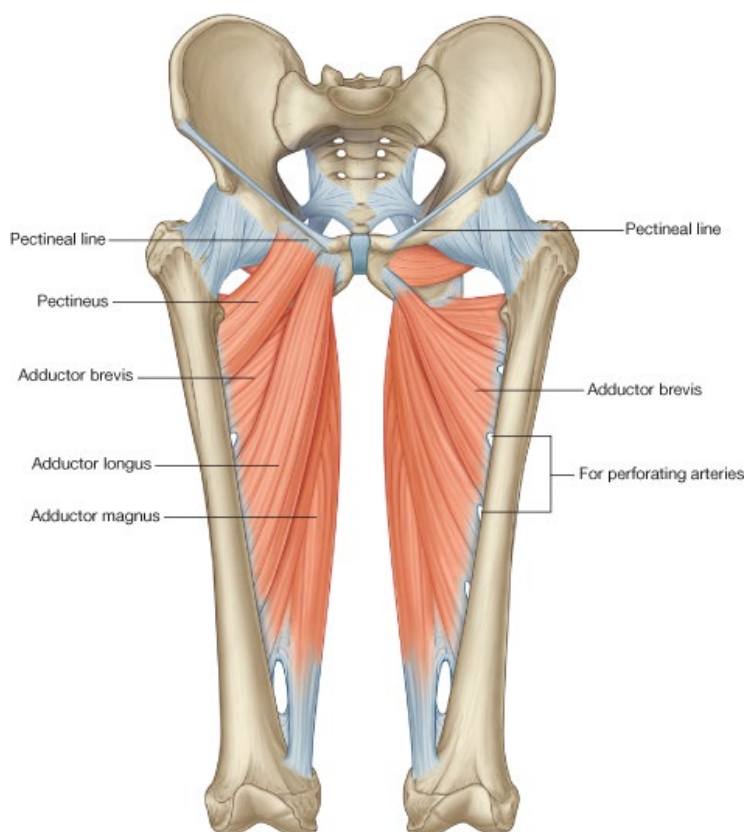
### **Middle stratum:**

- Small; only 1 muscle
- **Adductor brevis**
- Arises from **pubic arch below pubic symphysis**.
- Fans out to insert into **linea aspera** on the back of the femur.
- **Adductor** of the femur

- Supplied by **obturator nerve**.

### **Superficial stratum:**

- 2 muscles
- **Pectineus**
- **Adductor longus**
- Both triangular shape
- Base of pectineus arises from pubis
- Apex of adductor longus arises from pubis
- Both are flat muscles & pass side by side to back of femur.
- **Pectineus** inserts by small tendon between lesser trochanter & linea aspera
- **Adductor longus** inserts into linea aspera itself.
- Both are adductors
- **Pectineus** is supplied by the femoral nerve
- **Adductor longus** is supplied by obturator nerve (the normal adductor nerve)



### **NEUROVASCULAR BUNDLE OF ADDUCTOR MUSCLES:**

- Obturator nerve and vessels
- **Obturator nerve** is a branch of the lumbar plexus in posterior abdominal wall – **anterior divisions of L2,3,4**
- **Obturator artery** arises from internal iliac artery on inner pelvic wall
- Both nerve & vessel pass through the **obturator foramen**.

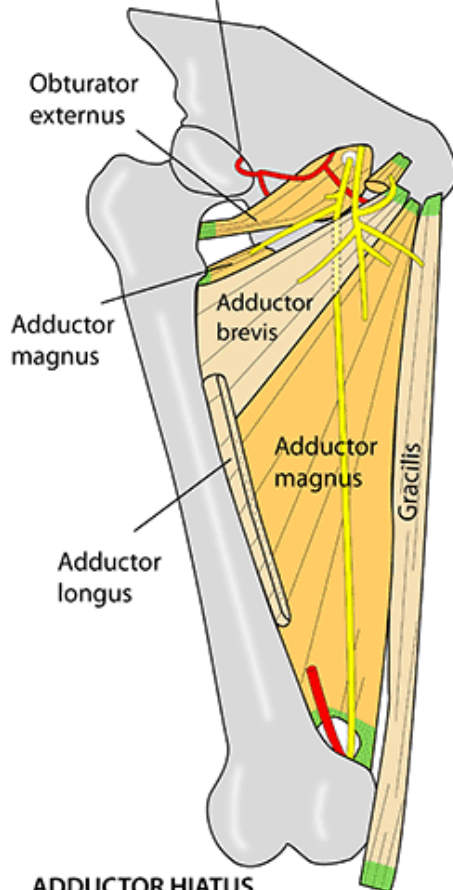


- **Obturator nerve** divides immediately **either side of the adductor brevis**:
  - **Anterior division of obturator nerve**
  - **Posterior division of obturator nerve**
- **Anterior division** passes over top of obturator externus
- Gains plane between superficial and middle strata of adductor muscles.
- Supplies:
  - **Adductor brevis**
  - **Adductor longus**
  - **Pectineus**
  - **Gracilis**
- **Posterior division**
  - Pierces obturator externus
  - Gains plane between middle and deep strata of adductor muscles
  - Supplies the deep muscles of the adductor group:
    - **Obturator externus**
    - **Adductor magnus**
- **Obturator artery** also splits into anterior and posterior division, but these just form a mesh around obturator membrane.
- Branch of posterior division supplies an important artery to the femur head via the acetabular notch – the **artery of the ligament of the head of the femur**

## MEDIAL THIGH

Branch of obturator artery via ligamentum teres to fovea of head of femur

For details of muscles, please see muscle section in the book - Instant Anatomy, by R H Whitaker & N R Borley. 4th edition. Wiley-Blackwell 2010



### OBTURATOR NERVE

From anterior divisions of L2,3,4

**Anterior branch:**  
Lies between adductors longus & brevis, contributes to subsartorial plexus for medial thigh skin, supplies gracilis, adductors longus, brevis

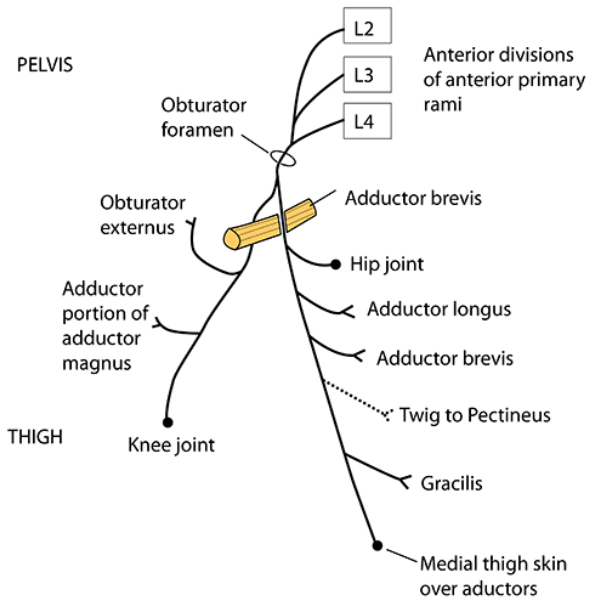
**Posterior branch:**  
Lies between adductors brevis & magnus, supplies adductor portion of adductor magnus, obturator externus & knee joint via a small branch that passes through the adductor hiatus

Medial collateral ligament of knee is probably a remnant of the tendon of the hamstring portion of adductor magnus that was originally attached to the tibia

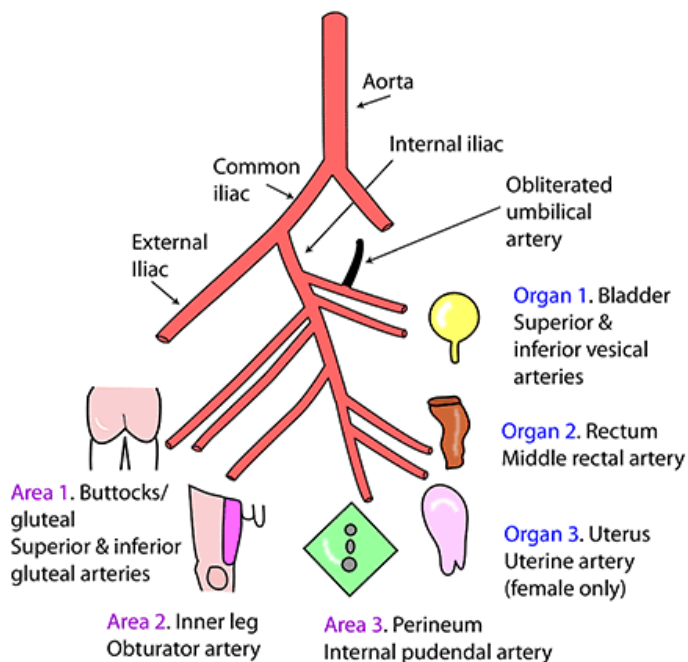
### ADDUCTOR HIATUS

Transmits femoral artery, femoral vein, the small genicular branch of the posterior branch of the obturator nerve. The saphenous nerve may pass through it, but if so, then it immediately returns more superficially so that it does not enter the popliteal fossa

# OBTURATOR NERVE



## BRANCHES OF THE INTERNAL ILIAC ARTERY



A simple representational diagram of the branches of the internal iliac artery. An easy way to remember them is to think of them in 2 groups, each with 3 branches. **Group 1** has 3 branches to organs (bladder, rectum and uterus) and **Group 2** has 3 branches to areas (buttocks/gluteal, adductor compartment and perineum).

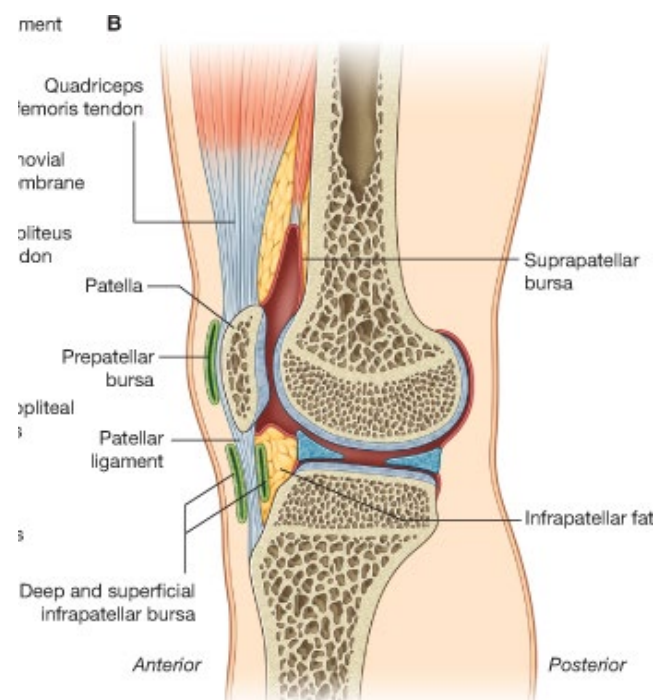
- ILIOLUMBAR:** Passes laterally, behind obturator nerve & psoas. Lumbar branch to psoas, quadratus lumborum & spine. Iliac branch to iliacus, iliac bone, anastomosis at anterior superior iliac spine
- LATERAL SACRAL:** Passes inferiorly, lateral to anterior sacral foramina & anterior to nerve roots & piriformis
- ARTERY TO VAS:** Usually off superior vesical (or inferior vesical)
- UTERINE ARTERY:** In female it largely replaces middle rectal (or inferior vesical)

### EXTENSOR MUSCLES (of knee joint):

- In front of the musculo-osseofascial partition in thigh
- Mostly extensors of **knee joint (not the hip joint)**.
- The lateral intermuscular septum & adductor sheath both arise from back of the femur
- Δ room from the extensor muscle mass to arise from both front and side of the femur shaft.
  
- Dominant extensor of the knee is the **quadriceps femoris**
- Quadriceps femoris is composed of 4 parts:
  - **Vastus medialis**
  - **Vastus intermedius**
  - **Vastus lateralis**
  - **Rectus femoris (more superficial)**
  
- Unite to form strong **common tendon of the quadriceps**
- Tendon inserts into the patella & continues, to be anchored in tibial tuberosity by the ligamentum patellae.
- Patella is a sesamoid bone and can be removed without disrupting extension of knee (may be done after badly fracturing patella).

### **Bursa of the patella:**

- Several bursa found around patella.
- **Prepatellar bursa** found just deep to the skin in front of lower patella.
- Allows movement of skin over patella bone
- Frequent kneeling → **housemaid's knee** – chronic enlargement of the prepatellar bursa
- **Subcutaneous Infrapatellar bursa** lies deep to the skin on upper part of tibia
- **Deep infrapatellar bursa** lies between ligamentum patellae & upper tibia
  - Allows movement of ligamentum patella over tibia – preventing friction during knee movement.
- **Suprapatellar bursa** is extension of synovial membrane of knee joint.
- Insinuates between common quadriceps tendon and front of femur.



### **Origins of the quadriceps muscles:**

- **Vastus intermedius** arises from large area on front and sides of the femoral shaft
- **Vastus medialis & lateralis** have linea origins from the linea aspera on the back of the femur.
- **Rectus femoris** forms the superficial belly of the muscle and arises from the **anterior inferior iliac spine of the pelvis and the bone above acetabulum** (not the femur like the other 3 muscles).

### **Action of the quadriceps:**

- Extend the knee joint
- Rectus femoris can also act as *hip flexor*

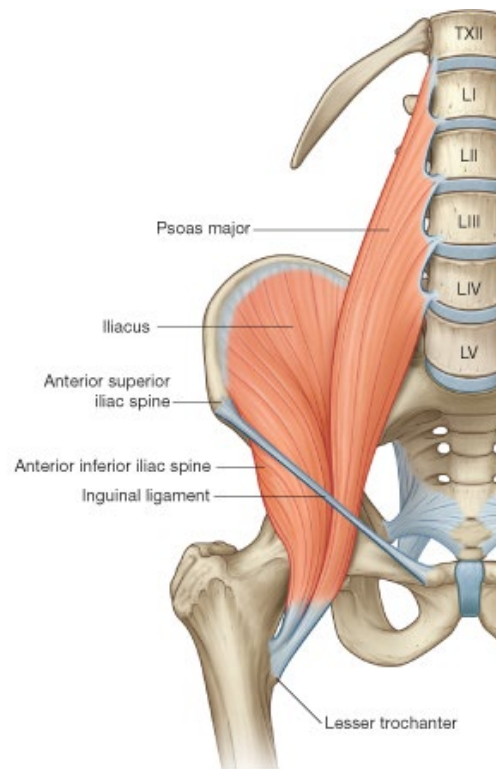
### **Nerve supply to quadriceps:**

- **Femoral nerve**



### **OTHER MUSCLES OF PROXIMAL THIGH:**

- 2 more muscles arise in the proximal part of the thigh.
- Arise in the adominopelvic cavity
- Converge as common tendon on the **lesser trochanter of the femur**.
- **Flexors of the hip joint**
- **Psoas major**
- **Iliacus**
  
- Both are supplied by the **femoral nerve**
- Pass deep to the inguinal ligament to insert into the lesser trochanter.
- Iliacus remains fleshy along course
- Psoas becomes a strong fibrous tendon
- Iliacus inserts both into the tendon of psoas, and into the lesser trochanter.
- Combined **iliopsoas** passes in front of the capsule of the hip joint.
- Iliopsoas is seperated from the hip joint capsule by a **bursa**.
  
- As well as a flexor, **psoas** is also a **medial rotator of the thigh when it is in the flexed position**.

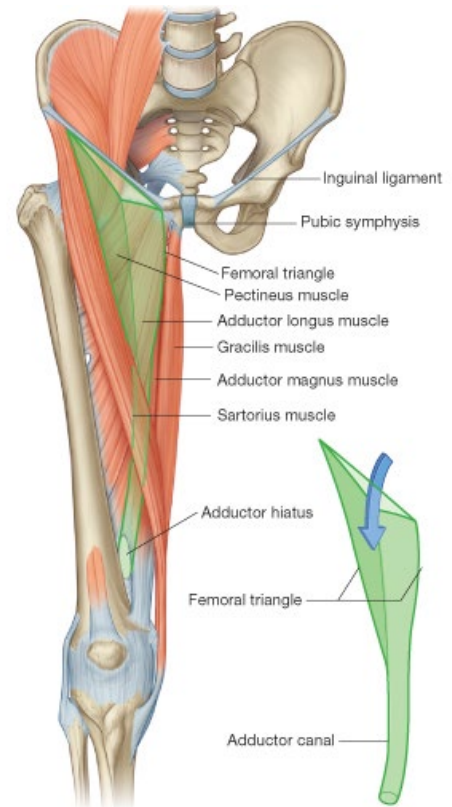


- **Sartorius**
- Last muscle of the anterior compartment
- Arises from ASIS
- Crosses obliquely in front of thigh
- Extends below the knee joint to insert into the medial side of the tibia.
- Although sartorius belongs to the anterior compartment, it is a *flexor* not an extensor.
  
- **Flexor** of both the *hip* and *knee* joint

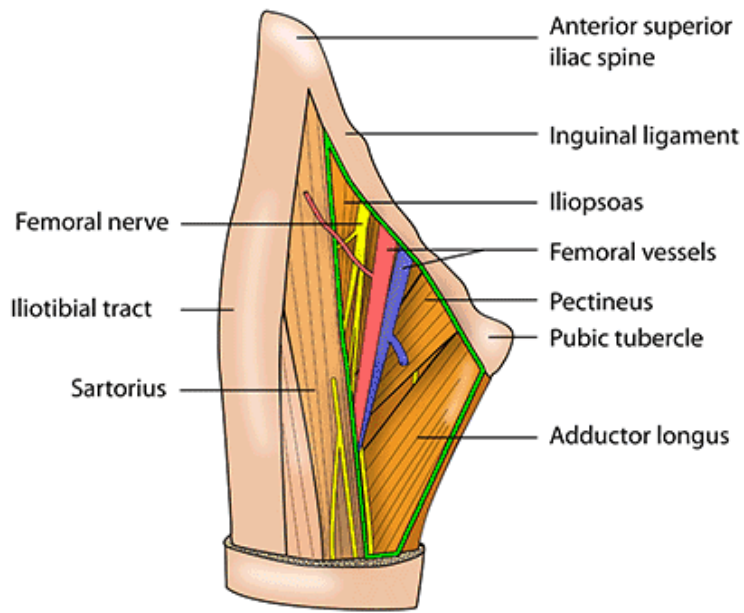
- **Lateral rotator** of the thigh
- Muscle used to sit cross-legged on the floor.
- Sartorius is supplied by the **femoral nerve**.

#### THE FEMORAL TRIANGLE AND FEMORAL CANAL:

- **Anterior** of thigh
- Base: inguinal ligament
- Lateral side: sartorius
- Medial side: medial border of:
  - Adductor longus
  - Pectineus
  - Insertion of iliopsoas
- Superficially: deep fascia, fat & skin
- Apex of femoral triangle leads to intermuscular cleft – the **adductor canal**
  - *Between:* **Vastus medialis** and **adductor magnus**.
  - *Covered superficially* by: **sartorius**
- At distal end of the adductor canal is the **adductor hiatus** in the adductor magnus.
- **subsartorial canal:** ½ way down the thigh
  - Between: **sartorius** and **adductor longus**



## FEMORAL TRIANGLE

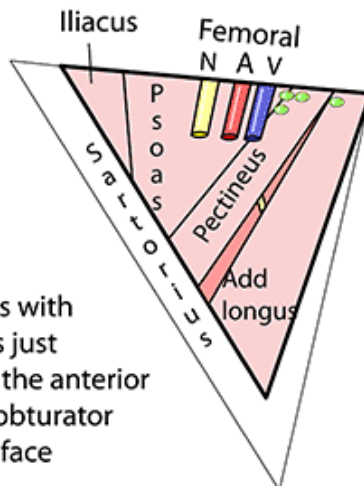


## BOUNDARIES

**Lateral**  
Medial border of sartorius

**Roof**  
Fascia lata

**Floor**  
Marked muscles with adductor brevis just showing. It has the anterior division of the obturator nerve on its surface



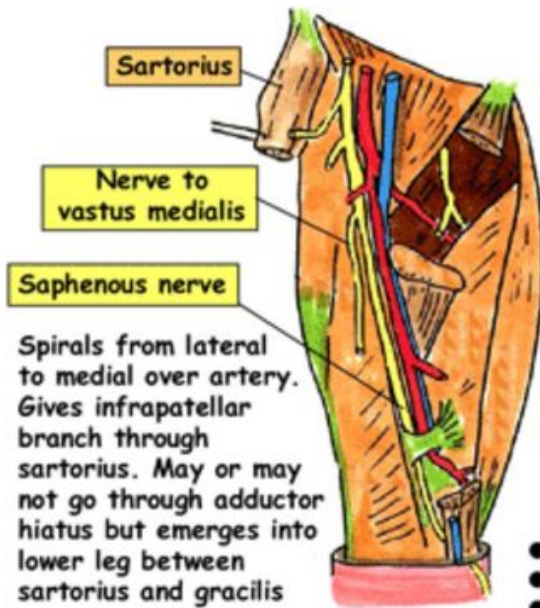
**Superior**  
Inguinal ligament

**Medial**  
Medial border of adductor longus

**Contains**  
Femoral nerve  
Femoral artery  
Femoral vein  
Deep inguinal nodes

A

## ADDUCTOR CANAL (HUNTER'S/SUBSARTORIAL)



Spirals from lateral to medial over artery. Gives infrapatellar branch through sartorius. May or may not go through adductor hiatus but emerges into lower leg between sartorius and gracilis

### Relations

Femoral artery is always between vein & saphenous nerve.  
 Femoral vein spirals from medial to artery in femoral triangle to posterior to artery in canal.  
 Femoral artery gives descending genicular artery as it leaves the adductor hiatus

### Adductor hiatus

Transmits:

- Femoral artery & vein
- Saphenous nerve (usually)
- Small genicular branch of posterior division of obturator nerve

### Boundaries

#### Lateral

- Vastus medialis

#### Medial/floor

- Adductor longus
- Adductor magnus

### Roof

- Fascia
- Sartorius
- Subsartorial plexus (contributed to by:
  - Anterior branch of obturator
  - Medial cutaneous n of thigh
  - Saphenous nerve
 Supplies: Skin of medial thigh)

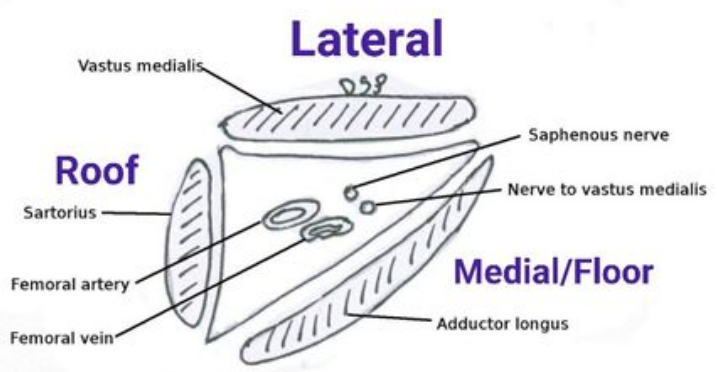
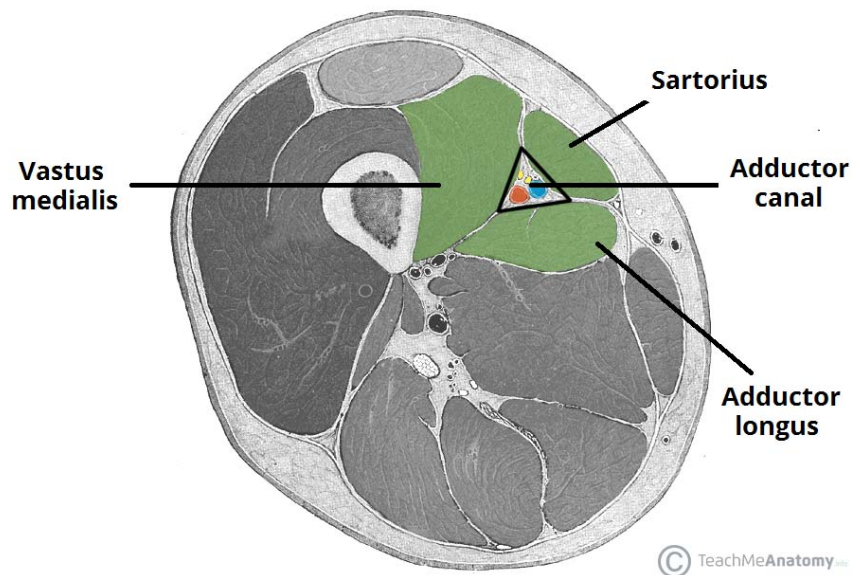
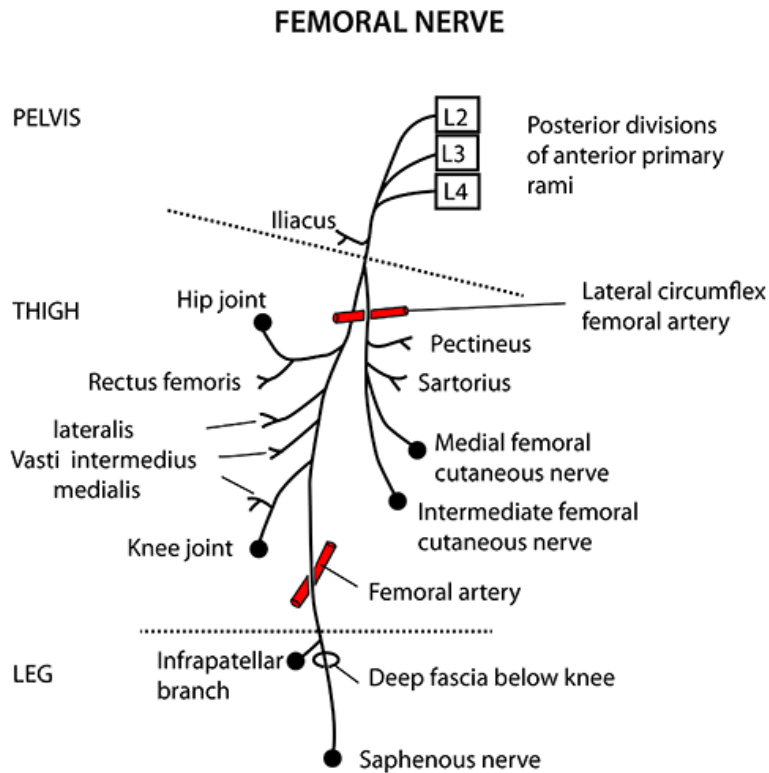


Fig. 2.14 Adductor canal



- Arterial supply to the lower limb is the **femoral artery**
- Femoral artery is a continuation of the **external iliac artery**
- Enters limb behind the inguinal ligament
- Venous blood from lower limb collects in the **femoral vein** which accompanies the femoral artery.
- Femoral vein becomes **external iliac vein** in abdominopelvic cavity.
- **Femoral nerve** supplies the muscles of **anterior extensor compartment** of lower limb.
- Femoral nerve is a branch of the **lumbar plexus (posterior divisions of L2,3,4)**
- Enters limb by passing behind the inguinal ligament.
- Femoral nerve becomes the **saphenous nerve** in the adductor canal
- **Lymphatics** accompany the femoral artery into abdominopelvic cavity → para-aortic channels.
- Must follow femoral artery, nerve & vein through each of 3 compartments:
  - Entrance to lower limb behind inguinal ligament
  - Femoral triangle
  - Passage in adductor canal



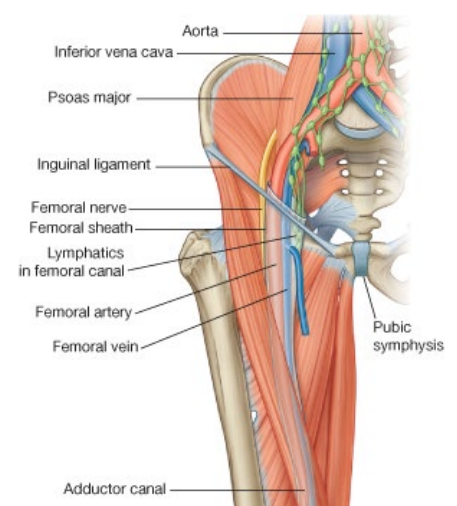


Femoral nerve: lateral to femoral artery in femoral triangle

Saphenous nerve: medial to femoral artery at base of adductor canal

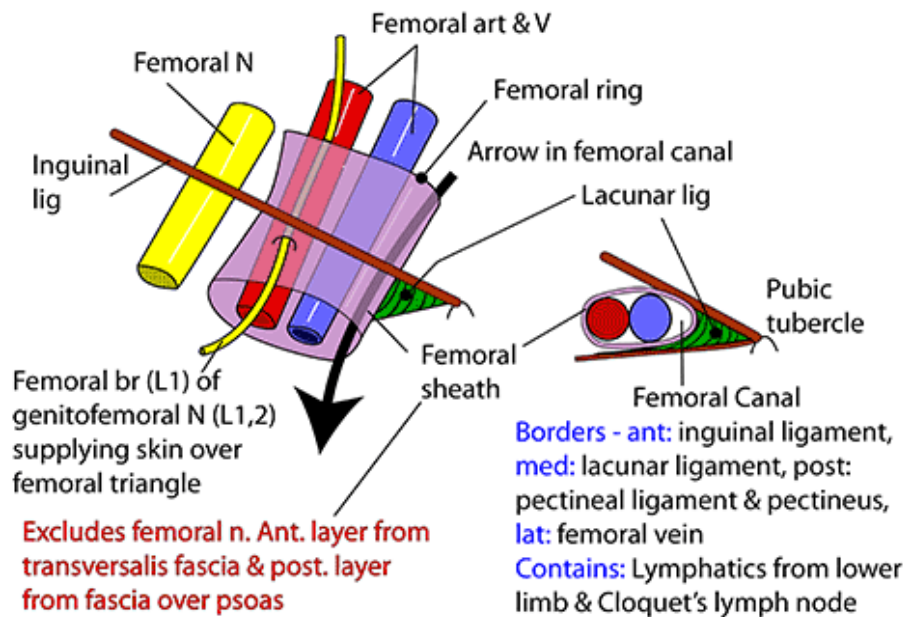
#### **ENTRANCE TO LOWER LIMB BEHIND INGUINAL LIGAMENT:**

- Remember, the **lacunar ligament** runs between the inguinal ligament and the **pectin pubis**.
- **Femoral nerve** forms in the **psoas muscle** as part of **lumbar plexus (post div L2,3,4)**
- Passes behind inguinal ligament in close association with the iliopsoas muscle.
- **Femoral artery & vein** are enclosed in fascia – **femoral sheath** – as they pass behind inguinal ligament.
- **Femoral sheath blends with the vessel walls and extends 1inch into thigh.**
- Extension of **fascia transversalis** forms anterior of femoral sheath
- Extension of **fascia iliaca** forms posterior of femoral sheath.
- IMPORTANTLY, the femoral artery and vein don't fill the femoral sheath next to the oval lacunar ligament – in this space is **fat & a lymph node**
- The **loose areolar tissue** medial of the femoral vein up to the lacunar ligament, which forms the space, is called the **femoral canal**.
- The **femoral canal** is said to be surrounded by a ring of structures – the **femoral ring**:
  - Laterally: **femoral vein**
  - Medially: **lacunar ligament**
  - Anteriorly: **inguinal ligament**
  - Posteriorly: **pectin pubis**



- Thus the femoral sheath contains:
  - Femoral artery
  - Femoral vein
  - Femoral canal (surrounded by the femoral ring)
- AVC – alcoholics vomit constantly

### RIGHT FEMORAL CANAL, SHEATH & RING



The big black arrow is passing downwards from the femoral ring, superiorly, via the femoral canal and into the femoral triangle. The femoral sheath surrounds the canal, femoral vein and femoral artery but NOT the femoral nerve. The femoral branch of the genitofemoral nerve is surrounded by sheath but the nerve pierces its anterior wall to reach the skin of the femoral triangle

#### ANTERIOR LAYER OF SHEATH

Transversalis fascia

#### POSTERIOR LAYER OF SHEATH

Psoas fascia (this fascia and the transversalis fascia fuse with the adventitia of the femoral artery 2.5cm below the inguinal ligament)

#### CONTENTS OF SHEATH

Femoral vein, femoral artery, lymphatics

#### ADDITIONAL FUNCTION OF THE THE SHEATH

Allows expansion of femoral vein during increased venous return

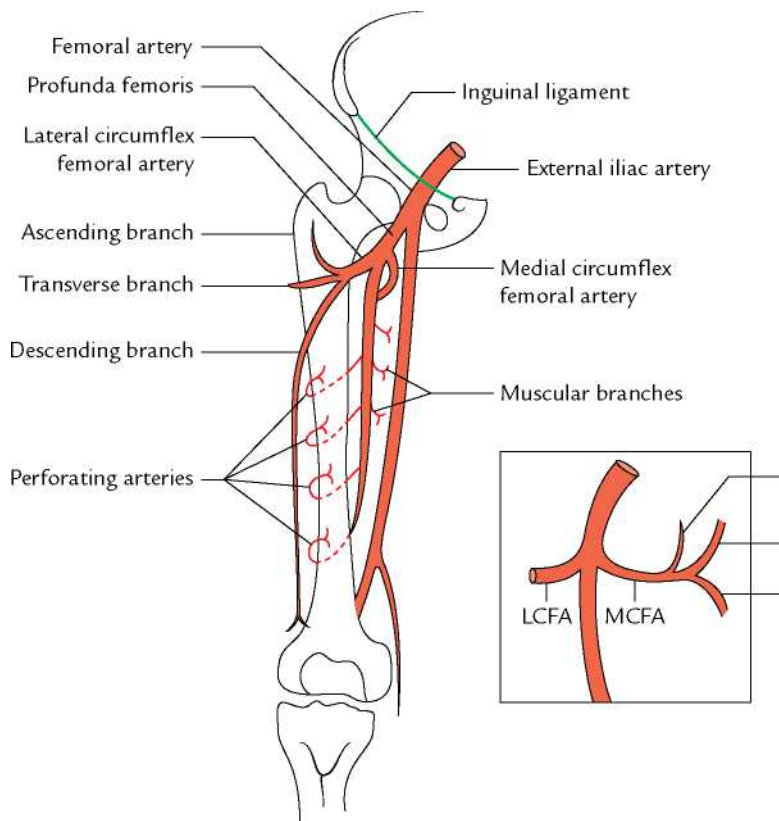
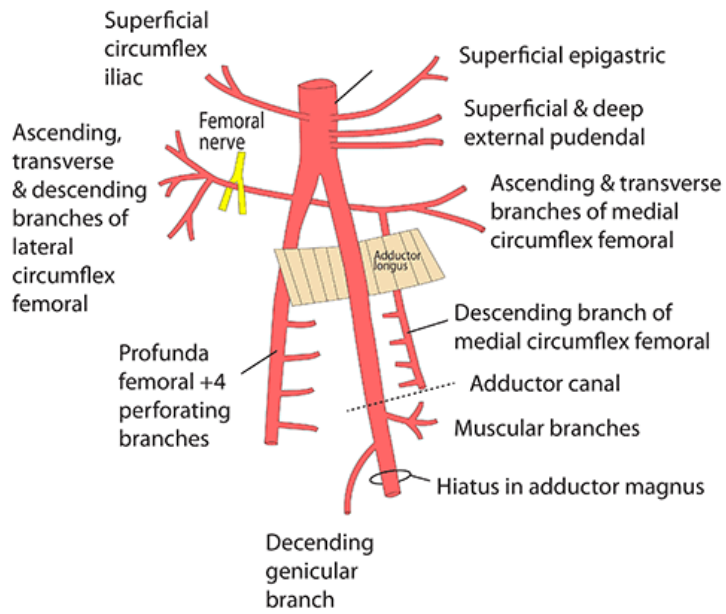
- **Femoral hernia** = herniation of abdominal contents through femoral ring and into femoral canal, into superficial tissues of the thigh.
- The **femoral artery** emerges from beneath the inguinal ligament at the **femoral point** – *midway between the pubic symphysis and the ASIS.*

- It emerges as the most lateral of the 3 structures surrounded by the femoral sheath.
- The fascia of the sheath quickly fuses with the vessel walls.
- **Femoral nerve** is on lateral side of femoral vein, but not included in femoral sheath.
- **Femoral nerve doesn't accompany the artery for long – quickly divides into several branches (the terminal of which is the saphenous nerve)**

#### FEMORAL ARTERY & VEIN:

- Femoral artery passes through femoral triangle → apex
- In triangle, gives off large branch – **profunda femoris** (aka **deep femoral artery**)
- Profunda femoris is as large as the femoral artery itself.
- **Principal blood supply to the thigh**
- Arises in proximal part of triangle, curves behind the femoral artery, and dips between the superficial adductor muscles (pectineus & adductor longus)
- The profunda femoris give off 2 large branches soon after it is formed:
  - **Lateral circumflex branch**
  - **Medial circumflex branch**
- **Lateral circumflex artery:**
  - Larger
  - Passes to deep surface of rectus femoris.
  - Sends **ascending branches** to supply hip muscles & joint, & gluteal muscles
  - Sends **transverse branches** into the vasti, which also course round back of femur.
  - Sends **descending branches** to knee region
- **Medial circumflex artery:**
  - **Sinks** into medial thigh musculature over upper border of magnus
  - Sends **ascending branches** to supply hip muscles & joint, & gluteal muscles
  - Sends **transverse branches** into the vasti, which also course round back of femur
  - Transverse branches of the lateral and medial circumflex arteries anastomose at back of femur
  - **Descending branch**
- Profunda femoris continues down the thigh, giving off **perforating branches**
- Perforating branches supply the adductor sheet of muscles and then travel round back of femur to supply posterior compartment & vastus lateralis muscle.
- There are **4 small branches of the femoral artery** itself, soon after it enters the femoral triangle:
  - **Superficial circumflex iliac**
  - **Superficial epigastric**
  - **Superficial + deep external pudendal**
- They fan out to surrounding superficial tissues
- Accompanied by veins (which are important in the treatment of varicose veins).

## RIGHT FEMORAL ARTERY



## HIP JOINT 3

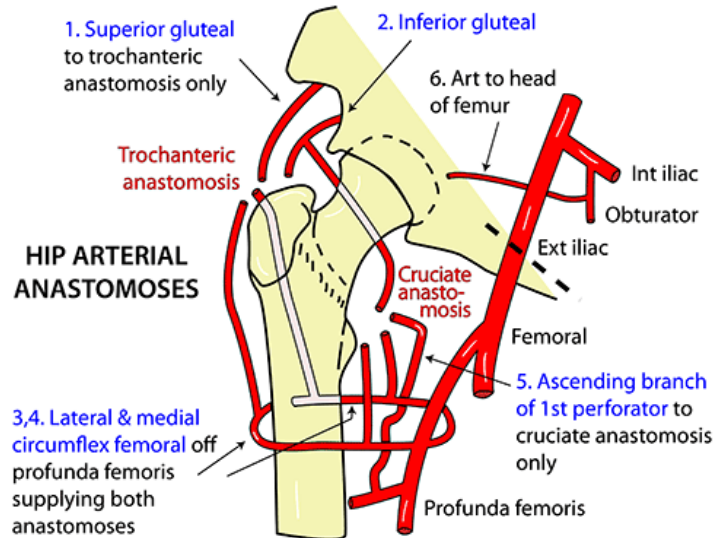
### CAPSULE

Strong ++

Anterior: Covers whole neck to intertrochanteric line

Posterior: Covers neck half way to intertrochanteric crest

Reflects: Back as retinaculum which carries the blood supply



### 2 ANASTOMOSES

#### Trochanteric (at greater trochanter):

Descending superior gluteal

Inferior gluteal

Ascending branches of medial & lateral circumflex femoral

#### Cruciate (at lesser trochanter):

Transverse branches of medial & lateral circumflex femoral

Descending branch of inferior gluteal

Ascending branch of 1st perforating artery

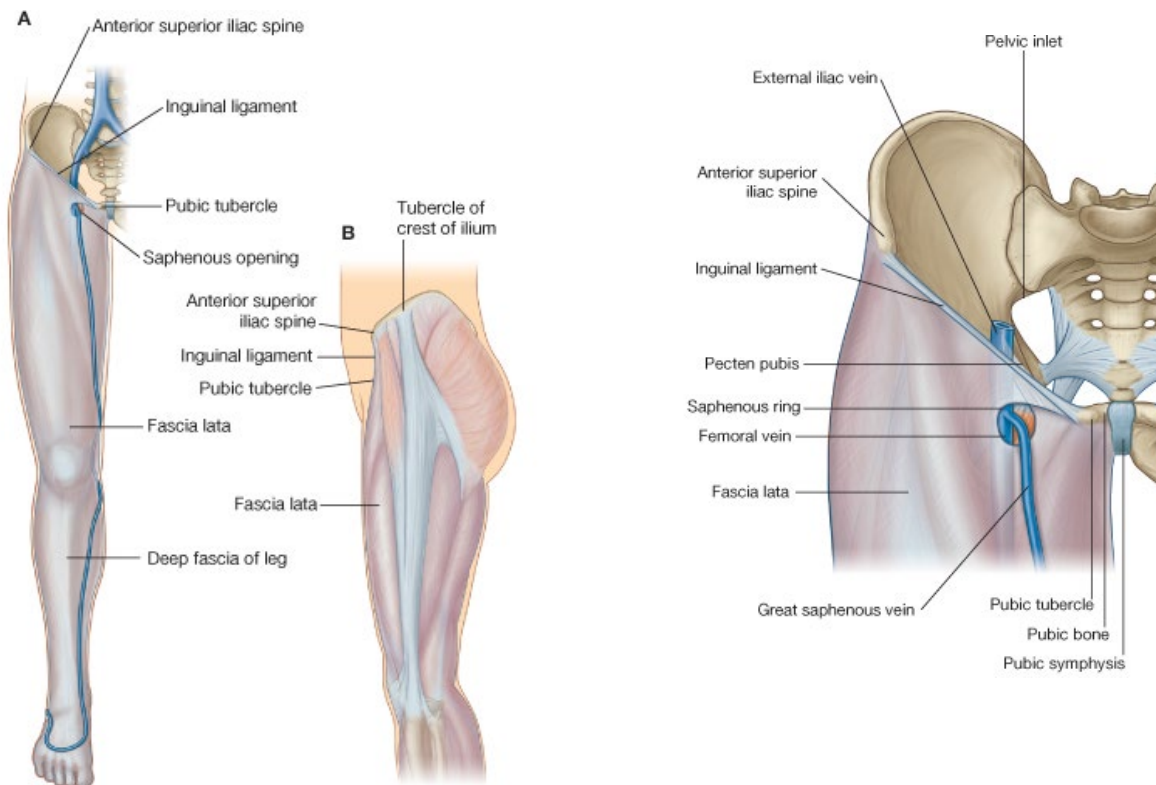
Mnemonic:

Upper anastomosis does not receive branch from lowest artery,  
lower anastomosis does not receive branch from highest artery.

### FEMORAL VEIN:

- Lies medial to the femoral artery in the femoral sheath.
- Travels up alongside the femoral artery from the apex of the femoral triangle.
- As the 2 vessels travel down the femoral triangle, they spiral such that the vein is behind the artery at the apex.
- As soon as it passes inguinal ligament: femoral vein = external iliac vein.
- **Profunda vein** travels with the profunda femoris artery
- BUT the lateral and medial circumflex veins enter the femoral vein directly.
- Femoral vein receives a large superficial vein called the **great saphenous vein**.
- Great saphenous vein is a long vein
- Originates on medial side of foot and ankle
- Drains blood from medial side of leg & thigh
- Runs in superficial fat of leg to just below level of inguinal ligament
- Then passes through the **deep fascia** of the thigh – the **fascia lata** – to reach the femoral vein which lies deep to it.
- The opening in the fascia lata is called the **saphenous opening**.
- Saphenous opening contains loose areolar tissue – the **cribriform fascia**





- Before joining the femoral vein, the saphenous vein receives 4 tributaries.
- Only important in treatment of varicose veins.
- **Great saphenous vein** contains many valves because it lies in *subcutaneous fat* and cannot rely on the skeletal muscle pump.
- If the valves become defective → pooling of blood → dilated veins → **varicose veins**.
- In the lower leg & ankle the saphenous vein communicates with deep veins via **perforators**.

### THE FEMORAL NERVE:

- Doesn't have a long course in the femoral triangle.
- Accompanies iliopsoas muscle/tendon behind the inguinal ligament, lateral to the femoral sheath.
- Divides in the proximal triangle into a 'fan' of several terminal branches:
  - **Cutaneous branches** to the skin on the front of thigh
  - **Saphenous nerve** – long cutaneous nerve which accompanies femoral artery to the apex of the femoral triangle. **Saphenous nerve may go through adductor hiatus**.
- Muscular branches of the femoral nerve supply:
  - **Iliacus + psoas**
  - **Quadriceps femoris (all parts)**
  - **Pectineus**
  - **Sartorius**
- Branch to the **vastus medialis is long – accompanies femoral artery to apex of triangle (and through the adductor canal)**

- Femoral nerve also gives branches to the hip and knee joint

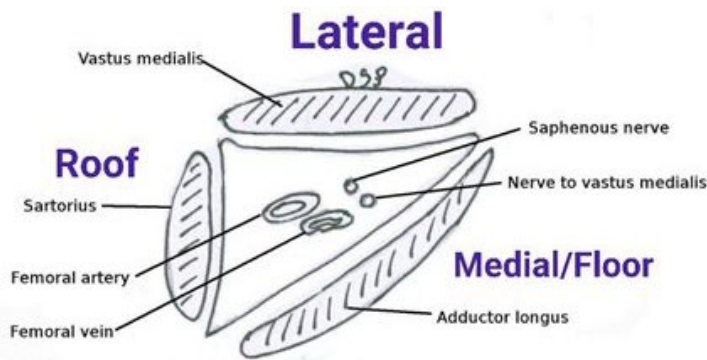


Fig. 2.14 Adductor canal

**Other nerves which reach the front of thigh from the lumbar plexus:**

- As well as the femoral nerve, other nerves reach the front of the thigh from lumbar plexus.

**Lateral cutaneous nerve of the thigh (lumbar plexus)** – passes into subcutaneous tissue of thigh

- Enters behind most lateral end of the inguinal ligament.
- Occasional irritation by pressure from the inguinal ligament → pain over outer surface of thigh.

**Genitofemoral nerve (lumbar plex L1,2)**

- After giving off the genital branch, the genitofemoral nerve continues below inguinal ligament to supply small area of skin below ligament (**femoral branch of genitofemoral nerve enters femoral sheath but then pierces the anterior sheath to supply the skin over the femoral triangle**).

**The ilioinguinal nerve (lumbar plexus L1)**

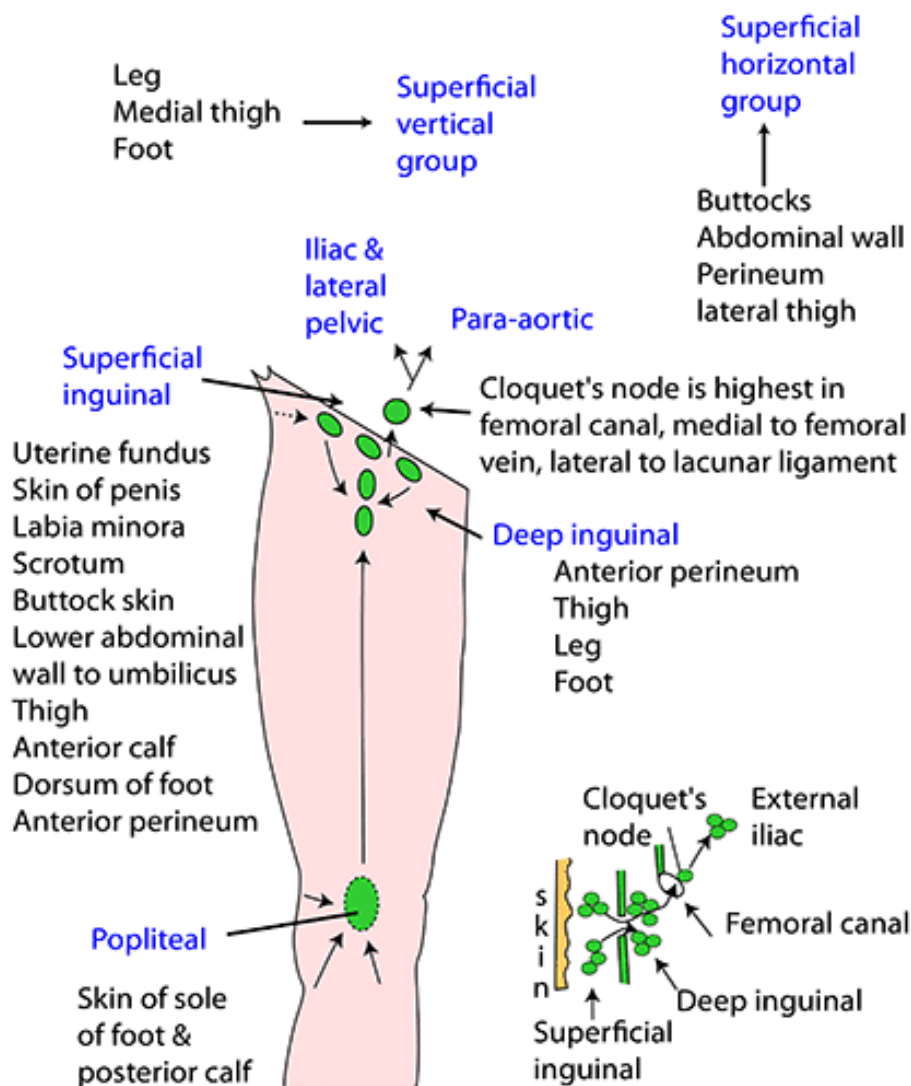
- Leaves through superficial ring
- Supplies skin of scrotum/labia majora & adjacent part of thigh
- If nerve is injured during surgery on inguinal hernia → loss of sensation in this area.

**LYMPH NODES IN FEMORAL TRIANGLE**

- LNs in femoral triangle are important in filtering lymph from lower limb.
- Arranged in **superficial and deep groups**.
- **Superficial inguinal LNs:**
  - Arranged like letter 'T'
  - Horizontal: subcutaneous fat below inguinal ligament
  - Vertical: around great saphenous vein.
  - Receive lymph from around:
    - Superficial layers of limb
    - Buttock
    - External genitalia
    - Perineum
    - Lower abdominal wall
- **Deep inguinal LNs:**
  - Efferents from superficial inguinal LNs pass onto the deep inguinal LNs

- Deep LNs surround the **femoral vein**
- One node is consistently found in the femoral canal – **CLOQUETS NODE** (medial to femoral vein in the femoral sheath).
- Efferents from the deep inguinal LNs pass behind the inguinal ligament to external iliac nodes.
- Normal to be able to palpate some inguinal LNs, even in healthy individual.

## LOWER LIMB LYMPHATICS



### REVIEW OF THE FEMORAL TRIANGLE:

- From a surgical perspective, the femoral triangle is bounded by:
  - Base: inguinal ligament
  - Laterally: sartorius
  - Medially: adductor longus
- Sartorius and adductor longus meet at the apex.

- Triangle contains:
  - Femoral vessels
  - Profunda vessels
  - Femoral nerve + its branches
  - Deep inguinal LNs surrounding the femoral vein
- Superficially, triangle is covered by:
  - Fascia lata (with saphenous opening)
  - Subcutaneous tissue, containing:
    - Cutaneous nerves
    - Great saphenous vein
    - Superficial inguinal LNs surrounding the saphenous vein.

#### **PASSAGE OF THE NEUROVASCULAR STRUCTURES THROUGH THE ADDUCTOR CANAL:**

- Adductor canal lies between vastus medialis & adductor longus.
- Distal end of the canal is the adductor hiatus (in magnus)
- Canal is roofed superficially by layer of fascia & sartorius muscle
- **Femoral artery** passes through the adductor canal → apex of triangle → hiatus  
→ posterior aspect of knee – renamed **popliteal artery**.
- **Popliteal vein** enters the adductor canal through the hiatus.  
→ anterior compartment → apex of femoral triangle – renamed the **femoral vein**
- Apex of the femoral triangle: the femoral vein is lateral to the femoral artery
- **Level of inguinal ligament: the femoral vein is medial to the femoral artery**
- **Femoral nerve** is largely finished by the time it reaches the apex of the femoral triangle.
- However, 2 of its branches accompany the femoral artery & vein part of the way through the adductor canal:
  - **Saphenous nerve** passes through the canal to emerge on the side of the knee (**between sartorius + gracilis**), to join the great saphenous vein.
  - Saphenous nerve will supply sensation to skin in lower leg.
  - **Nerve to vastus medialis** also enters the canal
  - Sends branches to the vastus medialis muscle whilst in the adductor canal.

#### **APPLIED ANATOMY OF FRONT AND MEDIAL SIDE OF THE THIGH:**

- **Quadriceps reflex (knee-jerk reflex)**
- Tapping the patellar ligament → immediate reflex extension of knee joint:
  1. Muscle spindles in quadriceps are stretched
  2. Afferent impulses from muscle spindles → femoral nerve → **L2, L3, L4** of spinal cord
  3. → motor/efferent fibres
  4. Efferent → quadriceps muscle.
- Absence of quadriceps reflex means a lesion in the reflex arc; e.g. herniated intervertebral disc into vertebral canal.
- **Fractures of shaft of femur**
- **Fractures of patella**

- Rupture of rectus femoris *muscle* in young athletes
- Rupture of rectus femoris *tendon* in older patient
- **Femoral hernia:**
- Bowel / omentum, covered with parietal peritoneum, passes through femoral ring into femoral canal.
- Abdominal protrusion within peritoneum can pass all the way along the femoral canal → ends up deep to the saphenous opening in fascia lata → protrudes through saphenous opening into subcutaneous fat of thigh.
- A femoral hernia which protrudes through the saphenous opening will have acquired a new fascial covering – the **cribriform fascia** (loose areolar tissue which fills the saphenous opening).
- The femoral hernia will present as a swelling in the groin.

*What else might cause swelling in groin?*

- Enlarged LNs
- Varicosities of great saphenous vein.
- An abscess from lumbar vertebral region, tracking down psoas sheath (which inserts in groin area).