

THE PHARYNX

- To see the pharynx must remove:
 - Ramus of the mandible
 - Associated muscles
 - Parotid salivary gland
 - Vessels & cranial nerves
- Muscular tube

Superior constrictor muscle

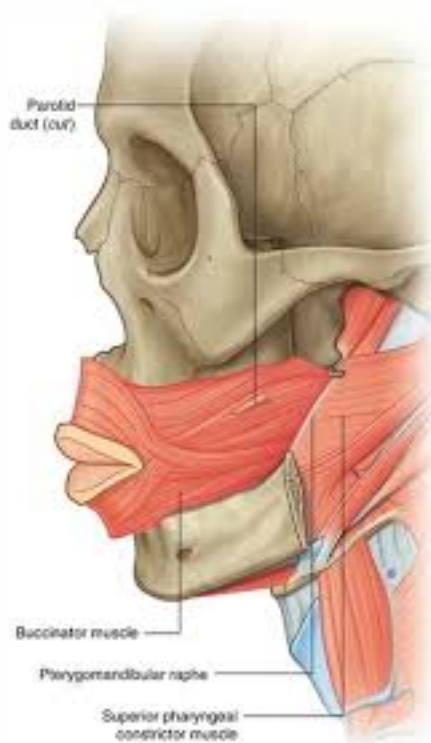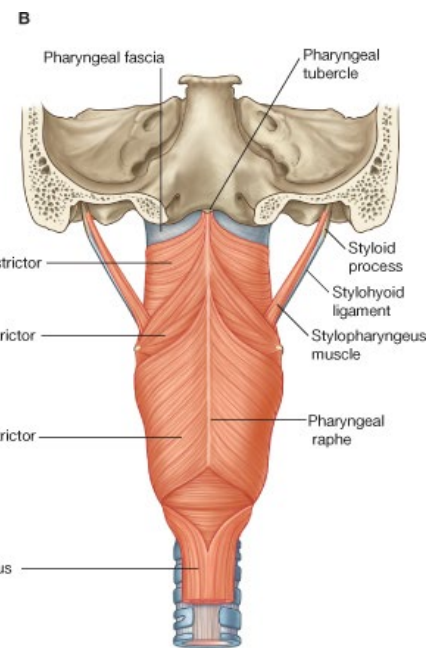
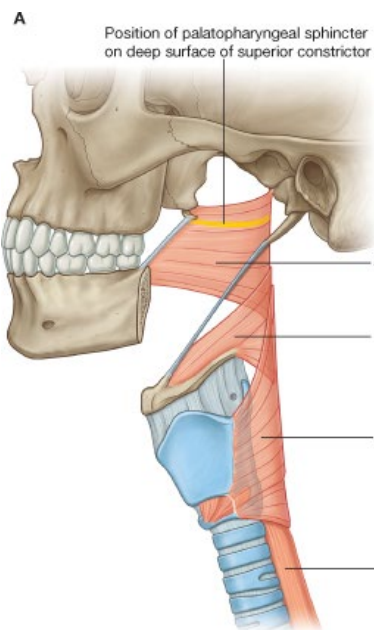
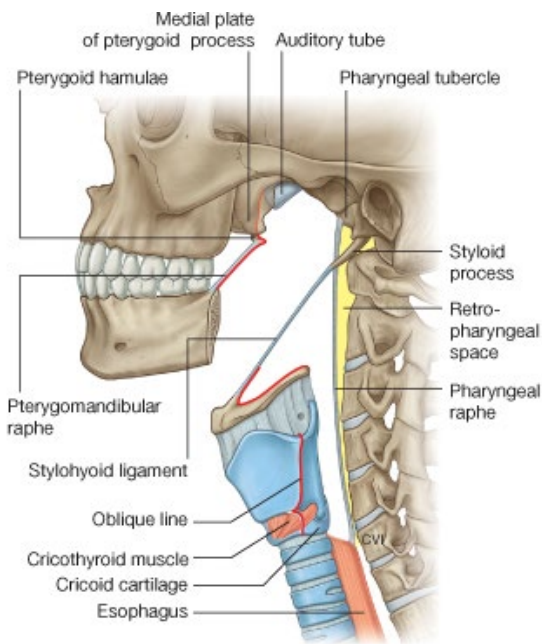
- Upper muscle fibres
- Has 2 origins:
 - A. From back of the nose on either side – from the **medial pteryoid plates** of the sphenoid bone
 - Tip of each medial pteryoid plate curves outwards to a hook – **pteryoid hamulus**
 - Fibres arising from the medial pteryoid plates sweep upwards and insert into the **pharyngeal tubercle** of the basoccipital bone.
 - B. From the **pterygomandibular raphe** (extends from pteryoid hamulus → inner surface of mandible on each side of the mouth).
- Muscle fibres from both origins fuse in the midline posteriorly at a seam or **raphe**.
- This muscle forms the **superior constrictor muscle**
- Fibres from the medial pteryoid plate bound the **nasopharynx**
- Fibres from the pterygomandibular raphe bound the **oropharynx**
 - Has the **palatine tonsil** applied to its inner wall
- The superior constrictor forms a raphe anteriorly with buccinator muscle.

Middle constrictor muscle:

- Arise from the:
 - **Greater horn of the hyoid bone**
 - **Stylohyoid ligament**
- Sweep round to the back of the pharynx *outside* the lowermost fibres of superior constrictor muscles.
- Fuse in the posterior midline raphe.

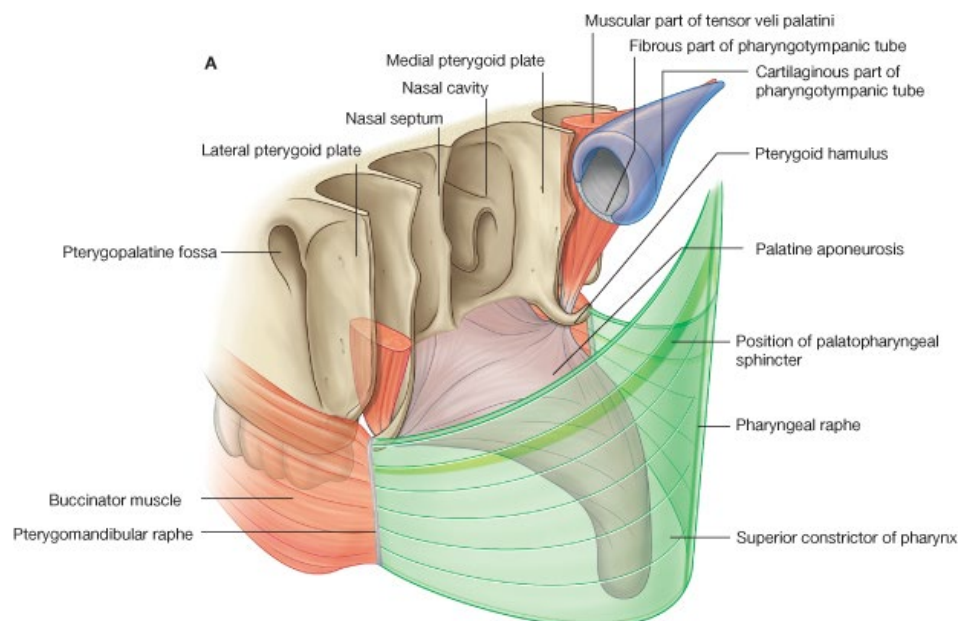
Inferior constrictor muscle:

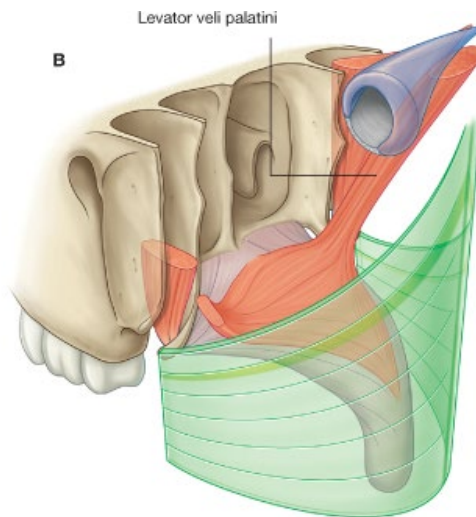
- Arise from the sides of the thyroid cartilage and the cricoid cartilage.
- Sweep round to back of the pharynx *outside* the lowermost fibres of the middle constrictor muscle
- Surrounds the **laryngopharynx** – lies at the level of the larynx.
- The midline raphe Δ extends from the base of the skull → beginning of the oesophagus.
- The 3 constrictor muscles overlap one another like stacked flower-pots.



- Oesophagus is in continuity with the inferior constrictor muscle below.
- **Prevertebral fascia** lies behind the oesophagus and pharynx
 - Allows free movement of the oesophagus and pharynx on the prevertebral muscle mass.
- The **retropharyngeal space** lies between the posterior wall of the pharynx and the prevertebral fascia.
- It is a potential space, filled with a little connective tissue.
- Infection of the retropharyngeal space can spread rapidly

- Puss in this space → **retropharyngeal abscess**
- Larynx:
 - Framework = cartilaginous
 - Spaces = filled with membranes
- Pharynx & oesophagus:
 - Framework = muscular
 - Spaces = filled with loose CT
- **Pharyngobasilar fascia** covers the inner surfaces of the muscles of the pharynx
- Thin
- Doesn't exist in lower pharynx as a membrane – as this would prevent expansion of the pharynx.
- But *does* exist as a true membrane between the upper free edge of the superior constrictor muscle and the base of the skull.
- **Buccopharyngeal membrane** covers outer surface of pharynx (+cheek).
- Insignificant membrane – doesn't help facilitate easy movement on prevertebral muscles.
- **Tensor palati & levator palati** muscles arise from base of the skull close to the superior constrictor muscle.
- **Tensor palati** runs down outside of the superior constrictor muscle and inserts into the pterygoid hamulus → changes direction and passes horizontally into palate.
- **Levator palati** runs through the pharyngobasilar fascia above the superior constrictor muscle to reach top of palate from inside the nasopharynx.
- Gaps between the superior, middle and inferior constrictor muscles are plugged with loose connective tissue but still allow important muscles and nerves to pass through to:
 - Oropharynx & mouth
 - Laryngopharynx & larynx





STYLOID APPARATUS:

- Muscles arise from the **styloid process** to insert into:
 - **Tongue** – *styloglossus*
 - **Hyoid bone** – *stylohyoid*
 - **Pharynx** – *stylopharyngeus*

Styloglossus:

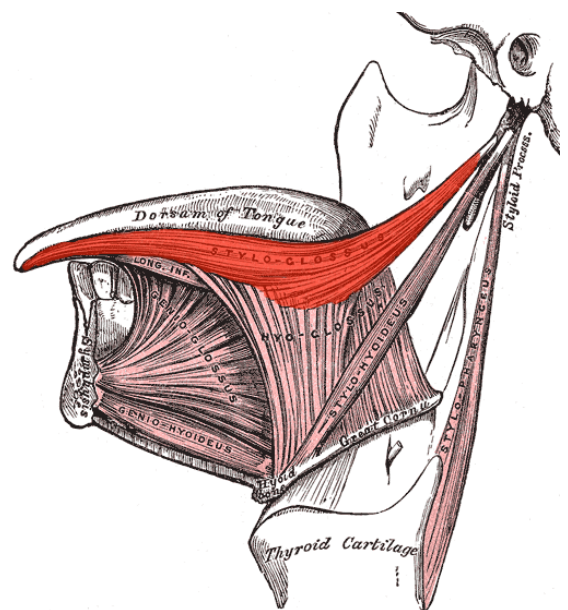
- Passes to the tongue between the superior and middle constrictor muscles
- Pulls the tongue upwards and backwards

Stylohyoid:

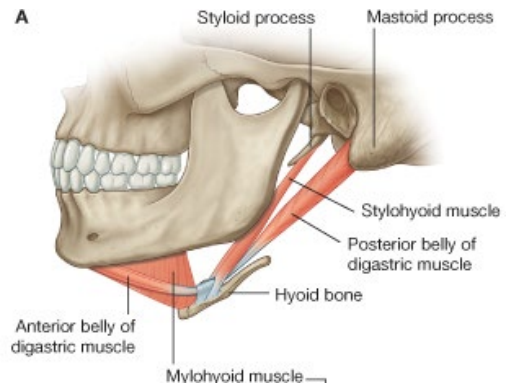
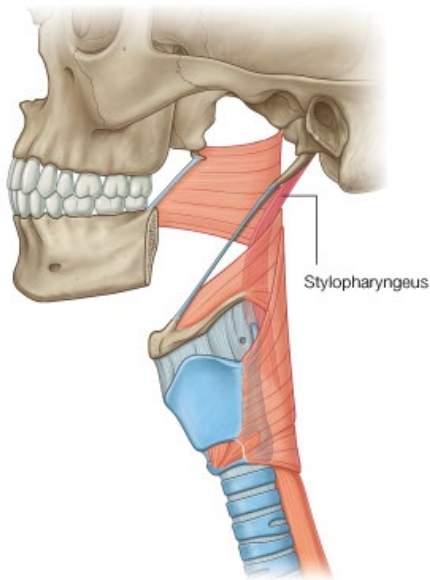
- Emerges more superficially
- Inserts into the hyoid bone at the junction between the body and greater horn.
- Retracts the hyoid bone in the neck

Stylopharyngeus:

- Longitudinal muscle of the pharynx
- Passes *deep* to the other styloid muscles
- Runs from styloid process → between internal and external carotids → passes over upper border of middle constrictor → enters pharynx → **inserts into inner surface of thyroid cartilage** inside the pharynx.
- Supplied by **glossopharyngeal (IX)**.



A

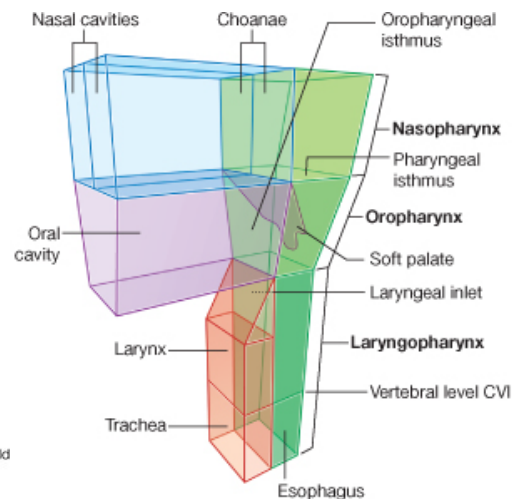


- **Stylopharyngeus** is a guide to the position of the glossopharyngeal nerve (IX)
- At its insertion the **stylohyoid** muscle forms an arch through which the intermediate tendon of the digastric muscle can pass.
- A **stylohyoid ligament** passes deep to the stylohyoid muscle and inserts into the lesser horn of the hyoid bone.
- **Styloglossus** muscle is involved in fine movement of the tongue, especially in swallowing & speech.

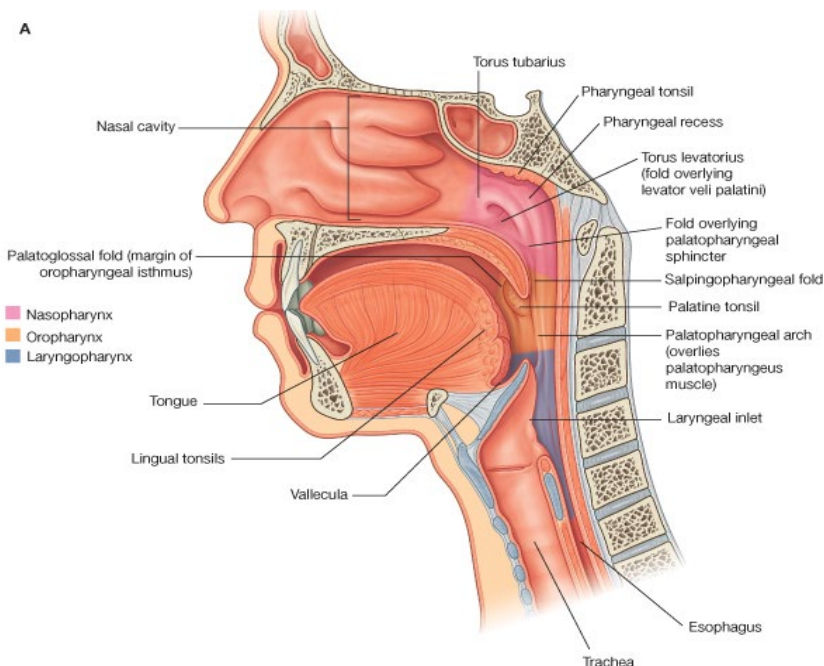
INTERIOR OF THE PHARYNX

- Lined with mucous membrane
- Nasopharynx: *respiratory epithelium* (pseudostratified ciliated colmnar epithelium)
- Rest of pharynx: *stratified squamous*

- Pharynx is divided into 3 regions:
 - **Nasopharynx** – behind the nose
 - **Oropharynx** – posterior to the mouth
 - **Laryngopharynx** – behind the larynx



A



NASOPHARYNX:

- Lies above the level of the palate
- Continuous with the oropharynx below through the **pharyngeal isthmus**
- In front it communicates with the nasal cavities
- The roof and posterior wall consist of mucous membranes covering the bones of the base of the skull.
- Lymphoid tissue is found in the posterior wall of the nasopharynx
 - Often enlarged in children – forming aggregations called **adenoids**
 - If grossly enlarged, child must breathe through open mouth – appearance called **adenoidal facies**.
- The **auditory tube** opens into the lateral wall of the nasopharynx at the level of the floor of the nose.
- Auditory tube equalises the pressure between the pharynx and the middle ear
- Can become blocked in URT infections – e.g. common cold.
- Opening of auditory tube is bounded by **tubal ridge**, containing more lymphoid tissue.
- Fold of mucous membrane descends from the tubal ridge down the side wall of the pharynx:
 - Contains a delicate longitudinal muscle of the pharynx – **salpingopharyngeus muscle**
 - Behind the ridge lies the **pharyngeal recess**

OROPHARYNX:

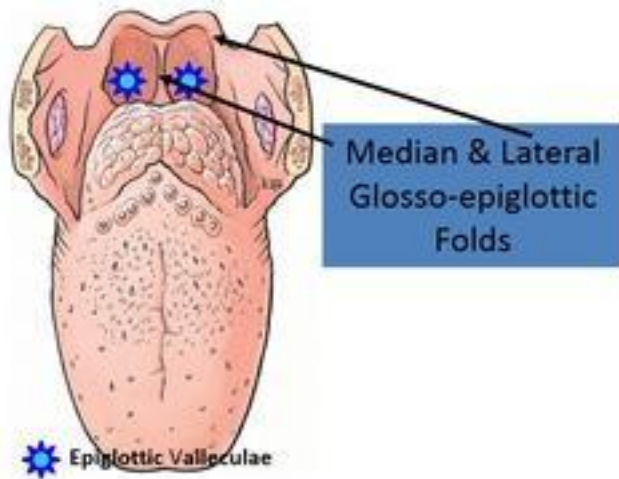
- Lies behind the **palatoglossal fold**, formed by the **palatoglossus muscle**
- Behind the palatoglossal fold, the **palatopharyngeus muscle** raises **palatopharyngeus fold**.
- Together these folds are known as the **anterior & posterior pillars of the fauces**
- The **palatine tonsil** (one on each side) lies between the 2 folds.
- Palatine tonsils are lymphoid masses and are extremely important clinically.
- Mucus membrane of the palatine tonsil dips deeply into the lymphoid tissue to form **tonsillar crypts**.
- Palatine tonsil is covered by a thin capsule which is attached to the:
 - Pharyngobasilar fascia
 - Sheath of the palatoglossal muscle.
- Helps to keep the tonsil in place.
- Outside / lateral to these structures is the superior constrictor muscle.
- **Facial artery & glossopharyngeal nerve lie outside the superior constrictor muscle here.**

Blood supply to the palatine tonsil:

- Chief artery is a branch of the **facial artery** – enters at the lower part of the tonsil.
- Veins pierce the superior constrictor muscle and drain into pharyngeal plexus or facial vein.
- Veins can bleed badly after tonsillectomy

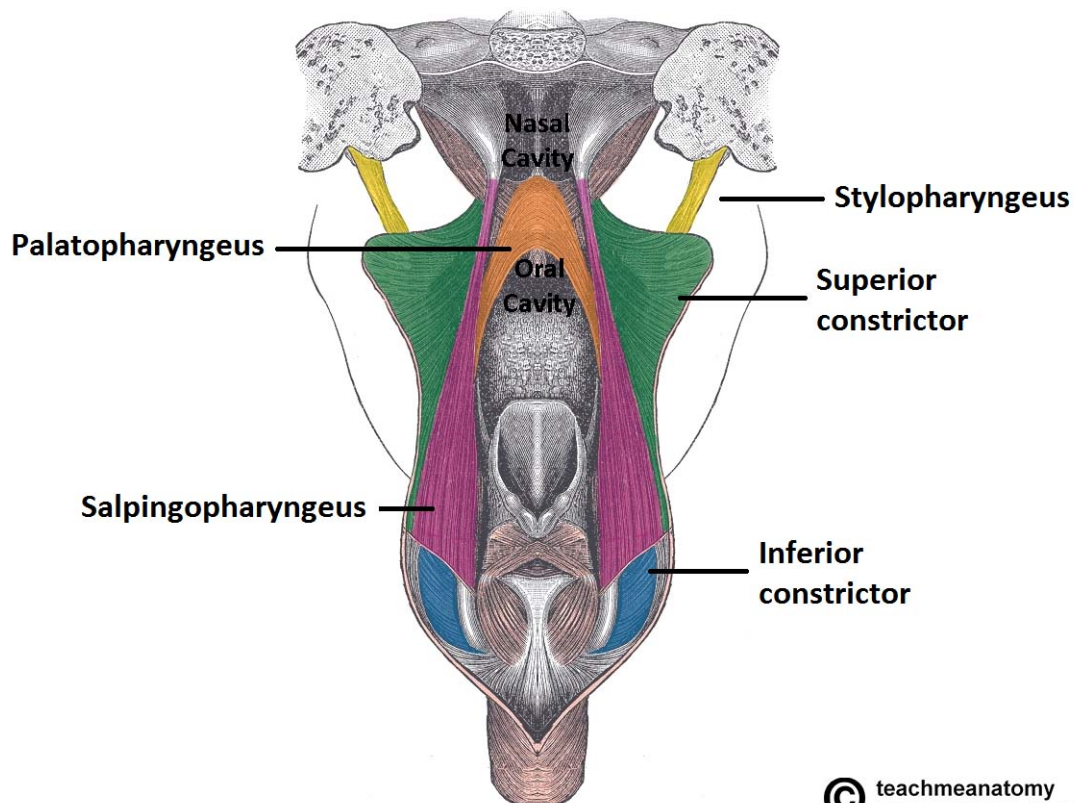
Lymphatic drainage of palatine tonsil:

- Pierce superior constrictor
- Drain to nearest LNs
- Often become enlarged and painful in tonsillitis
- **Jugulodigastric LN ('tonsillar LN')** is particularly affected
- 2 pairs of folds of mucous membrane pass forward from epiglottis → tongue:
 - **Median glossoepiglottic folds**
 - **Lateral glossoepiglottic folds**
- **Vallecula** is a depression either side of the median fold.

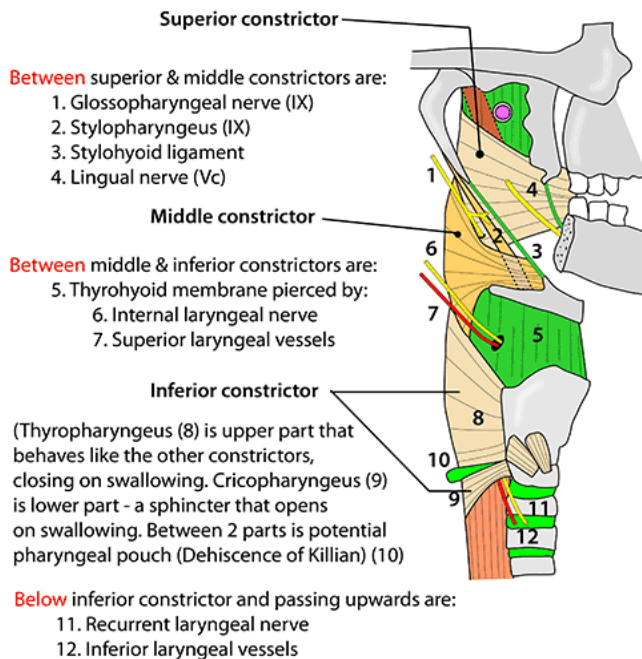


LARYNGOPHARYNX:

- Lies behind the larynx
- Posterior & lateral walls:
 - Middle and inferior constrictor muscles
 - Lower fibres of salpingopharyngeus
 - Stylopharyngeus
 - Palatopharyngeus
- Anterior wall:
 - Inlet of the larynx with the **piriform fossa** on either side.
 - Lower down: mucous membrane on the back of the cricoid cartilage.



PHARYNX - MUSCLES & STRUCTURES ENTERING IT

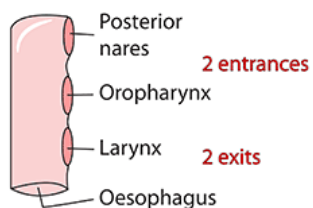


For more details & illustrations, please see relevant section in the book - Instant Anatomy, by R H Whitaker & N R Borley, 4th edition, Wiley-Blackwell 2010

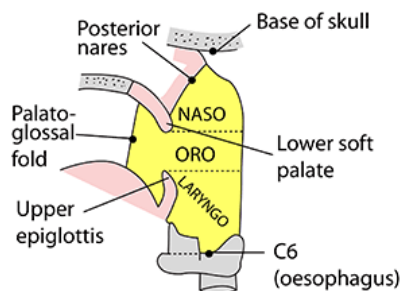
PHARYNX - DIVISIONS

- 5" (13cm) long fibromuscular tube
- Suspended from skull & lies anterior to prevertebral fascia
- Extends from nose to C6 (oesophagus)
- Like a mask applied to back of face
- Walls are mucous membrane, fibrous submucosa, muscle & thin buccopharyngeal fascia
- Muscles are:
 - 3 constrictors
 - Stylopharyngeus, palatopharyngeus, salpingopharyngeus
 - Note: levator palati is wholly intra-pharyngeal

CARTOON OF PHARYNX



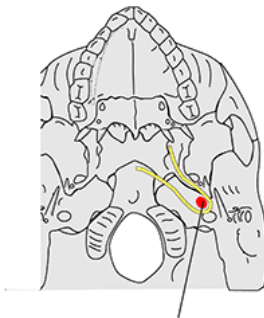
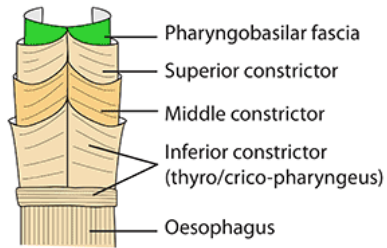
3 PARTS OF THE PHARYNX



PHARYNX - CARTOON OF MUSCLES & PHARYNGBASILAR FASCIA

CARTOON
OF MUSCLES
OF PHARYNX

LIKE 4
STACKED
CUPS



Levator palati

PHARYNGBASILAR FASCIA

(a rigid membrane with cartilage of auditory tube passing just above it. Shown in yellow)

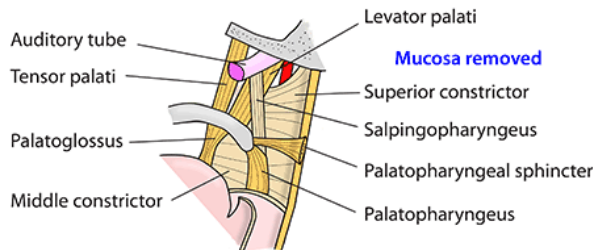
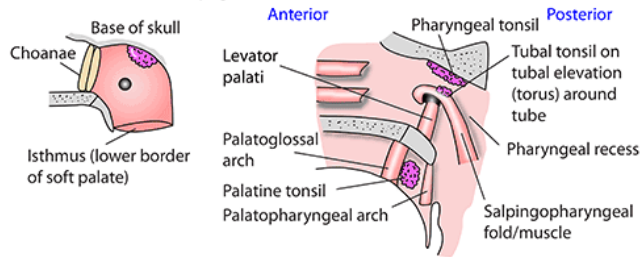
Arises: Pharyngeal tubercle, back of foramen lacerum, petrous temporal anterior to carotid foramen, cartilage of auditory tube, medial pterygoid plate, pterygoid hamulus then across to opposite side

Lower border: Junction of hard and soft palates (Passavant's ridge)

Note: Levator palati arises within pharynx

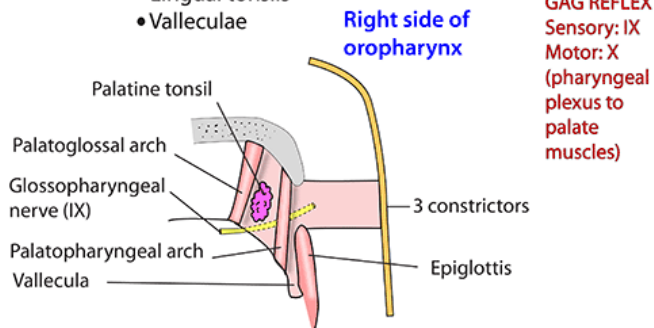
NASOPHARYNX - RIGHT

- From **CHOANAE** to **LOWER BORDER OF SOFT PALATE**
- **Back and sides:** pharyngobasilar fascia
- **Posterior:** prevertebral space/fascia, body of C1 vertebra
- **Anterior:** choanae & back of soft palate
- **Inferior:** Soft palate & pharyngeal isthmus
- **Superior:** Pharyngeal tonsil (adenoid), sphenoid & occiput
- **Epithelium:** Ciliated columnar
- **Features:**
 - Opening of auditory tube
 - Pharyngeal tonsil
 - Tubal tonsil
 - Pharyngeal recess (of Rosenmuller)
 - Salpingopharyngeus & levator palati
 - N: Pharyngeal br of Vb



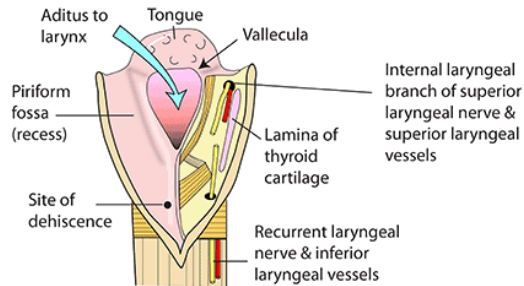
OROPHARYNX

- **From:** lower border of soft palate
- **To:** upper border of epiglottis
- **Anterior:** posterior aspect of tongue & palatoglossal arch
- **Posterior:** 3 constrictors & C2/C3 vertebrae
- **Inferior:** back of tongue, lingual tonsil & valleculae
- **Lateral:** palatoglossal/palatopharyngeal arches, constrictors & palatine (the) tonsil
- **Lining:** squamous epithelium
- **Nerves:** glossopharyngeal (IX) & internal laryngeal (X) in valleculae
- **Features:**
 - Palatine tonsils (see separate illustration)
 - Lingual tonsils
 - Valleculae



LARYNGOPHARYNX

- Extends from: tip of epiglottis - C3
- To: start of oesophagus - C6
- Anterior: larynx, aditus, epiglottis
- Posterior: 3 overlapping constrictors, dehiscence of Killian, cricopharyngeus, vertebrae C4,5,6
- Nerve supply: internal laryngeal branch of superior laryngeal nerve (X) & recurrent laryngeal nerve (X).
Note that there is some overlapping of supply in the laryngopharynx unlike in the larynx
- Lining: squamous non-keratinising epithelium
- Features: aditus to larynx & piriform fossa



Piriform fossa

Medial: quadrangular membrane
Lateral: thyrohyoid membrane & lamina of thyroid cartilage

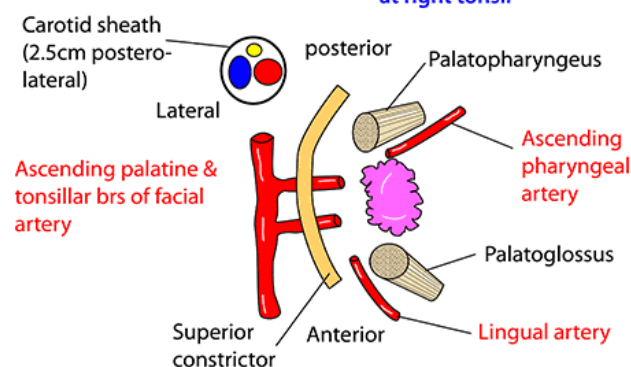
Hypopharynx

A clinical term for that part of the laryngopharynx below the aditus
Anterior: arytenoid cartilages
Posterior: dehiscence of Killian

PALATINE TONSIL

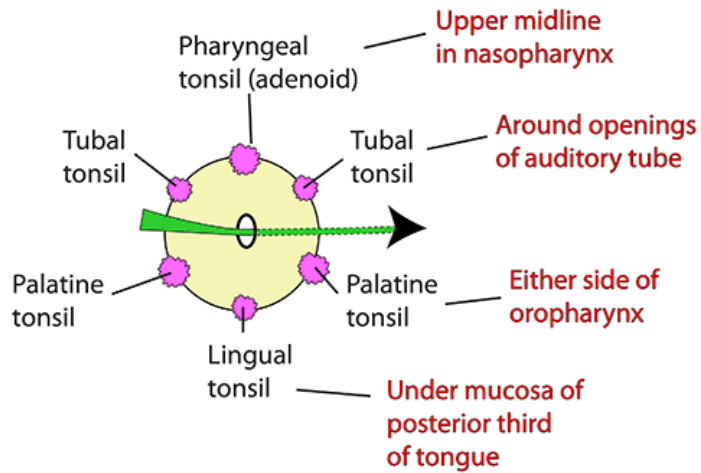
- Lymphoid tissue in tonsillar fossa
- Anterior/posterior: palatoglossal/palatopharyngeal arches
- Superior: soft palate
- Inferior: tongue
- Medial: mucosa & 20 tonsillar crypts, intratonsillar cleft (this is a large crypt from 2nd pharyngeal pouch)
- Bed: submucosa (capsule), superior constrictor, facial artery & its branches
- Lymph: to deep cervical & jugulodigastric
- Veins: plexus in capsule to pharyngeal venous plexus. Also external palatine (paratonsillar) from soft palate
- Nerves: tonsillar branch of glossopharyngeal (IX) - hence referred pain to the middle ear. Also lesser palatine (maxillary via pterygopalatine ganglion)
- Development: 2nd pharyngeal pouch endoderm gives mucosa & crypts
Surrounding mesenchyme gives lymphoid tissue
- Surface marking: medial to lower masseter

BLOOD SUPPLY



WALDEYER'S RING

An interrupted circle of protective lymphoid tissue at the upper ends of the respiratory and alimentary tracts



NERVE SUPPLY TO THE PHARYNX:


Motor:

- Muscles of the pharynx are supplied by the **cranial root of the accessory nerve (XI)**
- The cranial root then enters the **vagus nerve (X)**
- The branches of the vagus then distribute the cranial root of accessory to the muscles of the pharynx.

Sensory:

- Varies with the level of the pharynx.
- **NASOPHARYNX mucous membrane:**
 - **Maxillary branch (V_{ii})** of trigeminal nerve (like most of nose)
- **OROPHARYNX mucous membrane:**
 - **Glossopharyngeal (IX)** – (like back of tongue)
 - Also supplies mucous membrane of the auditory tube & middle ear
 - Vallecula is supplied by vagus (X)
- **LARYNGOPHARYNX mucous membrane:**
 - **Pharyngeal branch (vagus X)**
 - **Recurrent laryngeal nerve (vagus X)**
 - (Just like the larynx)
- **Pharyngeal plexus** is a plexus on the surface of the pharynx composed of fibres from:
 - **Pharyngeal branch of vagus**
 - **Glossopharyngeal nerve**
 - **Sympathetic fibres**

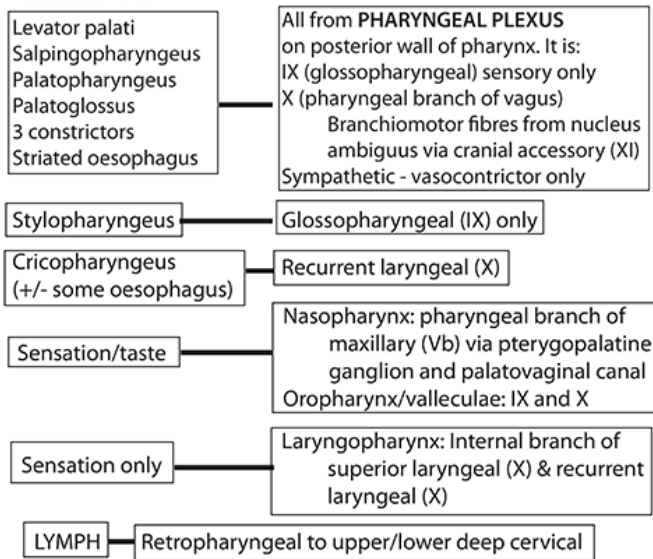
PHARYNX - VESSELS & NERVES



VENOUS DRAINAGE

Plexus on middle constrictor draining to:
Pterygoid plexus
Internal jugular vein
Lower pharynx to inferior thyroid veins

NERVE SUPPLY



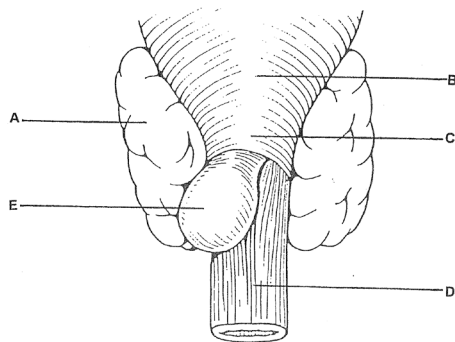
LYMPHOID TISSUE IN THE PHARYNX

- There is a ring of lymphoid tissue surrounding the entrance to the respiratory and digestive tracts:
 - Adenoids (pharyngeal tonsil) – posterior to soft palate
 - Surrounding the opening of auditory tube
 - Palatine tonsils on either side
 - Lymphoid tissue at the back of the tongue

APPLIED ANATOMY OF THE PHARYNX

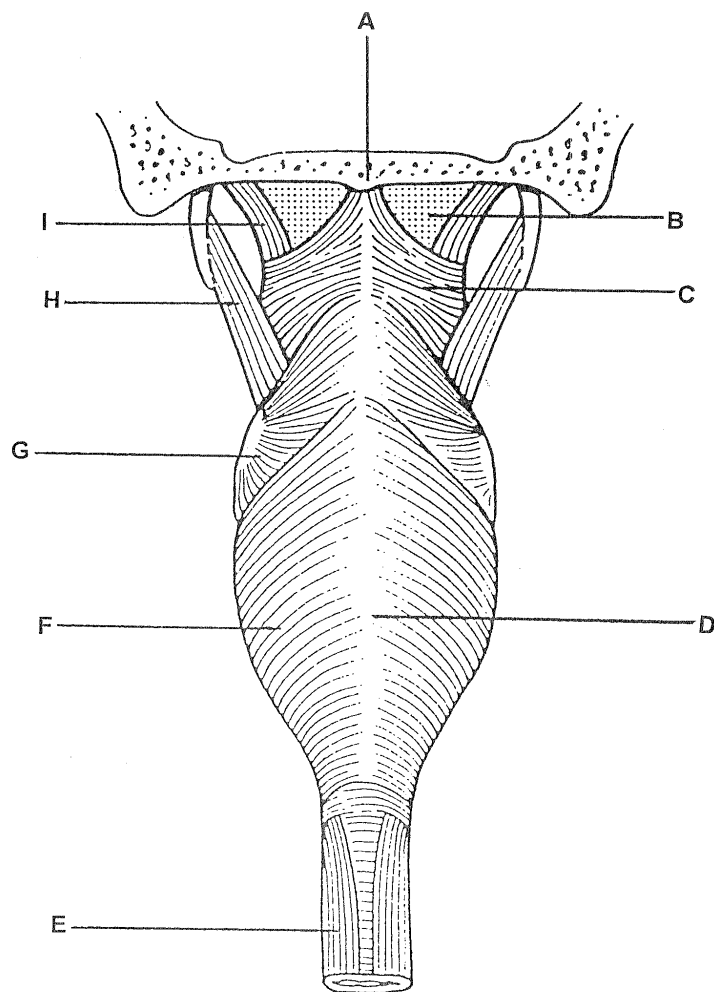
- Enlarged adenoids (pharyngeal tonsil) makes breathing through the nose difficult
- Enlarged palatine tonsils can reduce size of oropharyngeal inlet significantly
- Δ tonsilectomy is a common procedure in children
- **BUT palatine tonsil is supplied by 4 major arteries:**
 - Facial
 - Lingual
 - Ascending pharyngeal
 - Palatine
- Venous drainage is also copious – esp. from external palatine vein

- Δ common complication of tonsillectomy is bleeding from tonsillar bed
- Must also be careful, as the glossopharyngeal nerve runs behind the palatine tonsil (as it runs forward to the tongue).
- The inferior constrictor muscle and the oesophagus are continuous with one another posterior to the cricoid cartilage.
- The muscle fibres in this region form the **cricopharyngeus muscle**
- Unlike the constrictor muscles, cricopharyngeus relaxes during swallowing
- Sometimes there is weakness between the muscle of the pharynx and oesophagus in the region of cricopharyngeus muscle.
- Allow lumen of pharynx to outpouch through the muscular wall – **pharyngeal pouches / diverticuli**.
- Clinically important because:
 - Collect food
 - Gastroscope may pass into one rather than lumen of oesophagus



Pharyngeal pouches, or diverticula, may herniate through weak regions between the cricopharyngeus muscle fibres and those forming the upper part of the oesophagus.

- | | | | |
|---|------------------------|---|------------------|
| A | Thyroid gland | D | Oesophagus |
| B | Inferior constrictor | E | Pharyngeal pouch |
| C | Cricopharyngeus muscle | | |



The superior, middle and inferior constrictor muscles each run to a midline posterior raphé. The superior constrictor also runs to the bony pharyngeal tubercle. Levator palati pierces the pharyngobasilar fascia to run inside the superior constrictor and into the soft palate. Stylopharyngeus runs between the superior and middle constrictors into the wall of the pharynx.

- | | | | |
|---|------------------------|---|----------------------|
| A | Pharyngeal tubercle | F | Inferior constrictor |
| B | Pharyngobasilar fascia | G | Middle constrictor |
| C | Superior constrictor | H | Stylopharyngeus |
| D | Midline raphé | I | Levator palati |
| E | Oesophagus | | |

ADDITIONAL NOTES FROM THE LECTURE:

- **Mylohyoid** – a muscular diaphragm which extends from hyoid bone to the base of the mouth (has a midline raphe)

