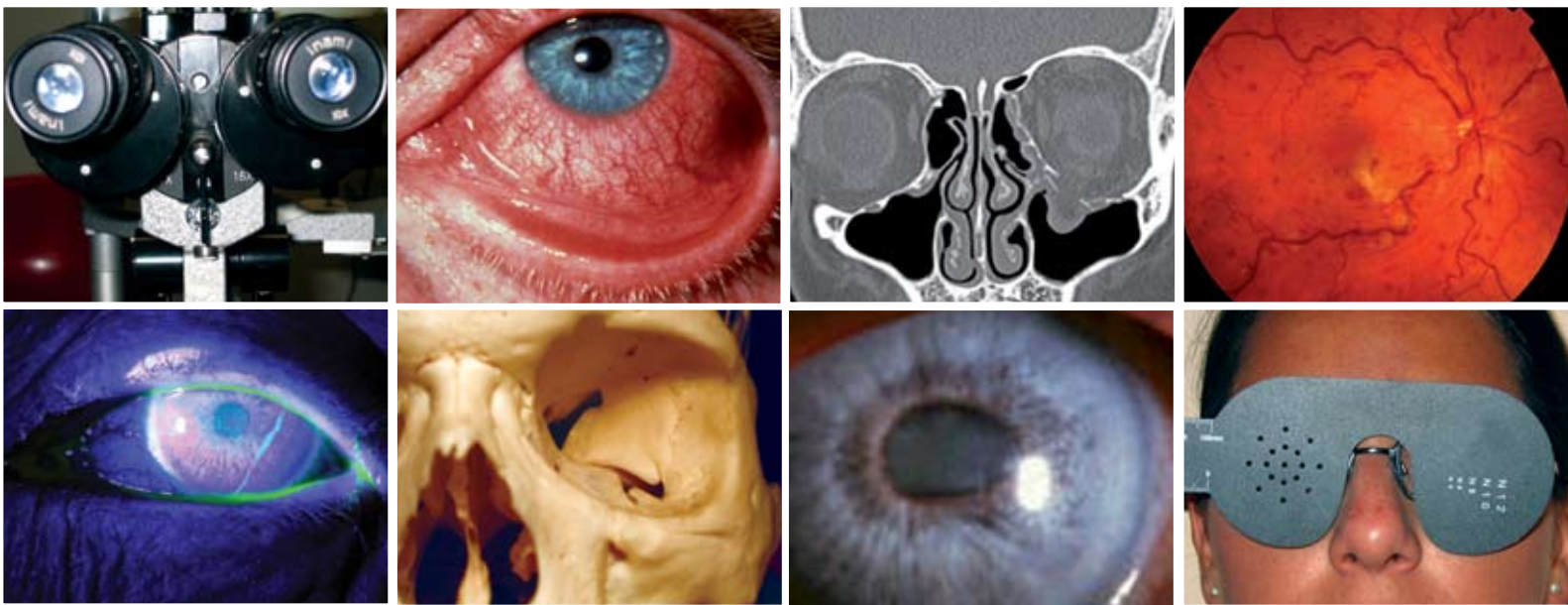


# EYE EMERGENCY MANUAL

*An Illustrated Guide*







# **EYE EMERGENCY MANUAL**

## **An Illustrated Guide**

## Acknowledgements

The Statewide Ophthalmology Service (SOS) Provision of Hospital Services Subcommittee in conjunction with the SOS Nurse Standing Committee proposed this manual and asked Dr Weng Sehu to develop it based on his existing education material.

Dr Sehu as principal author and editor would like to thank Dr Brighu Swamy, Ms Ellen Moore, Ms Jill Grasso, and Ms Louise Buchanan, from Sydney Hospital/Sydney Eye Hospital, Dr James Smith, from Royal North Shore Hospital, Ms Kathryn Thompson from the School of Applied Vision Sciences, University of Sydney, and Ms Annie Hutton from the SOS for all the time and effort they put into developing this useful tool for non-ophthalmic clinicians.

A special thankyou to Drs Con Petsoglou, Peter Martin and Alex Hunyor for providing some of the images in this manual, and to Mr Glenn Sisson, from NSW Institute of Trauma and Injury Management (ITIM) for assistance with desktop publishing.

Thankyou also to the many ophthalmologists, nurses, orthoptists and health managers, who are members of other SOS committees, who also contributed. The manual was trialled at Balmain, Mona Vale, Mt Druitt, Nepean, Pt Macquarie and the Hills Private Hospitals. Our thanks to the clinicians who assisted and provided feedback to the project team.

### Sponsors & Endorsements

This manual is sponsored by the SOS and the Greater Metropolitan Clinical Taskforce (GMCT), a Health Priority Taskforce of the NSW Department of Health. It is endorsed by the NSW Faculty of the Australasian College of Emergency Medicine (ACEM); the Australian College of Emergency Nursing (ACEN); the Royal Australian and New Zealand College of Ophthalmologists (RANZCO) and the 'Save Sight Institute,' University of Sydney.

### Disclaimer

This manual is designed for use by all medical and nursing staff in Emergency Departments across New South Wales. It is intended to provide a general guide to recognizing and managing the specified injuries, subject to the exercise of the treating clinician's judgment in each case. The GMCT (NSW Statewide Ophthalmology Service) NSW Health and the State of New South Wales do not accept any liability arising from the use of the manual. For advice about an eye emergency, please contact the Ophthalmologist affiliated with your hospital in the first instance. If unavailable contact Sydney Hospital/Sydney Eye Hospital on (02) 9382 7111.

### Copyright

© NSW Department of Health  
73 Miller St NORTH SYDNEY NSW 2061  
Phone (02) 9391 9000 Fax (02) 9391 9101 TTY (02) 9391 9900  
[www.health.nsw.gov.au](http://www.health.nsw.gov.au)

This work is copyright. It may be reproduced in whole or in part for study training purposes subject to the inclusion of an acknowledgement of the source. It may not be reproduced for commercial usage or sale. Reproduction for purposes other than those indicated above, requires written permission from the NSW Department of Health.

SHPN: (GMCT) 060125  
ISBN: 0 7347 3988 5

For further copies please contact:

Better Health Centre  
Phone: +61 2 9816 0452  
Fax: +61 2 9816 0492

February 2007

## NSW Statewide Ophthalmology Service (SOS) Committee Membership

### SOS Governing Body

Peter McCluskey	Professor of Ophthalmology (Chair)	Liverpool Hospital, SSWAHS
Michael Braham	Consumer Participant (Dep Chair)	
Allan Rosenberg	Ophthalmologist	Sutherland Hospital, SESIAHS
Ralph Higgins	Ophthalmologist	Sydney Hospital & Sydney Eye Hospital, SESIAHS
Joanna McCulloch	Nurse Practitioner	Sydney Hospital & Sydney Eye Hospital, SESIAHS
Michael Hennessy	Ophthalmologist	Prince of Wales Hospital, SESIAHS
Jill Grasso	CNC	Sydney Hospital & Sydney Eye Hospital, SESIAHS
Susan Cochrane	A/Head Orthoptist	The Children's Hospital at Westmead
Clayton Barnes	Ophthalmologist	Wagga Wagga Base Hospital, GSAHS
Lisa Cottee	Ophthalmologist	Lismore Base, NCAHS
Rafat Ghabrial	Ophthalmologist	Concord Hospital, SSWAHS
Alina Zeldovich	Ophthalmology Registrar	
Geoff Wilcsek	Ophthalmologist	Prince of Wales Hospital, SESIAHS
Philip Hayes	Ophthalmologist	Gosford Hospital, NSCCAHS
Alex Hunyor	Ophthalmologist	Sydney Hospital & Sydney Eye Hospital, SESIAHS
Mara Giribaldi	Orthoptist	Marsden Eye Specialists
Ann Macfarlane	Orthoptist	President, OAA NSW Branch
Chris Challinor	Ophthalmologist	John Hunter Hospital, HNEAHS
Julia Kelly	Head Orthoptist	Sydney Hospital & Sydney Eye Hospital, SESIAHS
Jenny Keller	Ophthalmic Nurse	Epping Eye Surgery Centre
Joanna Barton	Outback Eye Service Manager	Prince of Wales Hospital, SESIAHS
Michael Lawless	Ophthalmologist	Royal North Shore Hospital, NSCCAHS
Iain Dunlop	Ophthalmologist	Sydney Hospital & Sydney Eye Hospital, SESIAHS
Peter Sumich	Ophthalmologist	Westmead Hospital, SWAHS
Cheryl Moore	Nurse Educator	Sydney Hospital & Sydney Eye Hospital, SESIAHS
Peter Macken	Ophthalmologist	Liverpool Hospital, SSWAHS
Steevie Chan	Clinical Services Director	SSDB NSW Health
Jan Steen	Executive Director	NSW SOS

### Provision of Hospital Services Subcommittee & Nurse Standing Committee

Ralph Higgins (Co-Chair)	Ophthalmologist	Sydney Hospital & Sydney Eye Hospital, SESIAHS
Joanna McCulloch (Co-Chair)	Nurse Practitioner	Sydney Hospital & Sydney Eye Hospital, SESIAHS
Phillip Myers (Deputy Chair)	Ophthalmologist	Bankstown Lidcombe Hospital, SSWAHS
Wendy Cutler	NUM	Royal Prince Alfred Hospital, SSWAHS
Alwyn Thomas	Consumer representative	
James Smith	Ophthalmologist	Royal North Shore/ Manly, NSCCAHS
Ellen Moore	A/Director of Nursing	Sydney Hospital & Sydney Eye Hospital, SESIAHS
Jan Jones	NUM – Eye Clinic	Westmead Hospital, SWAHS
Sandra Tait	Orthoptist in Charge	Concord Repat Hospital, SSWAHS
Diana Cordell	CNC Case Manager	Royal North Shore Hospital, NSCCAHS
Phillip Hayes	Ophthalmologist	Gosford Hospital, NSCCAHS
Julie West	Clinical Nurse Consultant	St Vincent's Hospital Lismore
John Downie	Ophthalmologist	Prince of Wales Hospital SESIAHS
Mara Giribaldi	Orthoptist	Marsden Eye Specialists
Jenny Keller	Ophthalmic Nurse	Epping Eye Surgery Centre
Elyssa Brennan	Ophthalmic Nurse	Prince of Wales Hospital, SESIAHS
Alex Hunyor	Ophthalmologist	Sydney Hospital & Sydney Eye Hospital, SESIAHS
Leeanne Gardner	Nurse Specialist, Eye Clinic	Liverpool Hospital, SWSAHS
Jill Grasso	Clinical Nurse Consultant	Sydney Hospital & Sydney Eye Hospital, SESIAHS
Susan Cochrane	A/Head Orthoptist	The Children's Hospital at Westmead
Cheryl Moore	Nurse Educator	Sydney Hospital & Sydney Eye Hospital, SESIAHS
Tracey Kerle	NUM Operating Theatres	Gosford Hospital, NSCCAHS
Jan Steen	Executive Director	NSW SOS
Annie Hutton	Project Officer	NSW SOS



# Table of Contents

Introduction .....	7
Chapter One: Anatomy .....	9
Chapter Two: Ophthalmic Workup .....	13
History .....	15
Important points .....	15
Examination .....	15
Visual acuity .....	16
Slit-lamp .....	17
Fundus examination: direct ophthalmoscopy .....	20
Paediatric examination .....	21
Pupil examination .....	23
Treatment .....	24
Everting eyelids .....	24
Eyedrops .....	25
Types of Ocular Drugs .....	26
Common Glaucoma Medications .....	27
Instruments to remove corneal foreign bodies .....	28
How to pad an eye .....	29
Chapter Three: Common Emergencies .....	31
Trauma .....	32
Lid laceration .....	32
Corneal foreign body .....	33
Ocular trauma .....	34
Blunt .....	34
Sharp (penetrating) .....	35
Chemical Burns .....	36
Flash Burns .....	37
Other .....	37
Orbital .....	38
Acute red eye .....	40
Painless .....	41
Diffuse .....	41
Localised .....	42
Painful .....	43
Cornea abnormal .....	43
Eyelid abnormal .....	44
Diffuse conjunctival injection .....	45
Acute angle closure glaucoma .....	47
Ciliary injection/scleral involvement .....	47
Anterior chamber involvement .....	47
Acute visual disturbance/Sudden loss of vision .....	48
Transient Ischaemic Attack (Amaurosis Fugax) .....	49
Central Retinal Vein Occlusion (CRVO) .....	50
Central Retinal Artery Occlusion .....	51
Optic neuritis .....	52
Arteritic Ischaemic Optic Neuropathy (AION)/Giant Cell Arteritis .....	53
Retinal Detachment .....	54
Chapter Four: Emergency Contacts, Further Information & Glossary .....	55
Emergency Contacts & Further Information .....	56
Glossary .....	57
Appendix I: Australasian Triage Scale: Descriptors for Categories .....	58
Appendix II: Fact Sheet for Epidemic Keratoconjunctivitis (EKC) .....	60
Appendix III: RANZCO Infection Control Guidelines .....	62






# Introduction

This manual is designed for use by all medical and nursing staff in Emergency Departments across New South Wales. It allows a quick and simple guide to recognising important signs and symptoms, and management of common eye emergencies. The manual will also be of assistance in triaging patients to appropriate care within the health system.

These guidelines have not undergone a formal process of evidence based clinical practice guideline development, however they are the result of consensus opinion determined by the expert working group (Provision of Hospital Services Subcommittee & Nurse Standing Committee). They are not a definitive statement on the correct procedures, rather they constitute a general guide to be followed subject to the clinician's judgment in each case. The consensus opinion provided is based on the best information available at the time of writing.

To help with ease of use, this manual has a high graphic content, and is subdivided into basic ophthalmic diagnostic techniques/treatment, and management of common eye presentations. Each of the presenting conditions is subdivided into the following sections:

- Immediate action (if any)
- History
- Examination
- Treatment
- Follow-up - When to refer?

 Each section has red flagpoints that are used to increase the triage weighting or indicate urgent ophthalmic referral with an explanation of its relevance. Recommended Australasian Triage Scale (ATS) categories have been included where possible.

Information included in this manual is also available at <http://www.ciap.health.nsw.gov.au/> and GMCT website at <http://www.health.nsw.gov.au/gmct/resources/publications.html>

Listed in the appendices are emergency contact numbers and relevant information which will give all medical and nursing staff 24hr support.

---

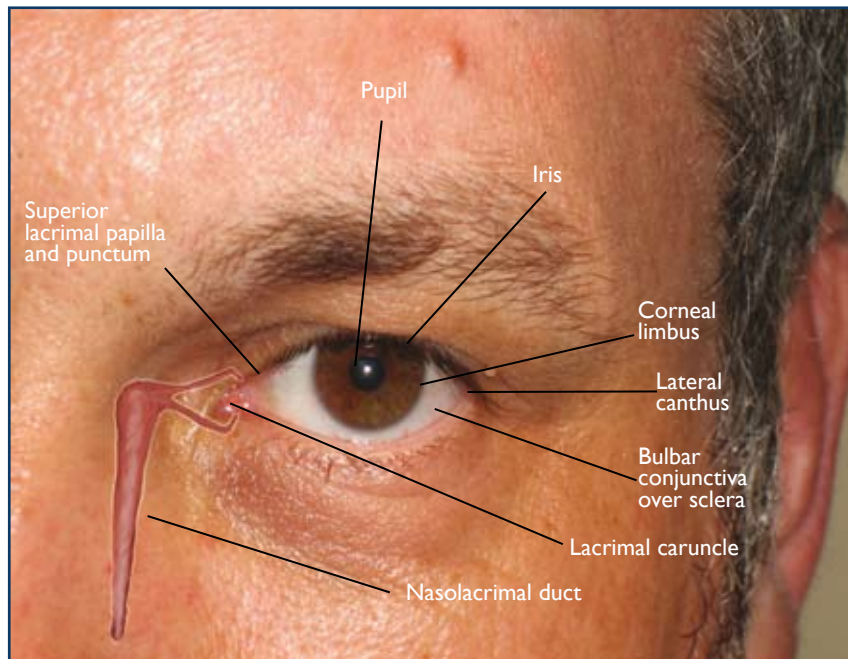


# Chapter One

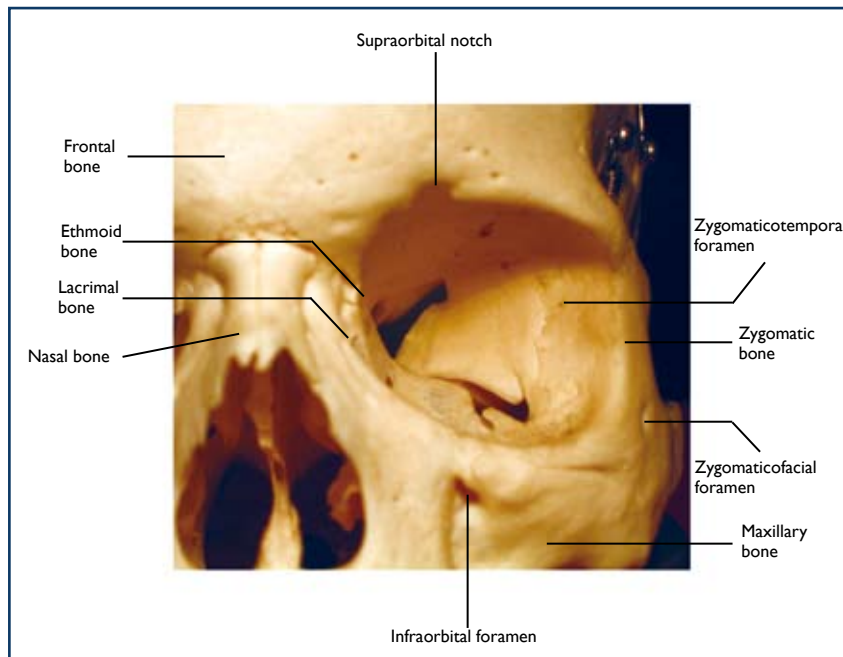
# Anatomy

---

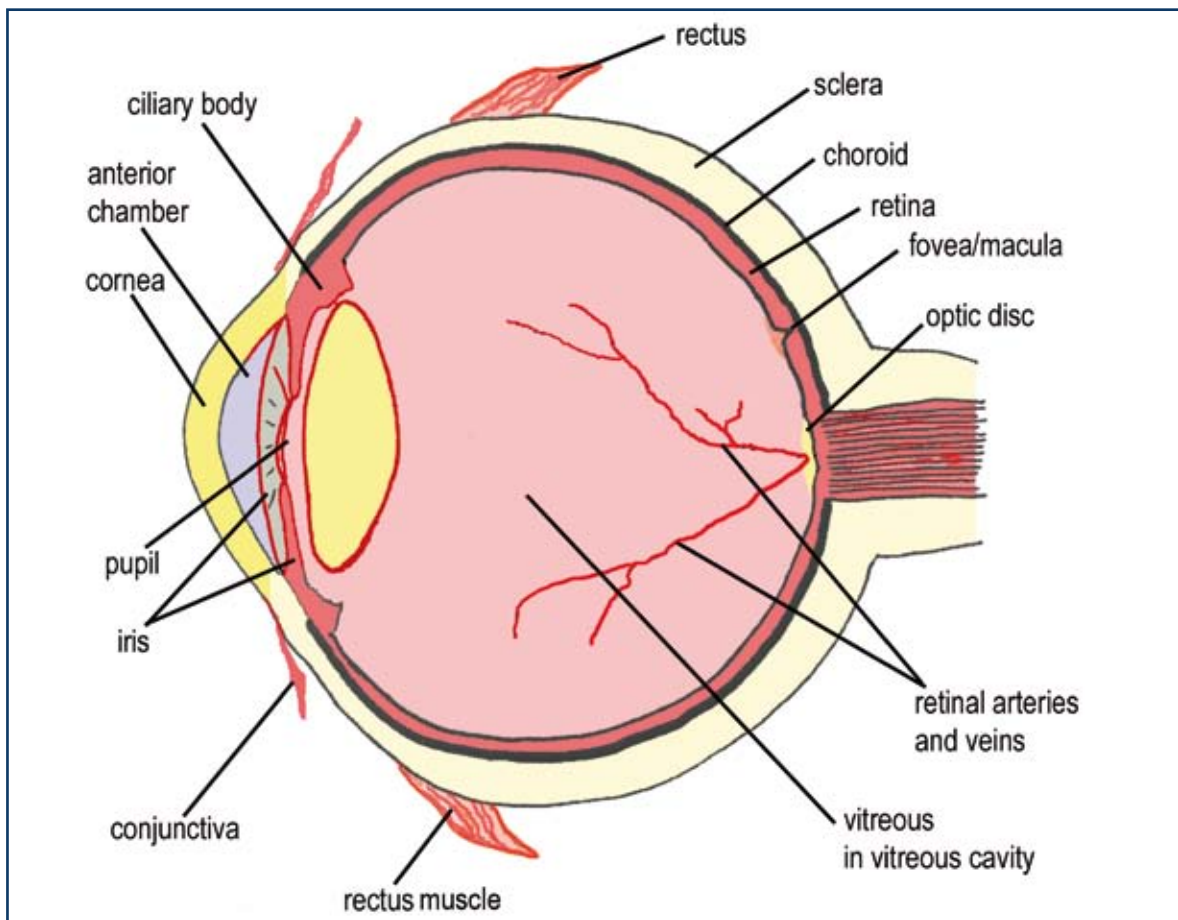
# Anatomy



Anterior surface view



Bony structure – orbit and facial bones



*Horizontal section of a schematic eye*

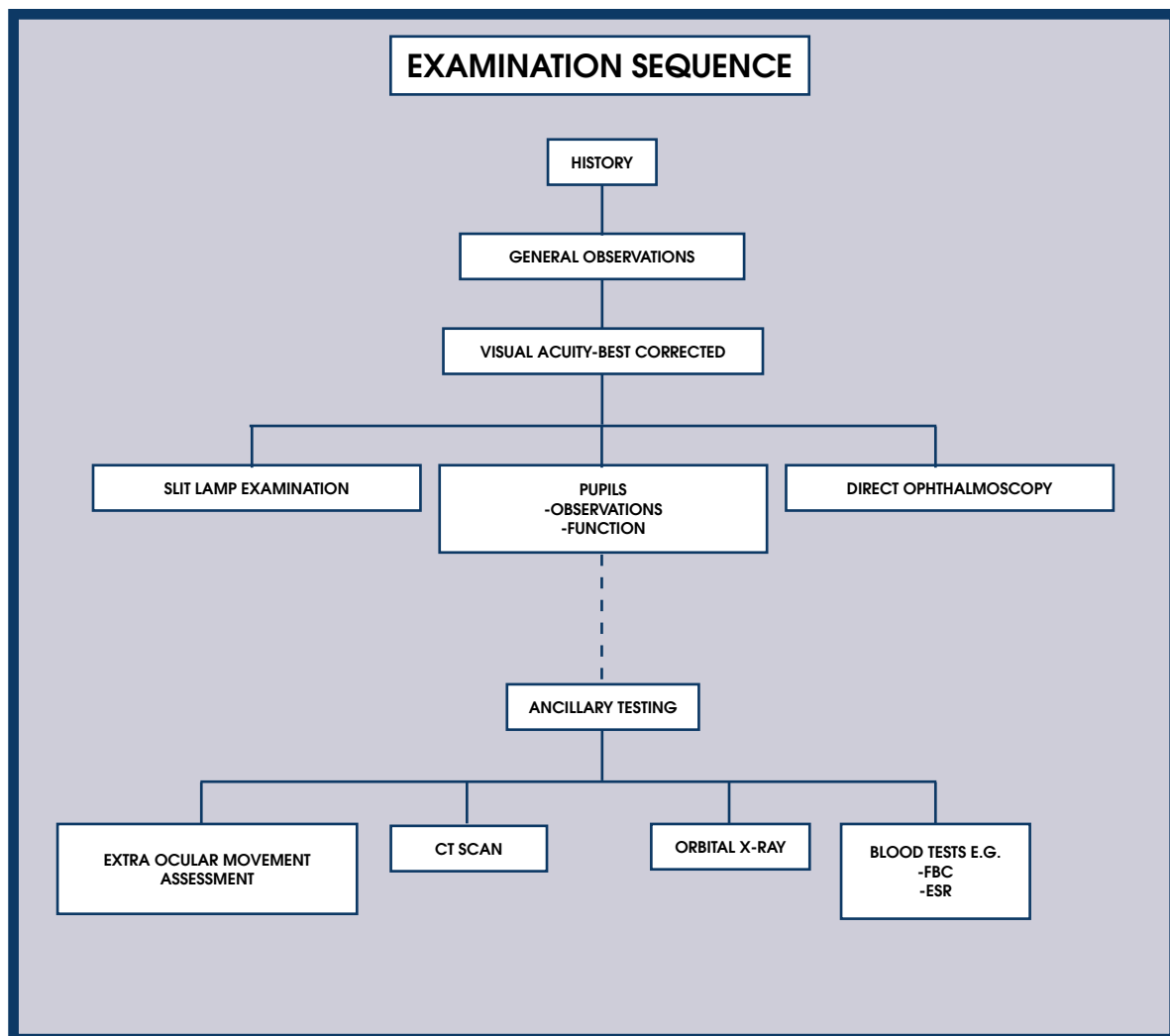


# Chapter Two

# Ophthalmic

# Workup

---






# Ophthalmic Workup

## History


### Important points

The suggested keypoints in the chapters on management are not intended to be the sole form of history taking but rather as an aid to prioritisation and referral.

The suggested questions to be asked when obtaining the history are common to both triage nursing (for urgency weighting) and medical staff.

 **Red flags are used to indicate potentially serious eye problems and should be noted to increase the triage weighting and to indicate whether urgent attention by an ophthalmologist is required.**

TAKING A GOOD HISTORY IS IMPORTANT. Previous ocular history including contact lens wear, eyedrops and surgical procedures.

 If the patient has one good eye only and presents with symptoms in the good eye, referral to an ophthalmologist for review is required.

Always consider the systemic condition and medications.

Good documentation is essential not only for effective communication but is of medicolegal importance.

## Examination

Sophisticated instruments are not a prerequisite for an adequate eye examination:

1. Small, powerful torch.
2. Visual acuity chart to measure visual acuity eg Snellen or Sheridan-Gardiner (see section on visual acuity, p16).
3. Magnification – Handheld magnifying glass/simple magnification loupes. A slit lamp is preferred if available (see later for instructions, p17) and is useful to visualise in detail the anterior structures of the eye.
4. Cotton bud – for removal of foreign bodies or to evert the eyelid.
5. Fluorescein – drops or in strips. A blue light source is required to highlight the fluorescein staining (see section on fluorescein drops, p26) either from a pen torch with filter or slit lamp.
6. Local anaesthetic drops – e.g. amethocaine.
7. Dilating drops (Mydriatics) – e.g. tropicamide 1.0% (0.5% for neonates).
8. Direct ophthalmoscope – to visualise the fundus.

### STANDARD PRECAUTIONS

It is important that Standard Precautions be observed in all aspects of examination:

- Hand hygiene - wash hands between patients
- Wear gloves if indicated
- Protective eye wear, mask and gown should be worn if soiling or splashing are likely
- NB -Tears are bodily fluids with potential infective risk
- Clean the slit lamp using alcohol wipes
- Current NSW Infection Control Policy for specific cleaning & disinfection see p 56

In patients with a red eye:

- Use single dose drops (minims)
- Use separate tissues and fluorescein strips for each eye to reduce risk of cross contamination NB -Viral conjunctivitis

## Visual acuity




Fig 1 6m eye chart (visual acuity ratio in red)

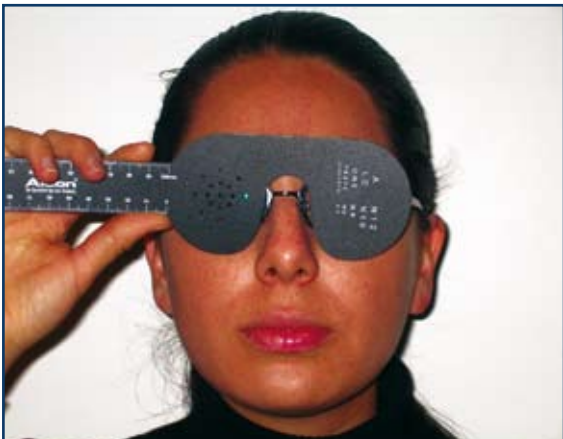


Fig 2 Pinhole occluder

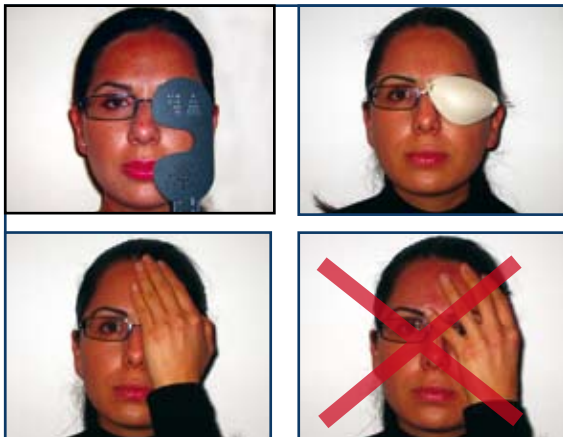

Fig 3

It is important to test the visual acuity (VA) in all ophthalmic patients as it is an important visual parameter and is of medicolegal importance. **A visual acuity of 6/6 does not exclude a serious eye condition.**

The patient should be positioned at the distance specified by the chart (usually 3 or 6m).

Visual acuity is a ratio and is recorded in the form of  $x/y$ , where  $x$  is the testing distance and  $y$  refers to the line containing the smallest letter that the patient identifies, for example a patient has a visual acuity of 6/9 (see Fig 1).

Test with glasses or contact lenses if patient wears them for distance (TV or driving).

### Pinhole

- If an occluder (see Fig 2) is unavailable, it can be prepared with stiff cardboard and multiple 19G needle holes.
- If visual acuity is reduced check vision using a “pinhole”.
- If visual acuity is reduced due to refractive error, with a “pinhole” visual acuity will improve to 6/9 or better.

Test each eye separately (see below for technique)

- Check if the patient is literate with the alphabet (translation from relatives is often misleading). Otherwise consider numbers, “illiterate Es” or pictures.
- It is legitimate to instil local anaesthetic to facilitate VA measurement.
- If acuity is less than 6/60 with the “pinhole”, then check for patient’s ability to count fingers, see hand motions or perceive light.

### Examine each eye (see Fig 3)

- Requires proper occlusion. Beware of using the patient’s hand to occlude vision as there are opportunities to peek through the fingers. Use palm of hand to cover the eye.
- Beware of applying pressure to ocular surfaces.

## Slit-lamp

### Guidelines in using a Haag-Streit slit lamp:

- The patient's forehead should rest against the headrest, and with chin on the chinrest. (see Fig 1).
- Adjust table height for your own comfort and that of the patient when both are seated.
- Position patient by adjusting chinrest so that the lateral canthus is in line with the black line (see Fig 2).
- Set eyepieces to zero if no adjustment for refractive error is required.
- Set the interpupillary distance on the binoculars (see Fig 3).
- Magnification can be adjusted by swinging lever (see Fig 4). Some models differ.
- Set heat filter if required (see Fig 5).
- Use the neutral density filter to reduce discomfort for the patient caused by the brightness of the wide beam. cont.....

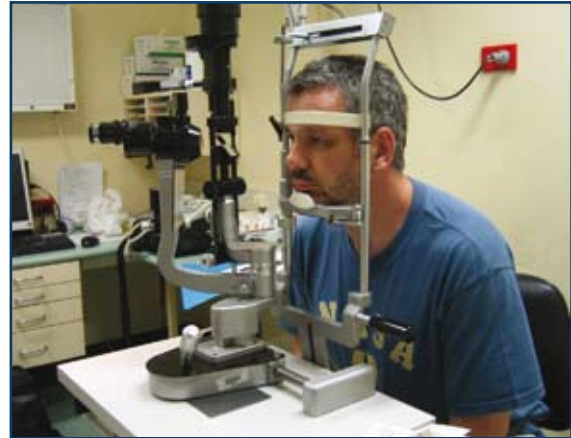

Fig 1 Position patient comfortably

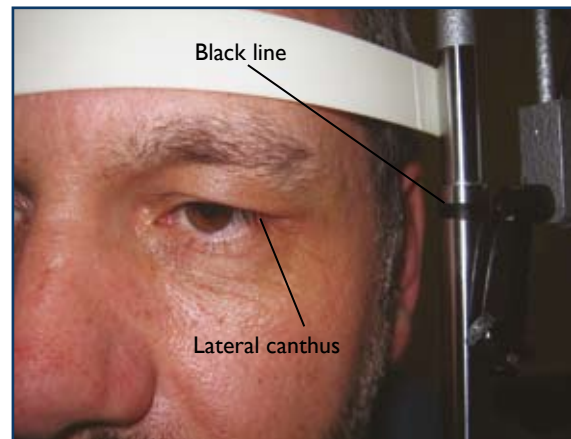


Fig 2 Left lateral canthus in line with black line



Fig 3



Fig 5




Fig 4 To adjust magnification, swing lever




Fig 1 Length of beam 1




Fig 2 Length of beam 2




Fig 3 Width of beam

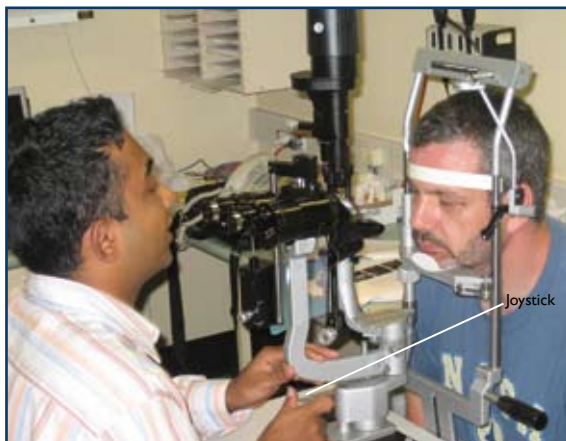


Fig 4 Preparing to position the joystick

- Ask the patient to look at your right ear when examining the right eye and vice versa.
- Turn on the control box, switching power to its lowest voltage.
- Adjust the slit aperture on the lamp housing unit, both the length and width of the beam can be adjusted (see Figs 1-3).
- The angulation of the slit beam light can also be adjusted.
- Focussing of the image is dependent upon the distance of the slit lamp from the subject (eye). Hint: obtain a focussed slit beam on the eye before viewing through the viewfinder.
- Push the joystick forward, toward the patient, until the cornea comes into focus (see Fig 4). If you cannot focus check to see if the patient's forehead is still on the headrest, or use the vertical controls at the joystick.
- Try to use one hand for the joystick and the other for eyeball control, such as to hold an eyelid everted (see p24).

Examine the eye systematically from front to back:

- Eyelashes.
- Eyelid – evert if indicated (see p24).
- Cornea – surface irregularities, transparency and tearfilm.
- Anterior chamber.
- Iris/pupil.
- Lens.
- Vitreous.
- Remember to turn off the slit lamp at the end of examination.

- Focal/Direct Illumination is for corneal examination. Light microscope set at an angle of 45 degrees (see Fig 1).

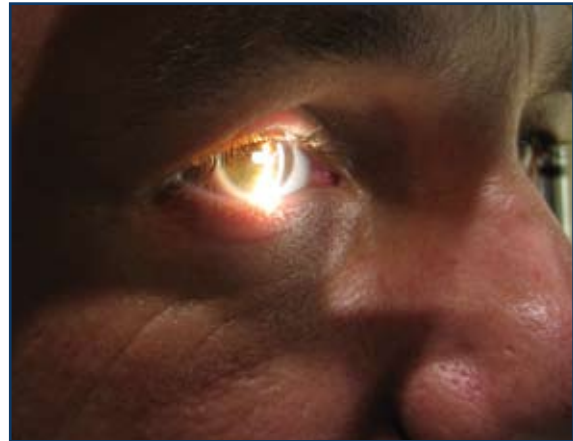

Fig 1 Direct illumination

- Diffuse illumination-wide beam slightly out of focus. Useful for gross alteration in cornea. Can view lids, lashes and conjunctiva (see Fig 2).

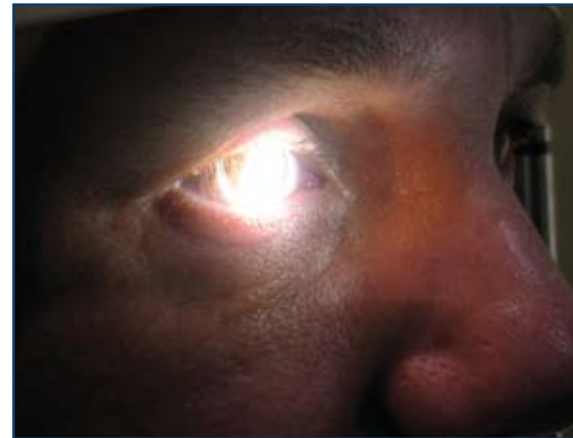

Fig 2 Diffuse illumination

- Optional **cobalt blue light** for fluorescein. Do not use green light filter (see Fig 3).

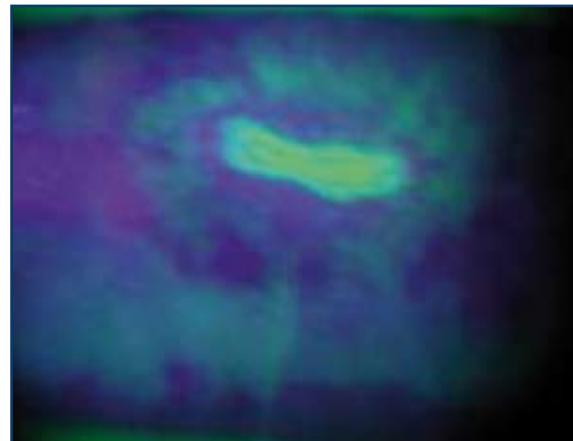


Fig 3 Corneal abrasion with fluorescein

### Cleaning Procedures

Remove chinrest paper if used.

Alcohol wipe over forehead rest, chinrest, joystick and handles.

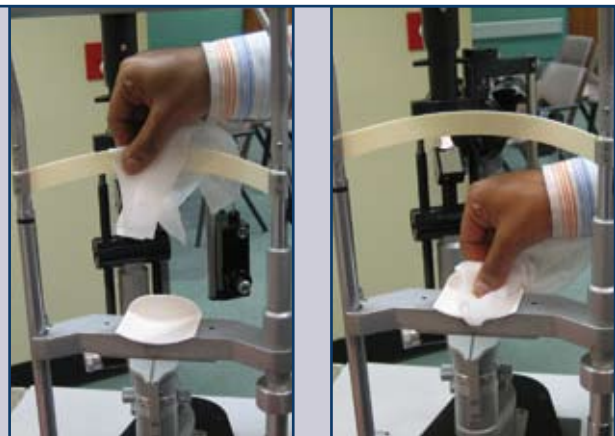
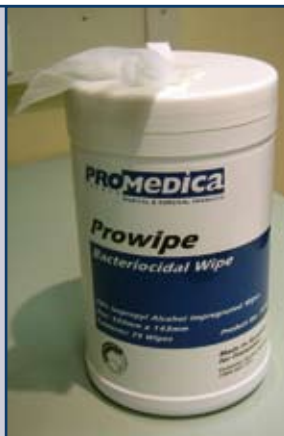


Fig 1 Dioptic correction to zero

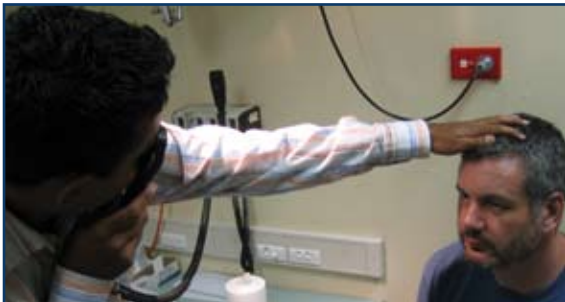

Fig 2 Testing for red reflex

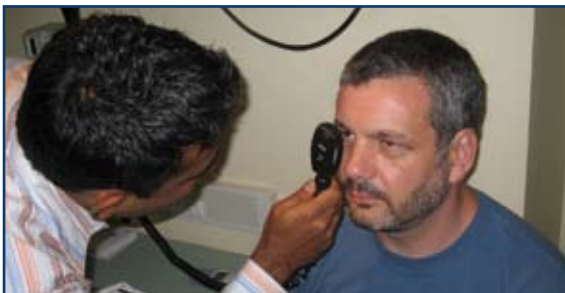

Fig 3 Examiner too far away

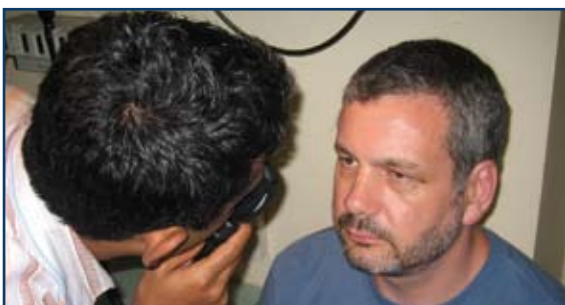



Fig 4 Patient too far away

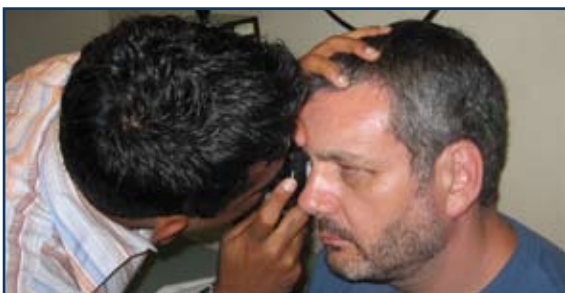

Fig 5 Just right!

## Fundus examination: direct ophthalmoscopy

- Use a dim room for optimum examination
- Examine pupil and iris before dilatation.
- Dilate pupil if possible using a mydriatic (see p26).
-  Do not dilate pupil if suspected head injury or iris trauma.
- Maximise brightness/no filter.
- Set dioptic correction to zero (see Fig 1).
- Have the patient fixate (e.g. the 6/60 letter on the wall chart taking care that your head is not in the way!)
- Test for red reflex (see Fig 2). while viewing from a distance, approximately at an arm's length.
- View fundus – your right eye for the patient's right eye or vice versa.
- Proper positioning of both the examiner and patient is the key to a successful view. Hint: locate a blood vessel, following the vessel will lead to the optic disc (see Figs 3-5).
- Systematic examination (see Figs 6 & 7):
  - Optic disc- size, colour, cupping and clarity of margins.
  - Macula.
  - Vessels for haemorrhage.
  - Elsewhere.

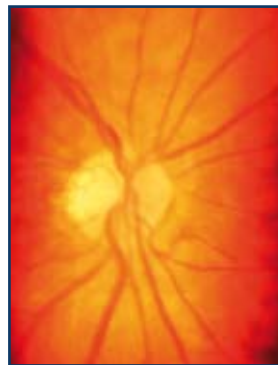


Fig 6 Appearance of the optic disc as viewed through the direct ophthalmoscope

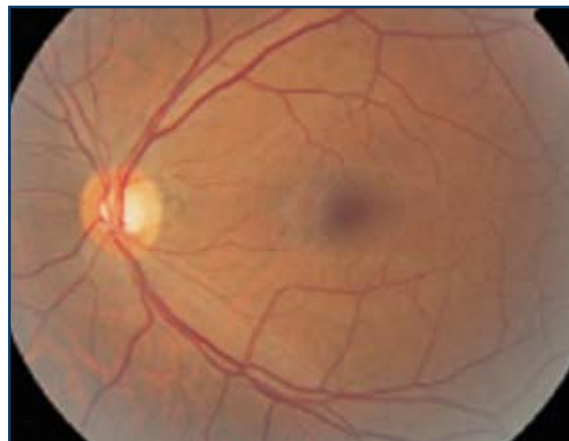


Fig 7 Fundus photograph

## Paediatric examination

### Paediatric Assessment

Assessing a child that may be injured or distressed can be difficult. The task should not be delegated to the most junior or inexperienced ED staff member.

Throughout the assessment it is not necessary to separate the child from its parent.

The first person to see the child or talk to the parents can be of enormous value in preventing or limiting the sequence of an injury and subsequent visual loss.

### History

Obtain a detailed history from an adult witness.

If no such history is available, always suspect injury as a cause of the red or painful eye in a child.

Determine vaccination and fasting status.

### Examination

This commences when the family is first greeted in the waiting room and continues throughout the history taking by simply observing the child.

Visual acuity **MUST** be assessed for each eye. For a preverbal child assess corneal reflections, the ability to fix and follow interesting toys (see Fig 1) or examiner's face, and their reaching responses for objects of interest (see Fig 2). Pupillary reactions should also be assessed. In a verbal child, acuity should be assessed monocularly using a Snellen chart, single letter matching at 3m or picture cards at 3m.

All drops will sting with the exception of plain fluorescein. This should be used in all cases of red or sore eye in a child. Local anaesthetic will sting but may facilitate the child spontaneously opening the eye.

cont.....



Fig 1 Small plastic figurines are useful in obtaining attention and visual fixation in the child



Fig 2 "100's and 1000's" are commonly used to test fine vision in children

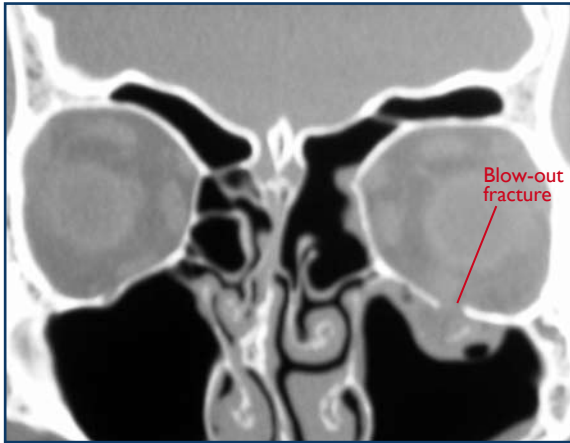

Fig 1 White blow-out fracture

❗ Never try to pry the eyelids of a child apart to see the eye. Inadvertent pressure on the globe may make a perforating injury worse. Strong suspicion of such an injury should be followed by placing a rigid shield on the eye and transporting the patient fasted to the appropriate facility for exploration under anaesthesia.

- A child less than two may require firm but gentle restraint for examination and treatment such as removal of a superficial foreign body. One such attempt should be made with a cotton bud before considering general anaesthetic.

### Specific Conditions

❗ Unexplained periorbital haemorrhage particularly in context with other injuries should arouse the suspicion of non-accidental injury and the child protective services should be contacted.

- Superglue closing an eye can usually be left to spontaneously open or treated by cutting the lashes. Fluorescein should be used as per corneal abrasion.

❗ Purulent discharge in the first weeks of life (ophthalmia neonatorum) should be urgently investigated with microbiology (chlamydia and gonococcus) with systemic treatment. The parents should have appropriate investigations for sexually transmitted disease.

❗ A red, swollen, tender eyelid in a febrile child should be assumed to be cellulitis and admitted to hospital.

❗ A white blow-out fracture occurs with orbital injury with the findings of minimal periorbital haemorrhage, sunken (en-) globe, restricted eye movement in an unwell child (see Fig 1). **Exclude head injury and refer urgently.**



## Pupil examination

- The pupil examination is a useful objective assessment of the afferent and efferent visual pathways.
- Direct/consensual/afferent pupillary defect.

### Terminologies used in pupil examination

- Direct - When one eye is stimulated by light, the eye's pupil constricts directly (see Fig 2).
- Consensual - When one eye is stimulated by light, the other eye constricts at the same time (see Fig 2).
- Relative Afferent Pupillary Defect (RAPD): exists when one eye apparently dilates on direct stimulation after prior consensual constriction and is a result of reduced transmission in the affected optic nerve, regardless of cause. It is tested by the swinging torch test (see Fig 3). Hint: use a powerful torch, minimise the transition time between eyes although allow sufficient time of light stimulation (count to 3).

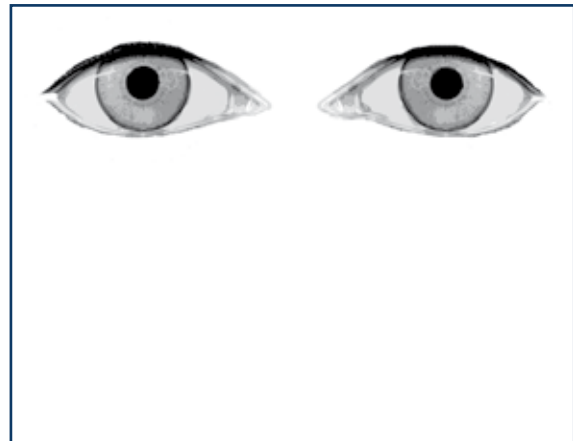


Fig 1 Normal Pupils

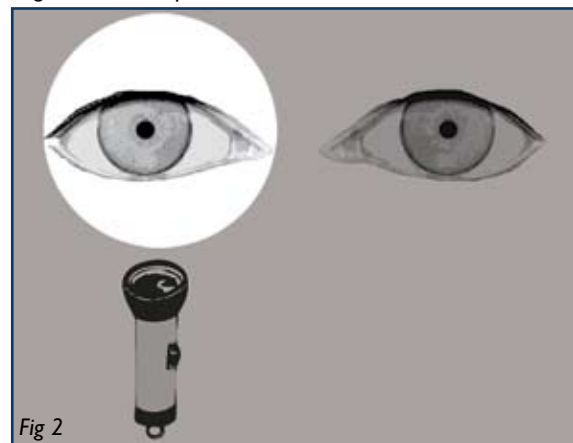


Fig 2

Direct Light Reflex

Consensual Light Reflex

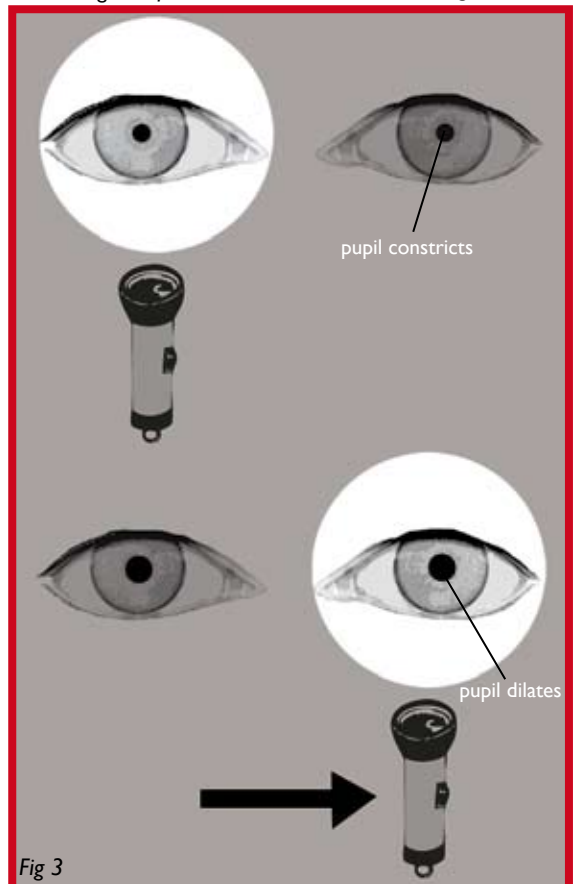


Fig 3

Swinging Torch test - demonstrating a left relative afferent pupillary defect where the left pupil apparently dilates after prior consensual constriction with direct light stimulation of the right eye

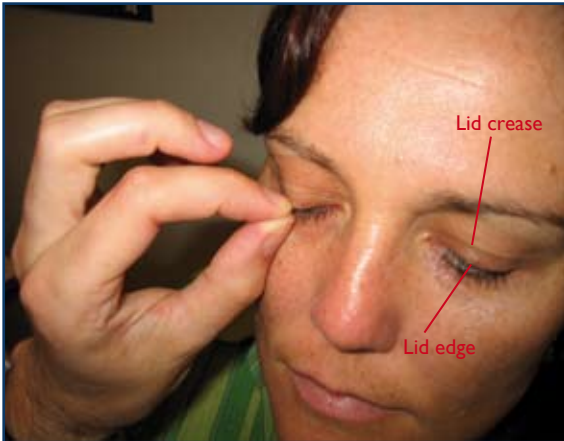

Fig 1

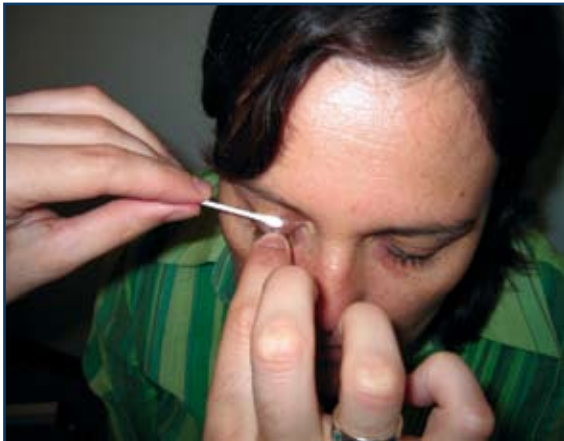

Fig 2

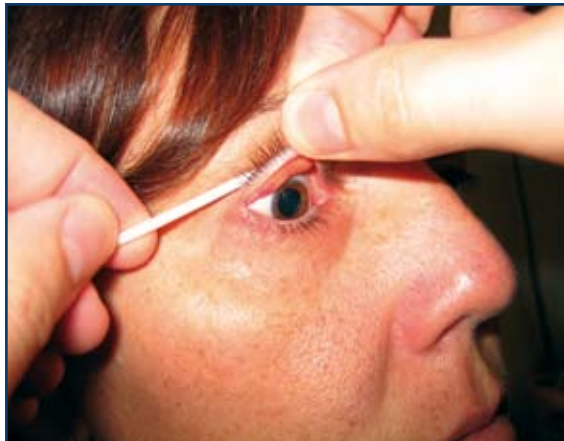

Fig 3

## Treatment

### *Everting eyelids*

- Instruct the patient to keep looking downwards (see Fig 1).
- Place cotton bud at the lid crease (or 5mm from lid edge) and apply very light pressure (see Figs 1 & 2).
- Evert the eyelid over the cotton bud using the eyelashes to gently pull the lid away and upwards from the globe (see Fig 3).

## Eyedrops

### How to instil drops

#### A. Self instillation (see Fig 1).

- Wash hands.
- Uncap the bottle/tube.
- Tilt head up.
- The hand on the opposite side holds the bottle resting on the bridge of the nose of the patient, taking care not to touch any surfaces with the bottle tip.
- Pull down the lower lid with the fingers of the same side so that a visible pocket forms at the space behind the lid.
- Gently squeeze bottle to deliver 1-2 drops.
- Shut eyelid for approximately 1 minute.
- Wipe away excess drops/ointment from face.
- Recap bottle.
- Wash hands.

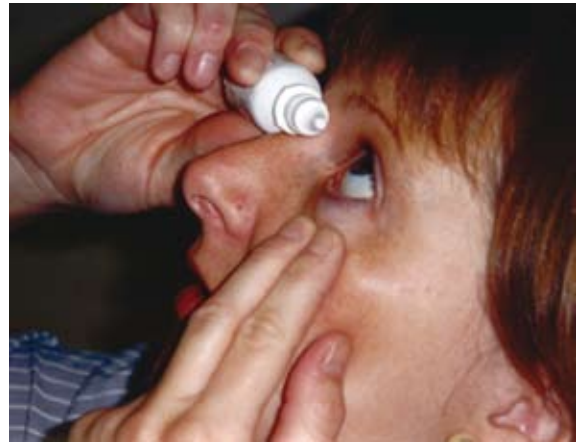

Fig 1 Self instillation of eyedrops

#### B. Health care worker or family member (see Fig 2).

- Wash hands.
- Uncap the container or twist off tab.
- Pull lower eyelid gently down with forefinger to form a pocket.
- Tilt head slightly back and look up.
- Hold the bottle gently between the thumb and forefinger, gently squeeze the recommended number of drops into the pocket formed.
- Do not touch the eye with bottle tip.
- Shut eye and move eyeball from side to side to spread the medication.
- Wash hands.

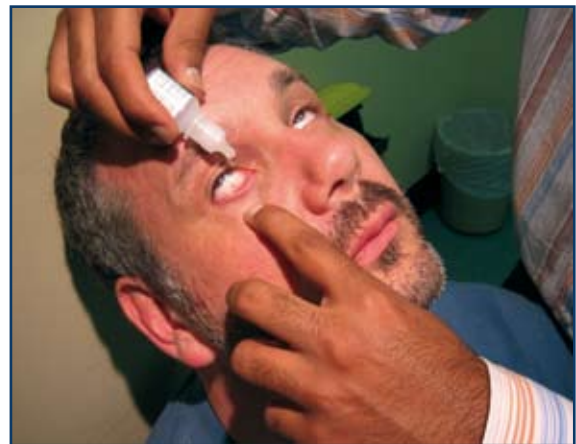

Fig 2 Drops administered by health care worker or family member

## Types of Ocular Drugs

### Local anaesthetic

*Use:* Local anaesthetic drops are used as an aid to the examination of the eye (lasts 10-20 minutes). They are also useful in improving patient comfort in certain procedures such as irrigation of the eye following chemical trauma. **Never give patients anaesthetic drops to take home.** *Common preparations:* Amethocaine 0.5%, Benoxinate 0.4%, 1% Lignocaine from an ampule for injection is satisfactory if minims are unavailable. If required, additional medications such as Panadiene Forte, topical Ketorelac or Homatropine may be used.

### Fluorescein

*Use:* Topically to diagnose abrasions and foreign bodies in the cornea. A cobalt blue light is required to highlight these areas of increased fluorescein uptake – available from either a torch light with a blue filter or the slit lamp. Fluorescein is also used in measurement of intraocular pressure and fundus angiography (specialist use). *Common preparations:* Impregnated paper strips or in drops.

### Mydriatics

*Use:* To dilate the pupil to facilitate examination of the fundus. The relative contraindication to dilatation is in the eye with a shallow anterior chamber as dilatation may precipitate acute angle closure glaucoma. This is an uncommon occurrence and patients should be warned to report for any acute eye discomfort following pupil dilatation (more common in oriental eyes). Vision may be affected so patients should also be instructed not to drive for a few hours following examination, or longer, if vision is blurred. It is normal for the drops to sting for a few seconds post instillation. *Common preparations:* Tropicamide 1.0% (0.5% for neonates). Pupils usually take 15 minutes to dilate and the drops may be repeated if dilation is unsatisfactory. Dark coloured irides may require multiple applications. Non ophthalmologists should only use tropicamide to dilate pupils.

### Basic antibiotics

*Use:* For treatment of acute bacterial conjunctivitis or as prophylaxis against bacterial infection following minor ocular trauma. Available in both

drop and ointment preparations – there are no specific therapeutic differences between the two preparations in the acute situation and usage is based on the prescriber's preference. The actual choice of antibiotic is usually dependent on the availability within the emergency department formulary. Usage is QID (4 times a day) and for 1 week unless directed by the ophthalmologist. *Common preparations:* Chloramphenicol drops (0.5%) or ointment (1.0%), Ciprofloxacin drops, Polymyxin B sulfate drops or ointment, Soframycin drops or ointment.

### Antiviral

*Use:* The most common viral condition is herpes simplex keratitis. This condition will require ophthalmology specialist follow-up. *Common preparations:* Aciclovir (Zovirax) ointment. Initial topical dosage of 5x per day.


### Ocular lubricants – drops and gels

*Use:* In the treatment of the dry eye. This is a very common condition and is characterised by the multitude of products in the market. They are subdivided into drops and gels (longer lasting although may temporarily blur vision) and with or without preservatives (only indicated in severe conditions requiring more than QID dosage and would follow specialist assessment). *Common preparations (brands in brackets):* Hypromellose drops or gel (Genteal, Polytears, Tears Naturale), soft paraffin and lanolin (Lacrilube), Polyvinyl alcohol (Liquifilm, Murine), Carbomer (Polygel, Viscotears).

### Glaucoma drops

Topical glaucoma medications are usually prescribed by the ophthalmologist, but it is important to have an appreciation of the possible systemic side effects of the medications (see Table p27).

### Steroid drops

 There is no indication for the use of steroids by non ophthalmologists.

## Common Glaucoma Medications<sup>1,2</sup>

Generic (Common Brand)	Mechanism of action	Contraindications or Precautions	Common Side effects
Apraclonidine (Iopidine) 0.5%	↓ production ↑ outflow Onset = 1 hr Duration = 3.5 hrs Stat or TDS	Monoamine Oxidase Inhibitors Tricyclic Antidepressants Hypertension Cardiovascular Disease	Hypersensitivity Eye irritation Drowsiness Dry mouth Altered taste
Brimonidine (Alphagan) 0.2%	↑ production ↓↓ outflow Onset = 2 hrs Duration = 12 hrs BD	Monoamine Oxidase Inhibitors Tricyclic Antidepressants Severe Cardiovascular Disease	Hypersensitivity Eye irritation Drowsiness Dry mouth
Timolol 0.25%, 0.5%	↓ production ↑ outflow Onset = 20 min Duration = 24 hrs BD or daily	Asthma Chronic Airways Limitation Bronchospasm Bradycardia Cardiac failure Heart block	Eye irritation Visual disturbances Cardiovascular and respiratory effects Nausea Nightmares
Betaxolol (Betoptic) 0.25%, 0.5%	↓ production ↑ outflow Onset = 30 min Duration = 12 hrs BD	Bradycardia Cardiac failure Heart block (Less) Asthma Chronic Airways Limitation Bronchospasm	Eye irritation Visual disturbances Cardiovascular effects (Less) Respiratory effects Nightmares
Pilocarpine 0.5%, 1%, 2%, 3%, 4%, 6%	↑ outflow QID	Acute iritis	Miosis Hypersensitivity Reduction in visual acuity
Acetazolamide (Diamox) Oral tabs 250mg Injection 500mg	↓ production Variable dosage (diuretic)	Low Na/K Renal or hepatic disease Sulphonamide sensitivity Thirst	Hypersensitivity Electrolyte disturbance Paraesthesia Thirst Dizziness Drowsiness Confusion
Dorzolamide (Trusopt) Brinzolamide (Azopt 1%)	↓ production BD/TDS	Sulphonamide-hypersensitivity Severe renal disease Impaired hepatic function	Sulphonamide-hypersensitivity Eye irritation Bitter taste Blurred vision
Latanoprost (Xalatan) 0.05% Bimatoprost (Lumigan) 0.03% Travaprost Travatan 0.004%	↑ episcleral outflow daily or nocte	Impaired renal function Impaired hepatic function	Eye irritation Blurred vision Brown colouration of iris Darkening of eyelid skin Growth of eye lashes

<sup>1</sup>Included with the permission of Dr Weng Sehu.

<sup>2</sup>An increasing number of combined medications is available.

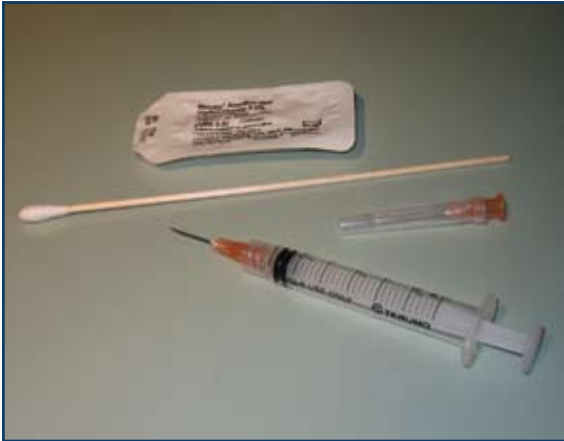

Fig 1



Fig 2

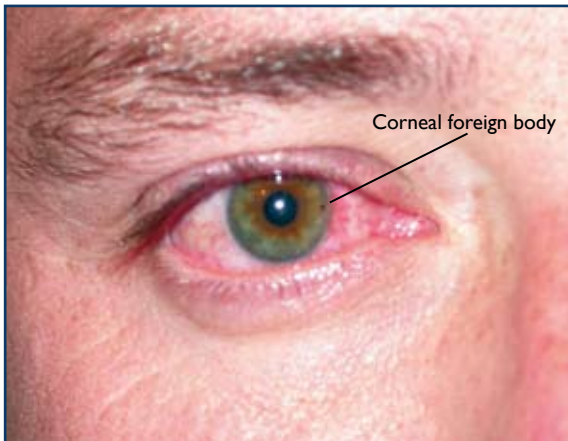

Fig 3 Corneal foreign body (macro)

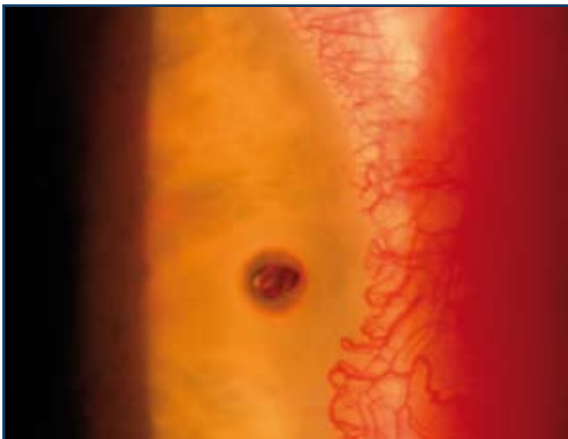


Fig 4 Corneal foreign body (micro)

## Instruments to remove corneal foreign bodies

- Cotton bud (see Fig 1).
- 25-30 g needle (see Fig 1). Use the bevelled surface of instrument angled away from patient's eye. The head should rest against the slit lamp.
- Optional: Motorised dental burr (see Fig 2). **Always obtain prior supervision.**
- See foreign body section for further management (p33).

## Procedure

1. Apply topical anaesthetic agent such as amethocaine 1%.
2. Position patient at slit lamp. Strap or hold head with the help of a colleague.
3. Focus slit lamp.
4. An oblique angular approach is very important (see Figs 5 & 6).

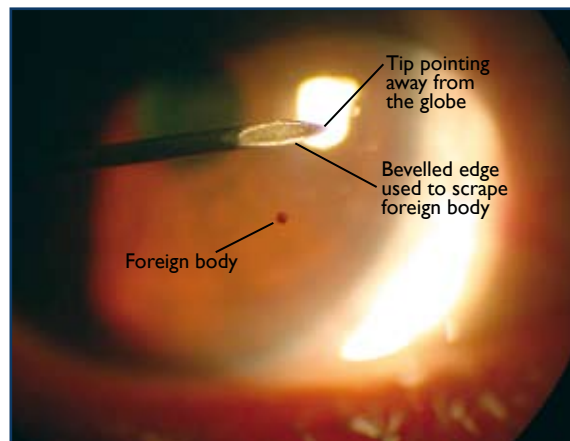


Fig 5 25G needle angled away from patient




Fig 6 Corneal foreign body removal with 25G needle

## How to pad an eye

- NB It is not necessary to pad an eye with minor corneal or conjunctival trauma. Drops are often preferred and are equally as effective as ointment. There are no indications for continued use of topical anaesthesia.
  - Single eye pad (see Fig 1).
  - Secure with three tapes angled away from mouth.
  - Ensure eye is closed when padding the eye.
  - Do not drive with eye padded.
- 
- When to use an eye shield (see Fig 2).
    - Suspected perforation.
    - Protects eye from further compression.
- 
- A modified polystyrene cup can be used if an eye shield is unavailable (see Figs 3 & 4).

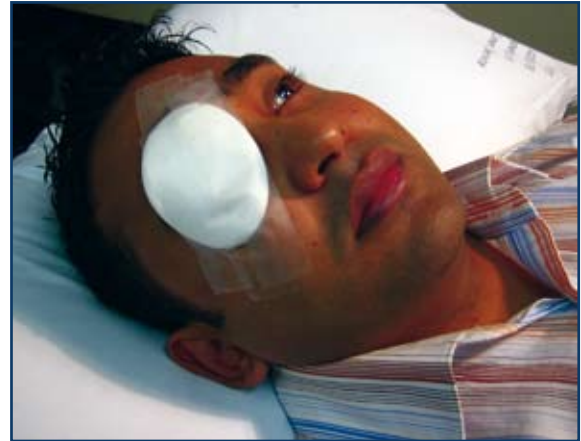

Fig 1 Single eye pad

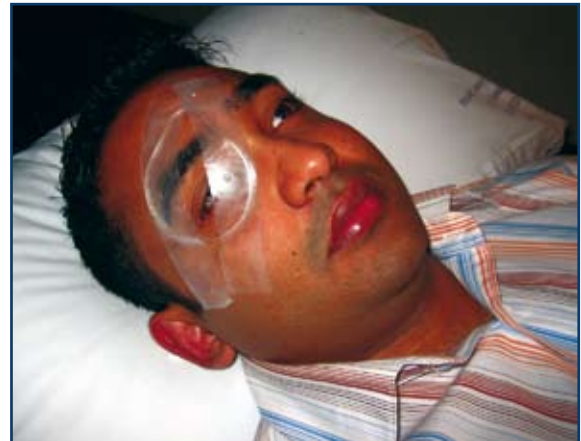

Fig 2 Eye shield

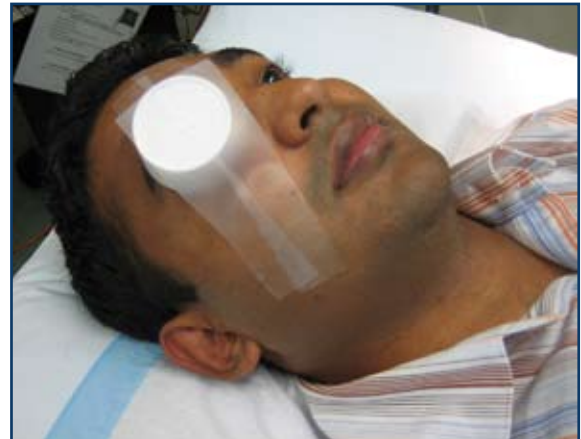

Fig 3 Polystyrene cup



Fig 4 Shield made from a polystyrene cup





# Chapter Three

## Common Emergencies

---

# Common Emergencies<sup>1</sup>

## Trauma

### Lid laceration (see Figs 1 & 2)

ATS CATEGORY 4 (START TREATMENT WITHIN 60 MINS)

Any laceration other than superficial skin that involves the lid margin will need ophthalmological referral. (Check for tetanus immunisation status as per current protocol).

**An eyelid laceration is a potential penetrating eye injury until proven otherwise.**

### History

Four basic questions are:

- which eye is injured?
- how did it happen?
- when did it happen?
- what are the symptoms?

Nature of injury – was there any possibility of penetration into the lid/orbit?

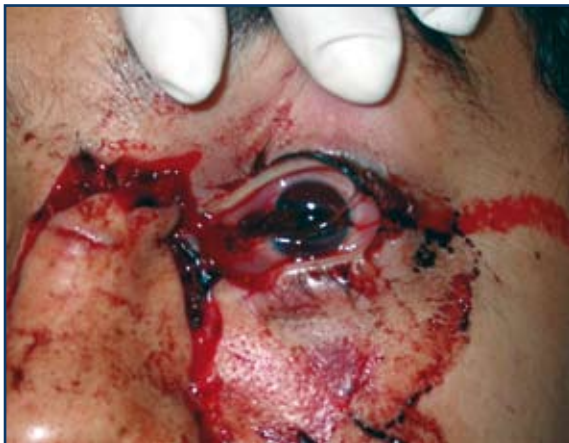

Fig 1 Exploration of an extensive lid laceration

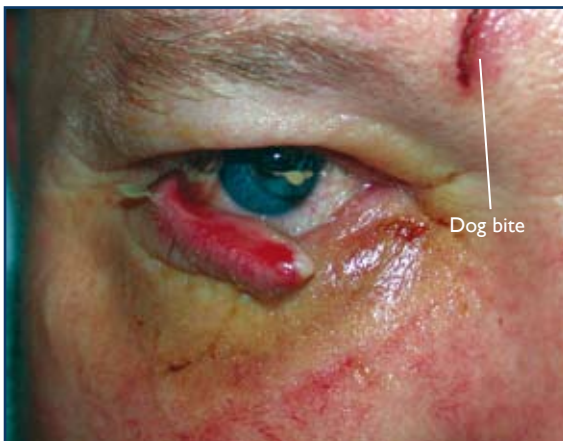

Fig 2 Torn eyelid with avulsed lower lacrimal canaliculus

### Examination

- Wound examination – size and depth.
- All wounds should be explored fully for extent of damage.
- Visual acuity.
- Superficial ocular examination with magnification to assess for any corneal/conjunctival laceration or penetration.
- Further ocular examination including dilated fundus examination as determined by history and examination findings.

### Treatment/Investigation

- Orbital XRay or CT if indicated for foreign bodies or orbital fracture.
- If superficial laceration:
  1. Clean the area and surrounding skin with antiseptic such as betadine.
  2. Subcutaneous anaesthetic with vasoconstrictor (2% lignocaine with adrenaline).
  3. Irrigate and debride the wound thoroughly with saline.
  4. Identify foreign bodies if applicable.
  5. Suture with a 6/0 non-absorbable suture.

### When to refer?

- Referral to an Ophthalmologist:
  1. If the eyelid laceration is associated with ocular trauma requiring surgery such as ruptured globe or intraorbital foreign body.
  2. If the laceration position is nasal to either the upper or the lower eyelid punctum for the possibility of damage to the nasolacrimal drainage system.
  3. If there is extensive tissue loss or distortion of the anatomy.
  4. If there is full thickness laceration or the laceration involves the lid margin.
- Lacerations resulting from human or animal bites will require tetanus prophylaxis. If there is significant risk of contamination, debridement of necrotic tissue with or without broad spectrum systemic antibiotic cover may be required.

<sup>1</sup>Recommended Australasian Triage Scale (ATS) categories have been included where possible (see Appendix 1 for details).

## Corneal foreign body

ATS CATEGORY 4 (START TREATMENT WITHIN 60 MINS)

Any foreign body penetration of the cornea or retained foreign body will need urgent referral.

### History

- What is the likely foreign body?
- Examples include dirt, glass, metal and inorganic material (see Fig 1).
- ❗ Retained organic material may lead to infection; retained metallic foreign bodies may lead to the formation of rust rings that produce persistent inflammation and corneal epithelial defect.
- Velocity of impact?
- ❗ High speed motor drilling without eye protection may lead to a penetrating corneal/scleral injury.

### Examination

- Visual acuity
- Slit lamp – assess for the size, site/s and nature of foreign body and the depth of penetration.
- ❗ Examine the cornea, anterior chamber, iris, pupil and lens for any distortion that may indicate ocular penetration (see p35, *penetrating ocular trauma*) and require urgent referral to an ophthalmologist. Evert the eyelids to exclude retained foreign bodies – remove if appropriate.

### Treatment/Investigation

- Use topical anaesthesia.
- Foreign body removal under slit lamp as directed (see section on corneal foreign body removal, p28).
- Rust rings should be removed by an ophthalmologist.
- Use fluorescein to assess and measure the size of epithelial defect.
- Topical antibiotic (qid) and cycloplegic agent (such as Homatropine 2% or 5%) for comfort. Oral analgesia as required.
- NB It is not necessary to pad an eye (see section on eye padding, p29). Drops are often preferred and are equally as effective as ointment in a healing corneal wound with the added advantage for the patient in having the use of both eyes. There are no indications for continued use of topical anaesthetic drops.

- Daily visual acuity and slit lamp review until complete healing of defect. The defect should be measured (see section on slit lamp examination p28) and compared with previous findings.

### Follow up - When to refer?

- ❗ Follow-up and referral depend on the size and location of the abrasion:
  1. within 24 hours: if foreign body is not completely removed.
  2. urgently if the underlying surface defect is opaque and is indicative of an abscess.
  3. if there is a persistent epithelial defect (more than 3 days).
- ❗ If the patient is a contact lens wearer, he/she should be advised to discontinue lens usage until the defect is fully healed and feels normal for at least a week.

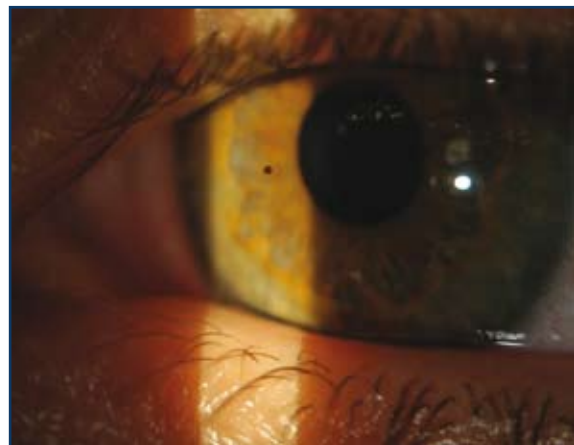

Fig 1 Corneal foreign body

## Ocular trauma

ATS CATEGORY 3 (START TREATMENT WITHIN 30 MINS)

### History

- ▀ Mechanism of trauma – any history suggestive of a penetrating trauma requires prompt assessment with the possibility of urgent referral to the specialist.
  - The type of projectile and the likely velocity (e.g. low or high) should be documented.
- ▀ Small projectiles at high velocities increase the likelihood of penetrating trauma. Symptoms include loss of vision, pain on movement and diplopia.
  - Was the patient wearing eye protection?
  - Any previous history of ocular trauma or previous surgery is to be documented and may suggest reduced integrity of the wall of the globe.

### Blunt

ATS CATEGORY 3 (START TREATMENT WITHIN 30 MINS)

**Closed globe injury:** Blunt trauma to the eye may result in considerable damage to the intraocular contents. Fracture of the orbital wall may occur due to the transfer of mechanical

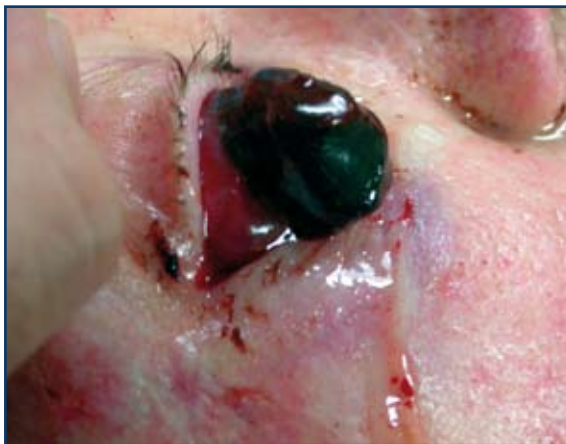

Fig 1 Ruptured globe

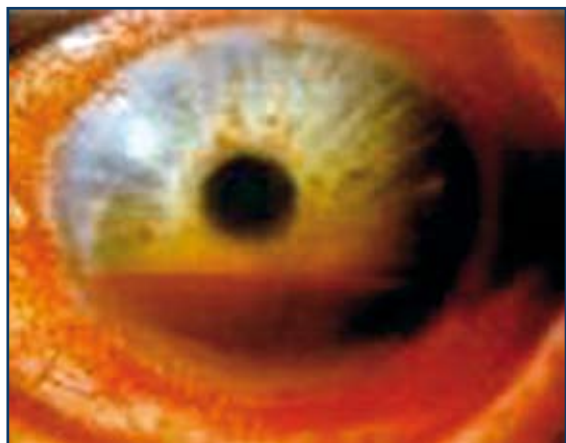

Fig 2 Hyphaema-blood in the anterior chamber

energy to relatively thin orbital bone.

**Ruptured globe** (see Fig 1): Trauma of sufficient force may result in globe rupture and typically occurs in the areas where the scleral wall is thinnest: at the limbus (which would be visible via the slit lamp) or behind the insertion of the rectus muscle (which would result in reduced ocular motility, loss of red reflex and vitreous bleeding).

### Examination

- Visual acuity.
- Ocular movements – if there is considerable eyelid oedema, carefully lift up the lid while viewing the eye to ensure there is no obvious rupture.
- ▀ Reduced movement may suggest ruptured globe or orbital wall fracture.
  - Slit lamp – looking for evidence of rupture (often at the limbus). Examine for blood in the anterior chamber, (see Fig 2). Examine the eyelid for lacerations (see p35 for further management).
  - Ophthalmoscopy – Red reflex (missing in intraocular haemorrhage or retinal detachment). Look for any retinal pathology (after dilating the pupil).

### Investigations

- CT scan (axial and coronal) or orbital wall fracture if indicated (see p38).

### Follow up - When to refer?

- Routine referral if the above findings are negative.
- ▀ **Urgent referral to an ophthalmologist** if findings are suggestive of intraocular haemorrhage, ruptured globe or orbital wall fracture (also see p38).

### Treatment

- Topical antibiotic drops for superficial trauma.
- Suture any eyelid lacerations as indicated in eyelid trauma section (see p32).

## Sharp (penetrating)

ATS CATEGORY 3 (START TREATMENT WITHIN 30 MINS)

- ▀ **All penetrating trauma should be referred following appropriate workup.**

### Examination

Examination may only need to be cursory if the trauma is obvious otherwise: –

- Visual acuity.
- Direct ophthalmoscopy – loss of red reflex may suggest retinal trauma or detachment.
- Slit lamp – looking for distorted anterior chamber structures or corneal/scleral breaks.

### Treatment

- ▀ **Urgent referral to ophthalmologist.**
  - Ensure nil by mouth status. Strict bed rest. Injectable analgesia/antiemetic if required.
  - CT scan of the orbit to exclude retained ocular/orbital foreign body after discussion with ophthalmologist (see Fig 2).
  - Shield (not pad) the eye making sure not to increase the intraocular pressure with further loss of ocular contents. (See section on eye padding/shields, p29).
  - No ointment for penetrating eye injury.
  - Check for tetanus immunisation status as per current protocol.
  - Commence broad spectrum IV antibiotics.

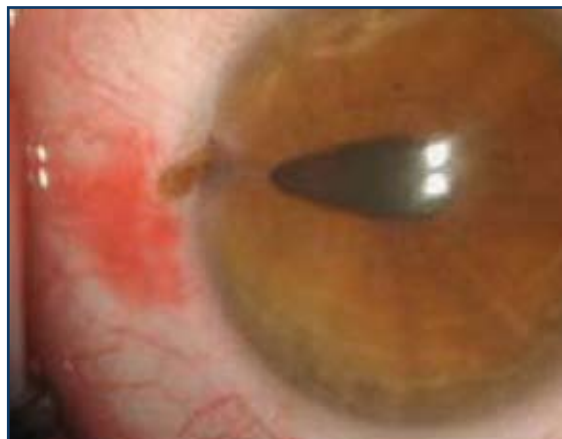


Fig 1 Distorted pupil with iris prolapse

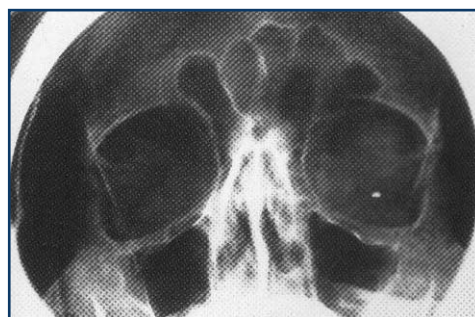


Fig 2 Intraocular foreign body

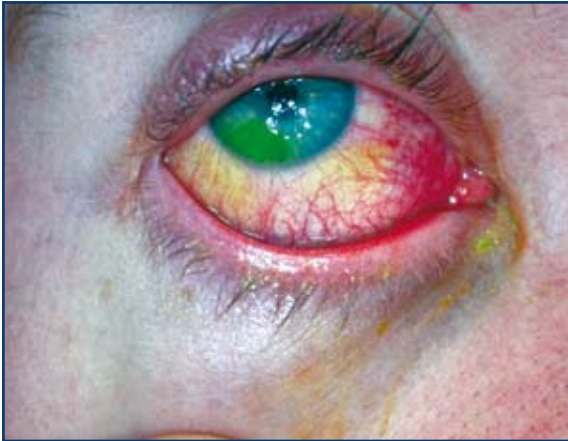

Fig 1 Acute alkali chemical injury: mild-moderate

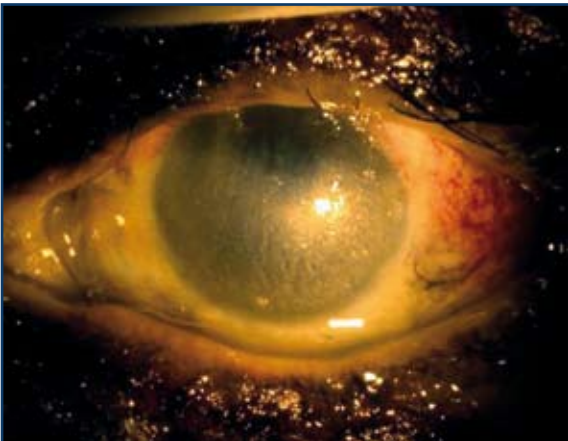


Fig 2 Acute alkali chemical injury: severe



Fig 3 Universal Indicator Paper

## Chemical Burns

ATS CATEGORY 2 (ASSESS & TREAT WITHIN 10 MINS)

### IMMEDIATE

🚩 **Copious irrigation with any neutral fluid (e.g. normal saline, Hartmann's solution) for at least 30 minutes.**

**Continue until pH normalises around 7.5. As a guide, check pH after each litre of fluid used.** (See Examination section below).

- **If the patient has difficulty in opening eyes, topical anaesthesia will be required.**
- **Remove any foreign body in the fornices if immediately evident with a cotton bud or glass rod.**

### History

- When did it occur?
- What is the chemical? (e.g. acid/alkali – alkalis are more harmful to the eye).  
Examples of acids include: toilet cleaner, car battery fluid, pool cleaner. Examples of alkalis include: lime, mortar & plaster, drain cleaner, oven cleaner, ammonia.
- Any first aid administered and how soon after the incident?

### Examination

- Use topical anaesthesia.
- The degree of vascular blanching, particularly at the limbus is proportional to severity of chemical burn (see Figs 1 & 2) for comparison).
- Measurement of the pH is possible by stopping irrigation for 1 minute and using universal indicator paper to sample the fornical space (see Fig 3).
- While awaiting ophthalmological opinion, examine the fornices and palpebral fissures for any residual chemical or material – remove if necessary with cotton bud or forceps.
- Test visual acuity.

### Treatment

- The immediate treatment is indicated above.
- Contact poisons information or the chemical manufacturer for further information if required.

🚩 **All patients should be referred to an ophthalmologist on the same day.**

## Flash Burns

ATS CATEGORY 4 (START TREATMENT WITHIN 60 MINS)

### History

- Electric arc welding or sun lamp without eye protection with symptoms appearing typically within several hours.
- Symptoms are usually intense pain, red eye, blepharospasm and tearing.

### Examination

- Use topical anaesthesia in the examination.
- Visual acuity.
- Slit lamp – widespread superficial epithelial defects staining with fluorescein, often bilateral. There may be also conjunctival injection.

### Treatment

- Topical antibiotic (qid) and cycloplegic (e.g. homatropine 5% bd) for comfort for 3 days. Oral analgesia as required. Patients are informed to re-present if symptoms have not improved appreciably after 24 hours.

## Other

### *Unexplained Non-Accidental Injury (NAI)*

As well as an ophthalmological examination (fundus) and treatment, all children should be referred to the appropriate paediatric team as per hospital protocol.

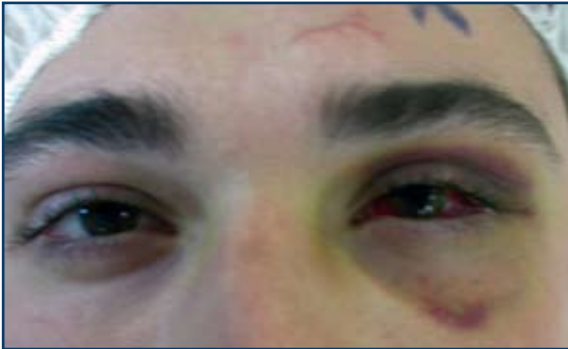

Fig 1 Blow-out fracture

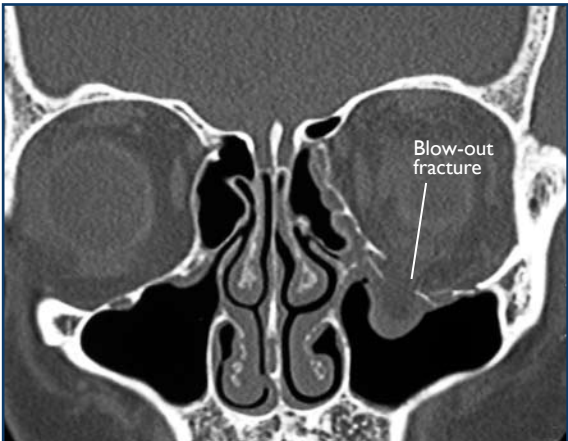


Fig 2 Coronal CT scan: Left blow-out fracture

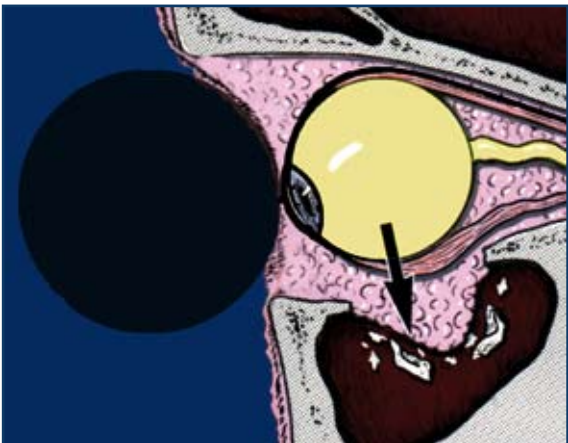

Fig 3 Blow-out fracture - squash ball hits eye

## Orbital

### Blow-out Fracture (Figs 1-6)

ATS CATEGORY 4 (START TREATMENT WITHIN 60 MINS)

#### History

- Mechanism of injury - for example squash ball, punch with a fist.

#### Symptoms

- Pain (especially on vertical movement), local tenderness, diplopia, eyelid swelling and crepitus after nose blowing.
- A “white” blow-out fracture occurs with orbital injury with the findings of minimal periorbital haemorrhage, sunken (enophthalmic) globe, restricted eye movement in an unwell child.

**Exclusion** Exclude head injury and refer urgently.

#### Signs

- Nose bleed, ptosis and localised tenderness.

#### Examination

- Complete ophthalmological examination.
- Sensation of affected cheek compared with that of the contralateral side.
- Infraorbital nerve involvement is demonstrated by anaesthetic upper teeth and gums on the affected side.
- Palpate eyelid for crepitus.

#### Investigation

- Computed tomography (CT) scan of the orbits and brain (axial and coronal views).



## Treatment

- Nasal decongestants for 7-10 days.
- Broad spectrum antibiotics.
- Instruct patient not to blow his or her nose. (Avoid valsalva manoeuvre).
- Ice pack to the orbit for 24-48 hours.

## Follow up - When to refer?

- Patients should be seen within 1-2 weeks post trauma and evaluated for persistent diplopia or enophthalmos.
- Surgical repair if necessary is usually performed 7 to 14 days after trauma

**Referral to ophthalmologist** for all cases with:

1. Suspected or documented orbital floor fractures.
2. Evidence of ocular injury (see *Ocular Trauma*, p34).

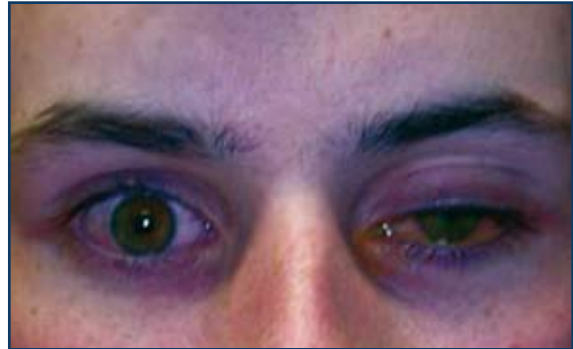

Fig 4 Left periocular ecchymosis and oedema with enophthalmos

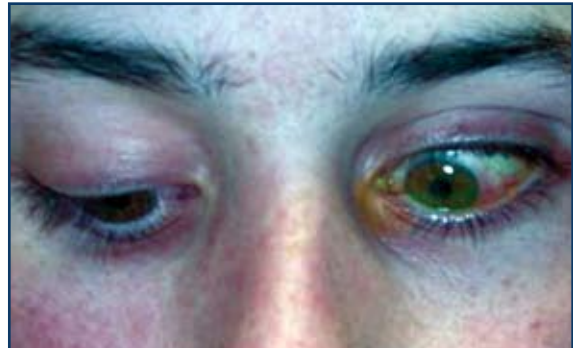

Fig 5 Ophthalmoplegia-typically in up- and down gaze (double diplopia)

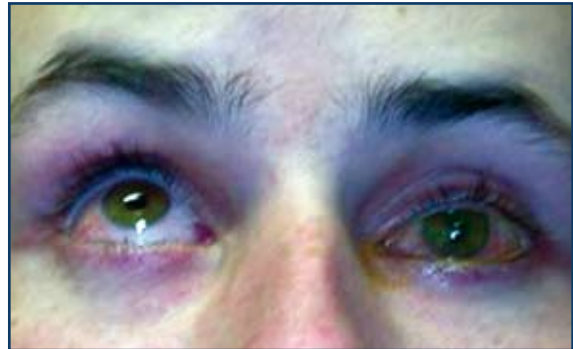

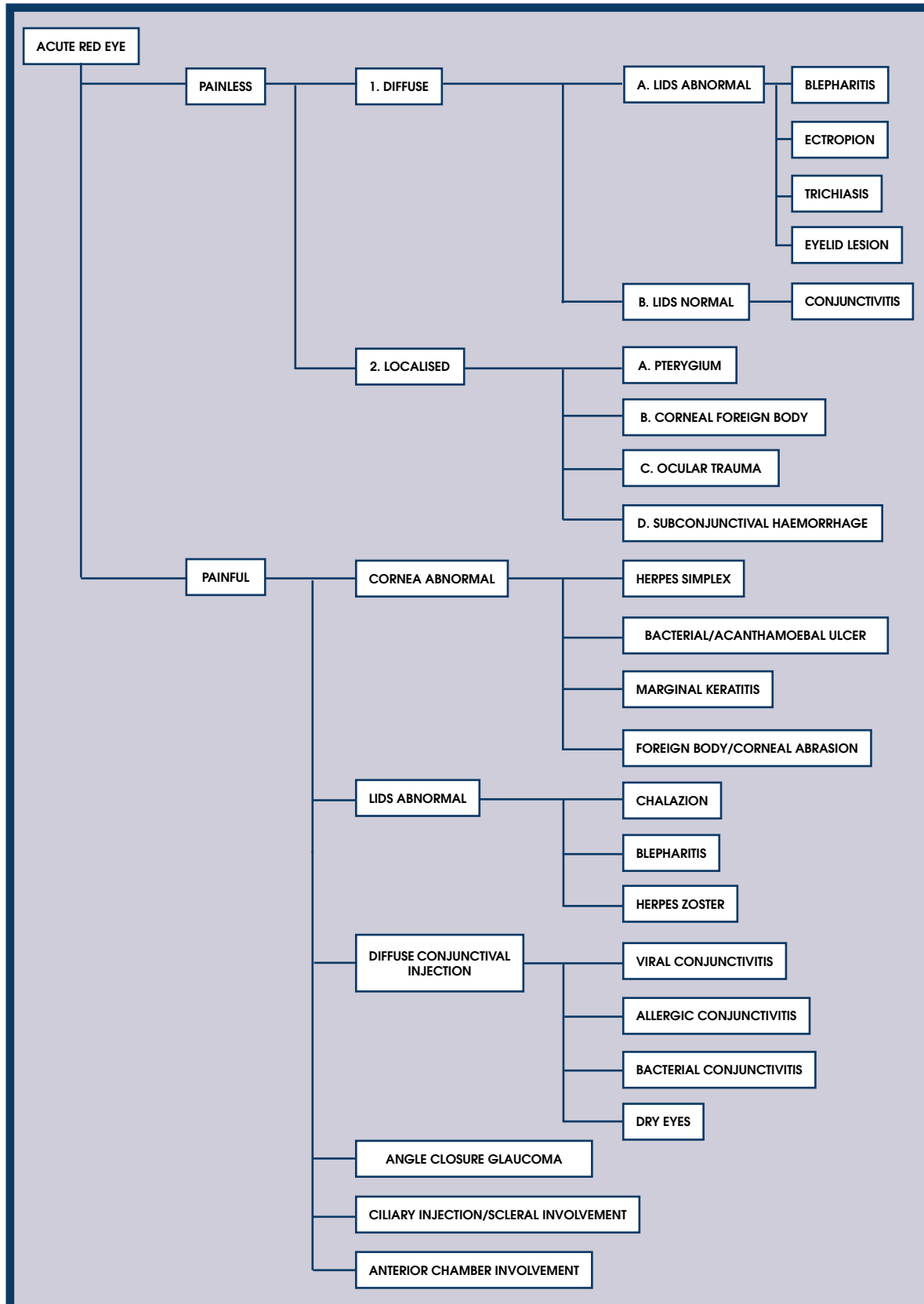
Fig 6 Ophthalmoplegia-typically in up- and down gaze (double diplopia)

## Acute red eye<sup>1</sup>

There are many conditions that can lead to a patient presenting with a red eye. A useful distinguishing feature is whether the condition

is painful or painless, and with further slit lamp examination for specific features.

**Beware in making the diagnosis of a monocular conjunctivitis until more serious eye disease is excluded.**



<sup>1</sup>Included with the permission of Dr Weng Sehu.

## Painless

ATS CATEGORY 5 (START TREATMENT WITHIN 120 MINS)

It is rare for a painless red eye to require an urgent ophthalmological assessment.

Extent of conjunctival redness:

### I. Diffuse

ATS CATEGORY 5 (START TREATMENT WITHIN 120 MINS)

#### A. Lids abnormal

**Blepharitis** (Fig 1)-(non specific generalised inflammation of the eyelids). Treat with daily lid hygiene (ref: [www.health.nsw.gov.au/topics/index.html](http://www.health.nsw.gov.au/topics/index.html)), lubrication as required with routine referral.

**Ectropion** (Fig 2)-(lids turning outwards with exposure of conjunctival sac)—topical lubrication with routine referral.

**Trichiasis**-epilate, lubricate with routine referral.

**Entropion** (Figs 3 & 4)-(lids turning inwards with eyelids abrading cornea)—check condition of cornea with fluorescein.

*Intact cornea:* lubrication with routine referral.

*Epithelial defect:* Tape back eyelid away from the cornea and manage as for corneal foreign body.

**Eyelid lesion** (Fig 5)-provided there is no overt eyelid infection/inflammation and no ocular involvement, routine referral. Consider topical antibiotics.

#### B. Lids normal

Use fluorescein to stain the corneal surface.

**Conjunctivitis** – most cases are painful. (Refer to page 45 for further detail).

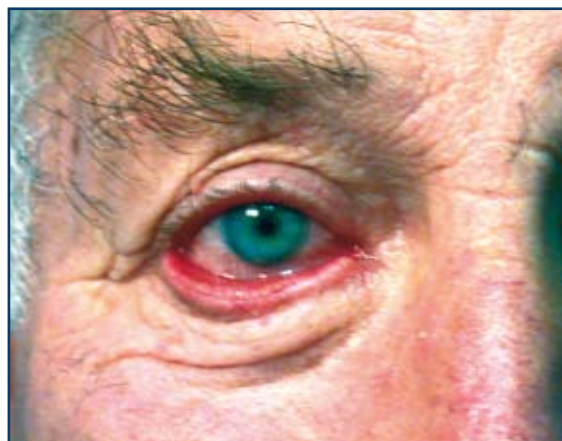

Fig 2 Ectropion

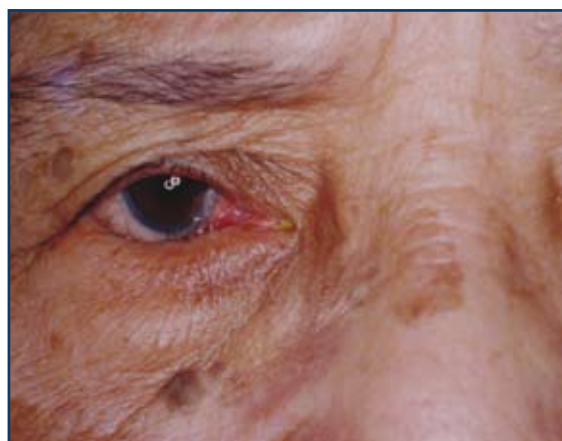


Fig 3 Entropion




Fig 4 Entropion - Corneal abrasion

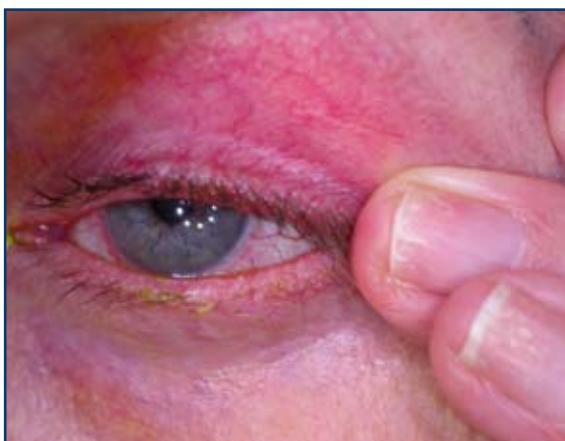

Fig 1 Blepharitis

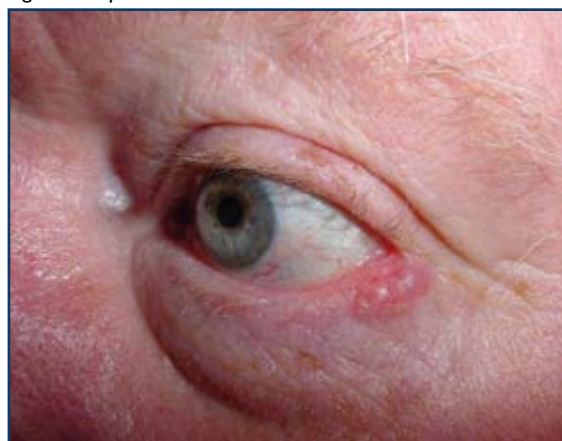


Fig 5 Lesion of left lower eyelid

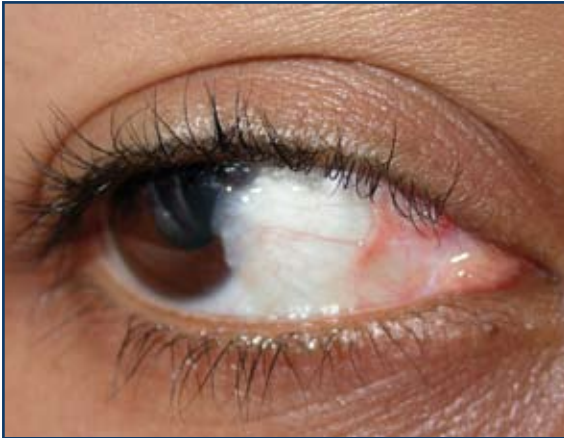

Fig 1 Pterygium

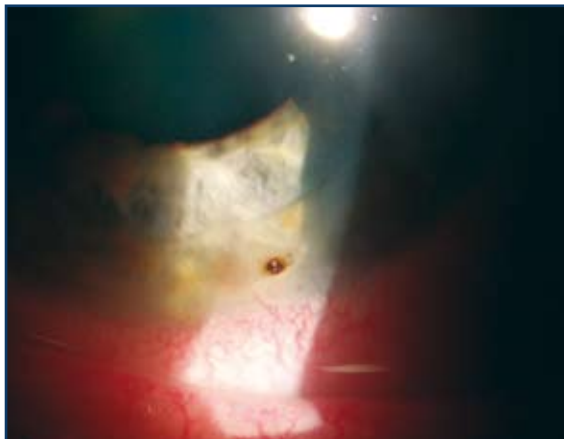


Fig 2 Corneal foreign body

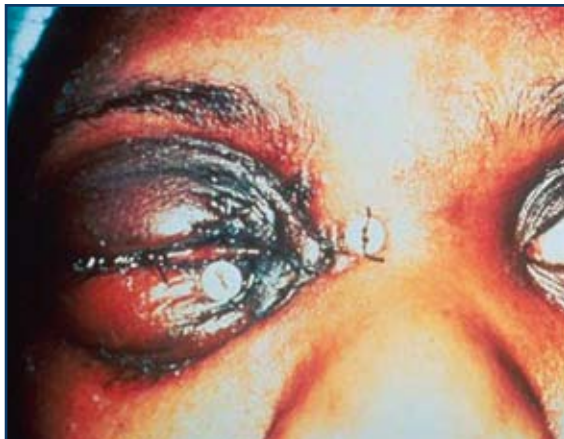

Fig 3 Ocular trauma

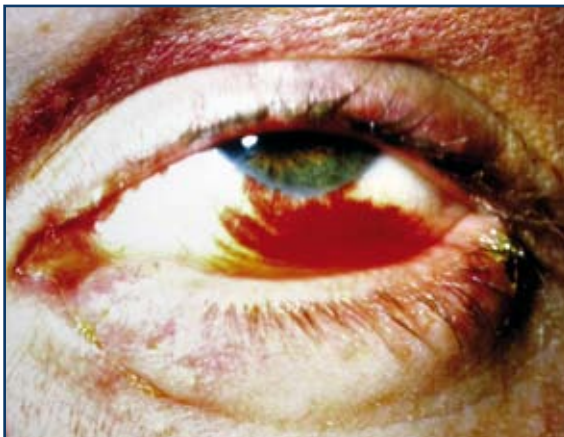

Fig 4 Subconjunctival haemorrhage

## 2. Localised

ATS CATEGORY 5 (START TREATMENT WITHIN 120 MINS)

Examine for specific conjunctival lesions.

### A. Pterygium (Fig 1)

- A raised, yellowish fleshy lesion at the limbus that may become painful and red if inflamed.
- Treatment: lubrication and sunglasses.
- Routine ophthalmological referral for further management.

### B. Corneal foreign body (Fig 2)

- Remove foreign body, treat with topical antibiotics. (See section on corneal foreign body, p28).

### C. Ocular trauma (Fig 3)

- Treat with topical antibiotics if trauma area is small otherwise as for corneal foreign body/blunt or penetrating trauma. (See sections on corneal foreign body and ocular trauma starting p34).

### D. Subconjunctival haemorrhage (Fig 4)

- Blood redness: unilateral, localised and sharply circumscribed.
- Underlying sclera not visible.
- No inflammation, pain or discharge.
- Vision unchanged.
- Possible association with minor injuries including rubbing.
- Common with use of antiplatelet agents and anticoagulants.
- Treatment:
  1. Check BP.
  2. Blood coagulation studies or INR if indicated.
  3. Lubricate.
- Routine referral if condition worsens or pain develops.

## Painful

### I. Cornea abnormal

ATS CATEGORY 4 (START TREATMENT WITHIN 60 MINS)

Use fluorescein to ascertain nature of any epithelial defect.

**A. Herpes simplex infection (Figs 1,2 & 3):**

- Dendritic ulcers.
- Treat with topical acyclovir.
- Referral following day.

**B. Bacterial or acanthamoebal ulcer (Fig 4):**

- Often history of contact lens wear.
- Epithelial defect with an opacified base.

**Urgent referral, may require admission for microbiological investigation and intensive antibiotic treatment.**

**C. Marginal keratitis (Fig 5):**

- Secondary to blepharitis.
- Ulcer is situated at the corneal periphery.
- Requires discussion with ophthalmologist.

**D. Foreign body/Corneal abrasion:**

- As directed in the previous sections (see p19 (corneal abrasion with fluorescein), p28 & p33).

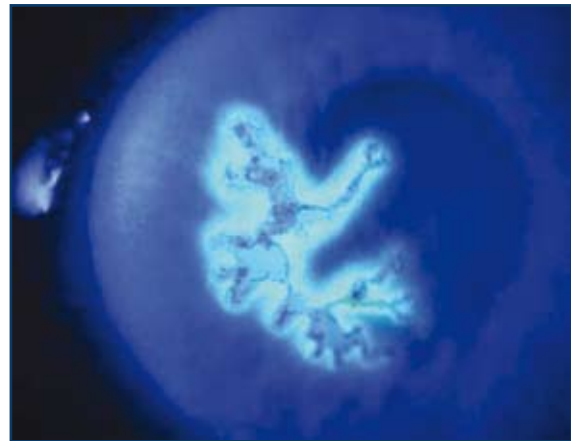


Fig 2 Herpes simplex keratitis dendritic ulcer with terminal bulbs

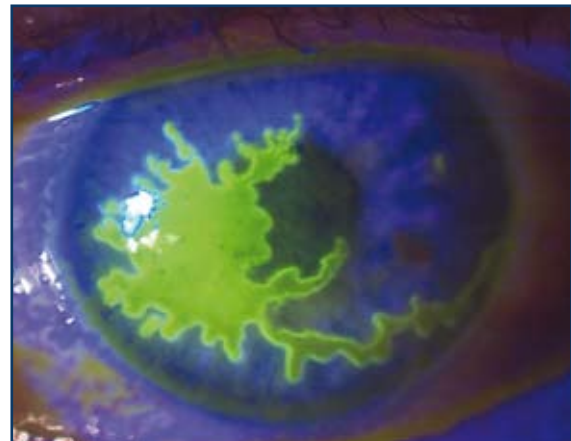


Fig 3 Herpes simplex keratitis- Steroid complication

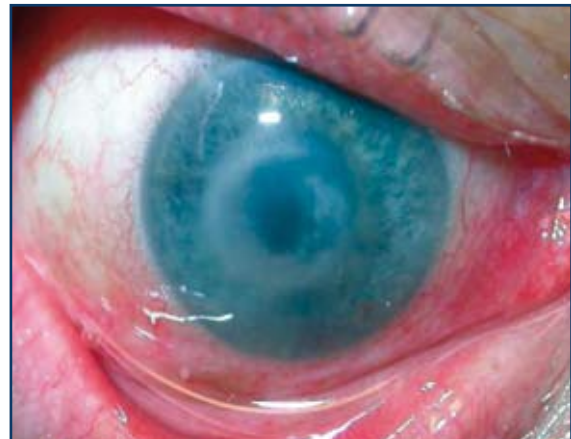

Fig 4 Bacterial ulcer

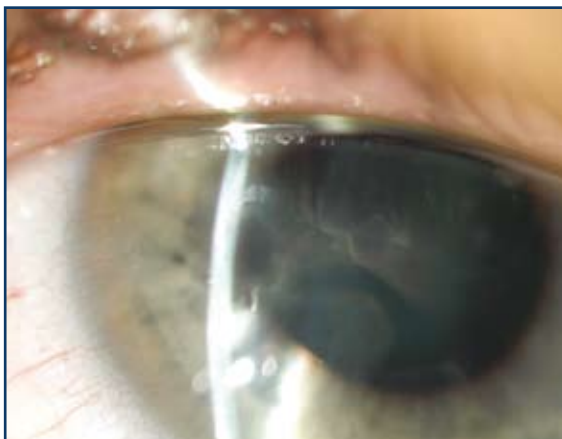


Fig 1 Herpes simplex keratitis

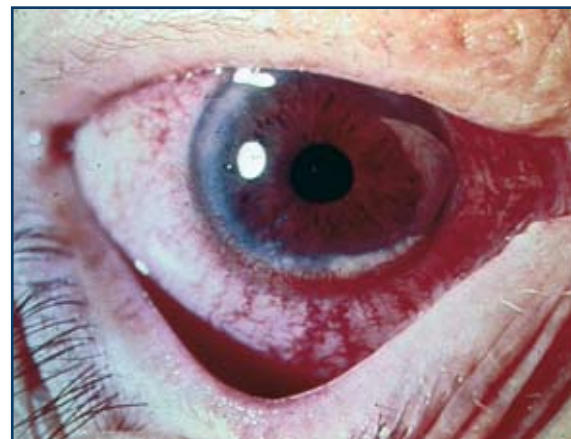


Fig 5 Marginal keratitis

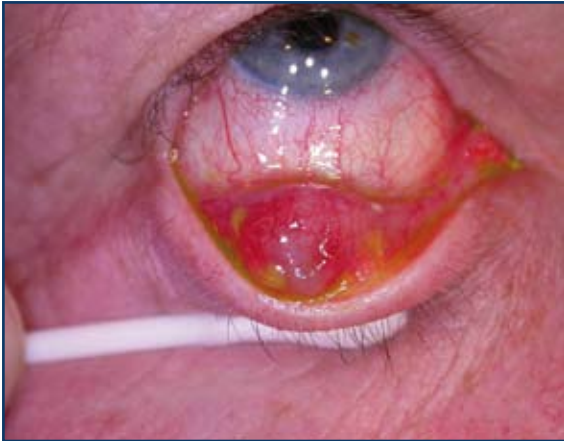

Fig 1 Chalazion

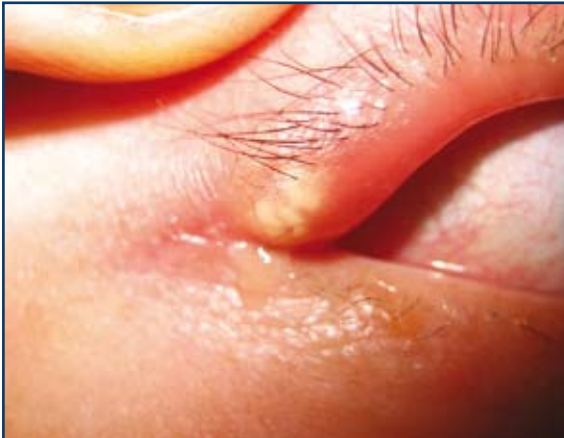


Fig 2 Stye

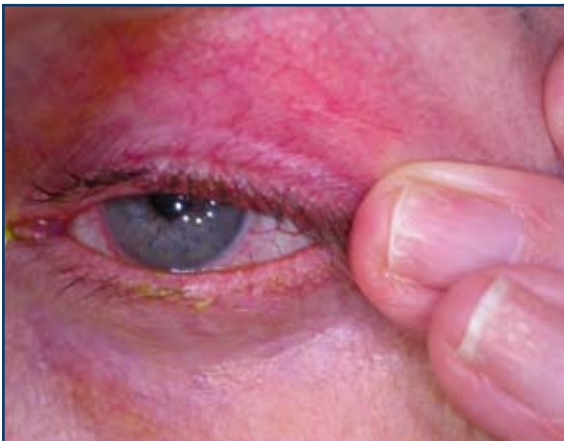

Fig 3 Blepharitis

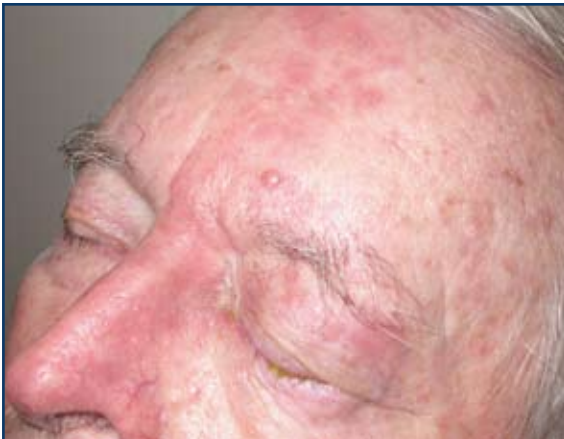

Fig 4 Herpes Zoster

## 2. Eyelid abnormal

ATS CATEGORY 4 (START TREATMENT WITHIN 60 MINS)

### A. Chalazion (Fig 1), Stye (Fig 2)

- Localised eyelid inflammation with minimal ocular involvement.
- Treat with antibiotic ointment if indicated.
- If acutely inflamed treat with oral antibiotics and warm compresses.
- Routine ophthalmological referral.

### B. Acute blepharitis (Fig 3):

- Localised eyelid inflammation with minimal ocular involvement (similar to chalazion without cyst formation).
- Treat with antibiotic ointment if indicated.
- Routine ophthalmological referral.

### C. Herpes Zoster (Fig 4)

- Vesicular rash.
- Treat with oral antivirals within 72 hours of appearance of the rash.



**Refer to ophthalmologist if vision is affected or if eye is red.**

### 3. Diffuse conjunctival injection

ATS CATEGORY 5 (START TREATMENT WITHIN 120 MINS)

#### A. Viral conjunctivitis (Fig 1):

- Contact history with recent eye or upper respiratory tract infection symptoms (especially children).
- Burning sensation and watery discharge (different from purulent exudate in bacterial infections).
- Classically begins in one eye with rapid spread to the other.

Highly contagious. Observe Standard Precautions, (see p15). Fact Sheet for Epidemic Keratoconjunctivitis (EKC) (see Appendix II), RANZCO Infection Control Guidelines (see Appendix III) & details of NSW Infection Control Policy (see p56).

#### • Treatment:

1. Wash hands and use separate tissues to avoid infection of the other eye or others.
  2. Cool compresses.
  3. Lubricants (without preservative) q 2 hrly.
  4. Antibiotic drops if indicated.
  5. Never steroids!
- Resolution may take weeks

#### When to refer?

- Photophobia and marked decrease in visual acuity.
- Severe disease requiring steroids.
  - Lasting longer than 3 weeks.
    - Chronic conjunctivitis.
    - Consider other diagnosis.
    - Chlamydia.
  - Work cover issues.
    - Employer responsibilities.
    - Long term scarring of eye lids.

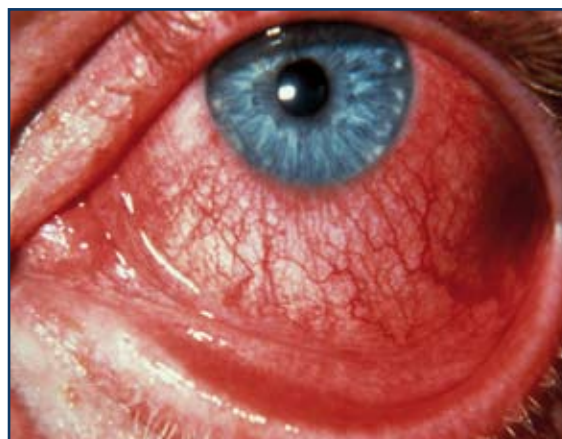

Fig 1 Viral conjunctivitis

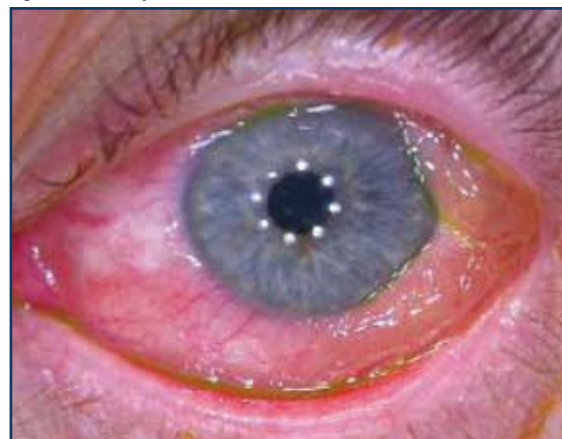


Fig 2 Allergic conjunctivitis

#### B. Allergic conjunctivitis (Fig 2)

- Itch!!!
- Atopic history: asthma, eczema, conjunctivitis.
- Treatment:
  1. Cool compresses.
  2. Lubricant (without preservative).
- Routine referral for all children or if symptoms are not well controlled.

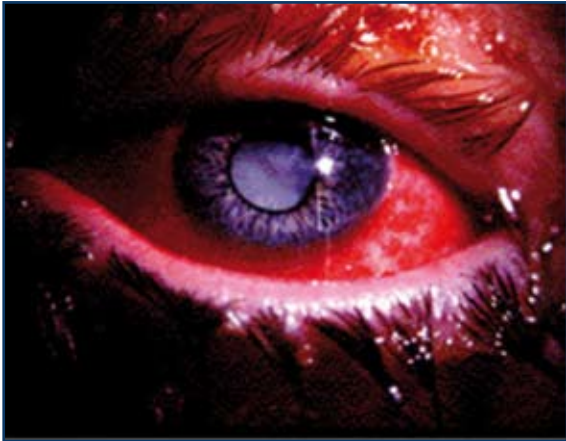

Fig 1 Bacterial conjunctivitis

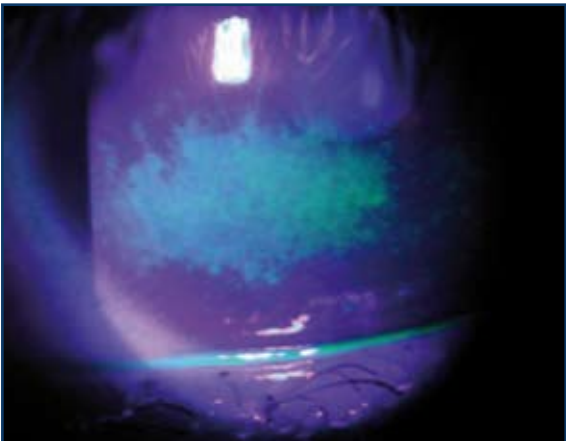


Fig 2 Dry eyes

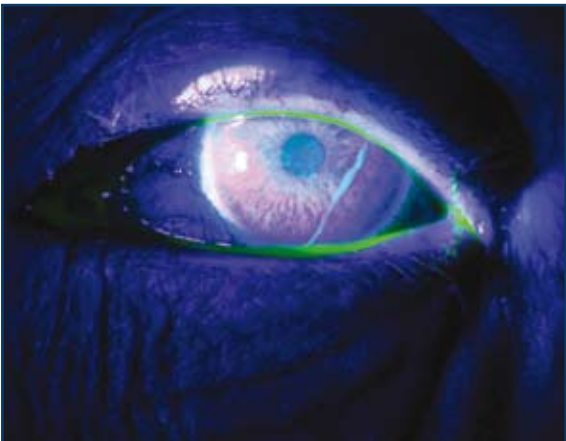

Fig 3 Dry eyes

**C. Bacterial conjunctivitis: (Fig 1)**

- Tender inflamed conjunctiva with purulent discharge from the conjunctival sac. This condition is often bilateral.
- No corneal or anterior chamber involvement.
- Systemically well. Common in the elderly and children.

• **Treatment:**

1. Regular hygiene to minimise secretion buildup.
2. Wash hands and use separate tissues to avoid infection of the other eye or others.
3. QID topical antibiotics for 5 days.

 **When to refer?**

- If vision is affected.
- If condition does not improve with treatment after 2 days or worsens.
- If condition persists after treatment for 5 days.

**D. Dry Eyes: (Figs 2 & 3)**

- A common chronic ocular condition that is often caused by or coexists with other ocular diseases.
- Symptoms often worsen in the evening.

• **Treatment:**

1. Good relief with lubricants (see p26) with consideration for preservative-free if more than 4 times and gels or ointments prior sleep.
2. Routine referral.



## 4. Acute angle closure glaucoma

ATS CATEGORY 3 (START TREATMENT WITHIN 30 MINS)

- Cornea usually has hazy appearance (see Fig 1).
- Anterior chamber is shallow with irregular semidilated pupil.
- The affected eye is very tender and tense to palpation.
- Systemic symptoms include **headache, nausea and vomiting.**


 **Urgent referral to ophthalmologist.**

## 5. Ciliary injection/scleral involvement

ATS CATEGORY 4 (START TREATMENT WITHIN 60 MINS)

**Scleritis (Fig 2).**

- Vision may be impaired.
- Sclera is thickened and discoloured. The globe is tender to palpation.
- Associated history of life-threatening vascular or connective tissue disease – may require appropriate physician consult (NB look for medications involving systemic steroids, NSAIDs, antimetabolites).

 **Urgent referral to ophthalmologist.**

## 6. Anterior chamber involvement


ATS CATEGORY 4 (START TREATMENT WITHIN 60 MINS)

**Acute Anterior Uveitis (Iritis)**

- Pain, photophobia, and red eye.
- Anterior chamber appears cloudy from cells and flare.

**Hypopyon (Fig 3)**

Visible accumulation of white cells inferiorly seen in severe uveitis.

 **Urgent referral** for investigation of infection, inflammation or ocular malignancy.

**Hyphaema (Fig 4)**

- Usually trauma related but consider non-accidental injury in children and blood dyscrasias.
- Bed rest, eye pad.


 **Urgent assessment by ophthalmologist.**

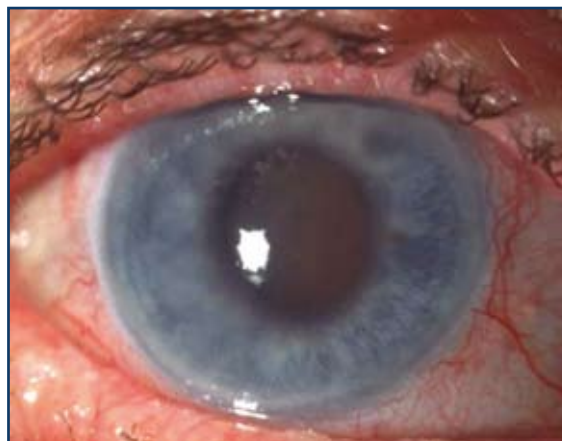

Fig 1 Acute angle closure glaucoma

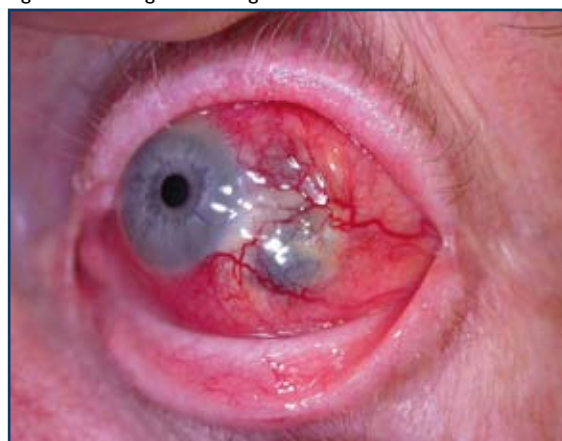

Fig 2 Scleritis

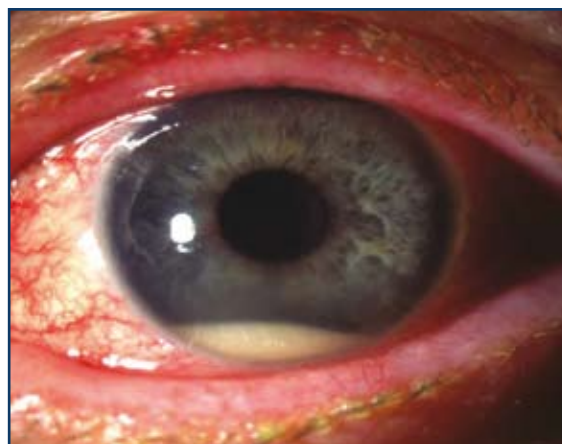

Fig 3 Hypopyon

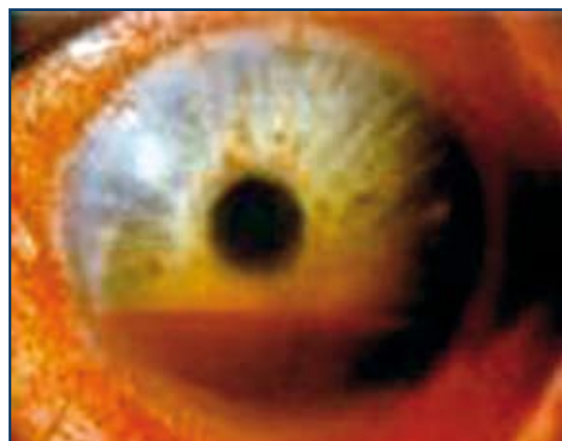
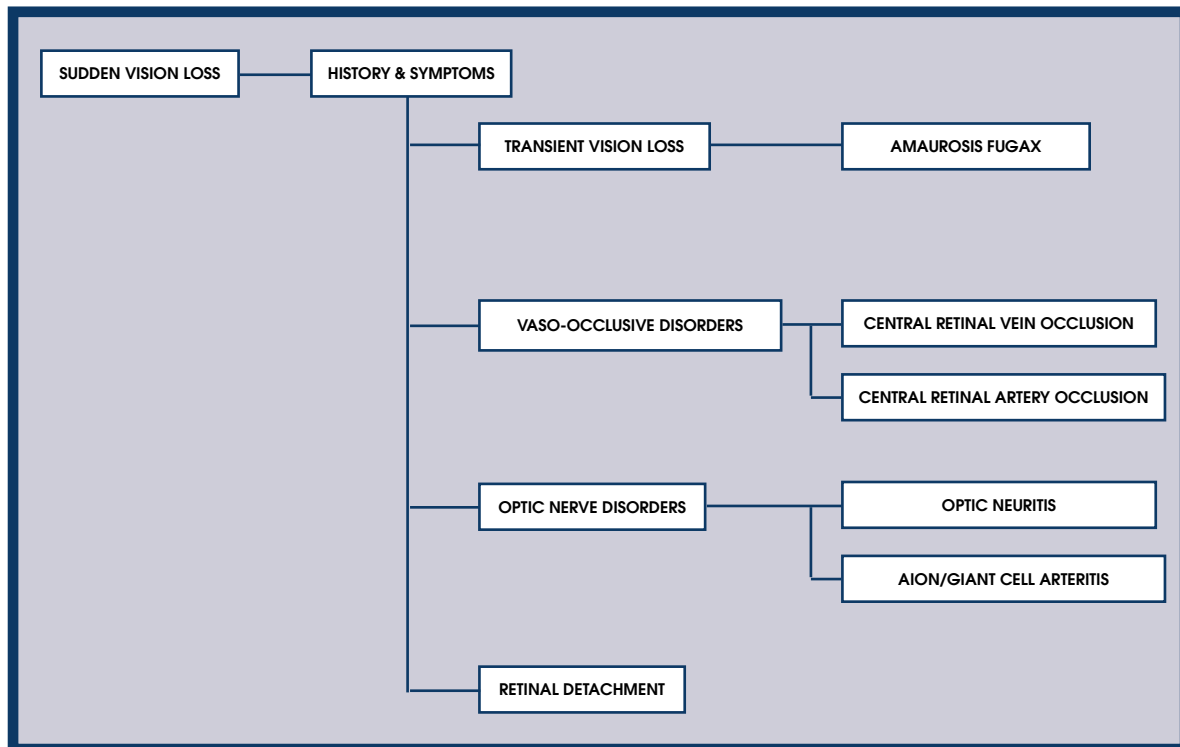


Fig 4 Hyphaema

## Acute visual disturbance/Sudden loss of vision<sup>1</sup>



## I. Transient Ischaemic Attack (Amaurosis Fugax)

ATS CATEGORY 3 (START TREATMENT WITHIN 30 MINS)

### Symptoms

- Monocular visual loss that usually lasts seconds to minutes, but may last 1-2 hours. Vision returns to normal.

### Signs

- Essentially normal fundus exam (an embolus within a retinal arteriole is only occasionally seen (see Fig 1).
- Other neurological signs associated with ischemia of cerebral hemispheres.

### Investigation

As per protocol but usually includes assessment of cardiovascular risk factors:

- Blood count/electrolytes/lipids/fasting blood sugar.
- Thrombophilia screen.
- Echocardiogram.
- Carotid doppler studies.

### Management


- Commence aspirin.
-  Referral to neurology/cardiology or vascular surgery as appropriate. Patients with recurrent episodes of amaurosis fugax require immediate diagnostic and therapeutic intervention.

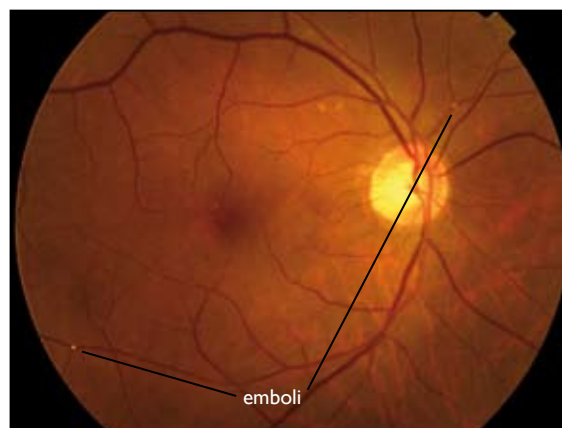

Fig 1 Transient ischaemic attack with visible emboli

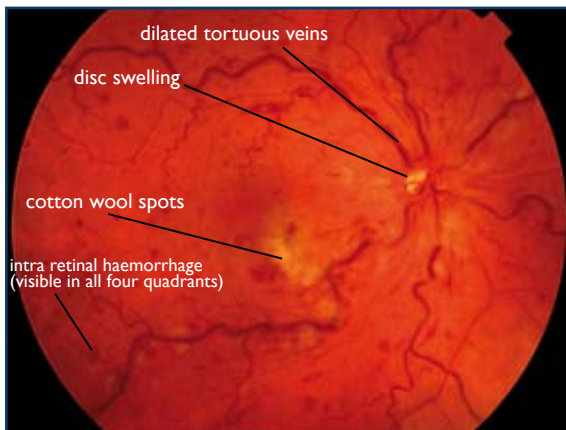


Fig 1 Non ischaemic CRVO (less severe)

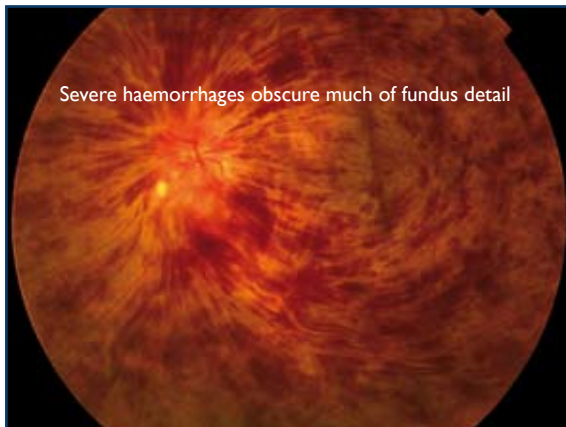

Fig 2 Ischaemic CRVO (more severe)

## 2. Central Retinal Vein Occlusion (CRVO) (Figs 1 & 2)

ATS CATEGORY 3 (START TREATMENT WITHIN 30 MINS)

### Symptoms

- Sudden and painless loss of vision.

### Predisposing factors

- Increasing age.
- Hypertension.
- Diabetes.

### Signs

- Visual acuity and presence of a Relative Afferent Pupillary Defect (RAPD) are variable depending on the severity and duration since the onset of the condition.
- Abnormal red reflex.
- Fundus examination shows large areas of haemorrhage.

### Investigation and Management

- Screen for diabetes and hypertension.
- Routine referral for an ophthalmological opinion.

### 3. Central Retinal Artery Occlusion

(Fig 1)

ATS CATEGORY 3 (START TREATMENT WITHIN 30 MINS)

#### Symptoms

- Sudden and painless loss of vision.

#### Signs

- Visual acuity < 6/60.
- Relative Afferent Pupillary Defect (RAPD) marked (see p23, *Pupil Examination*).
- Fundus examination: pale retinal (abnormal and asymmetrical red reflex), Arteriolar and venular narrowing.

#### Investigation and Management

- 🚩 Urgent ESR and CRP to exclude Giant Cell Arteritis.
- 🚩 **Urgent referral to ophthalmologist whether any immediate treatment is possible.**
- TIA workup as per page 49.

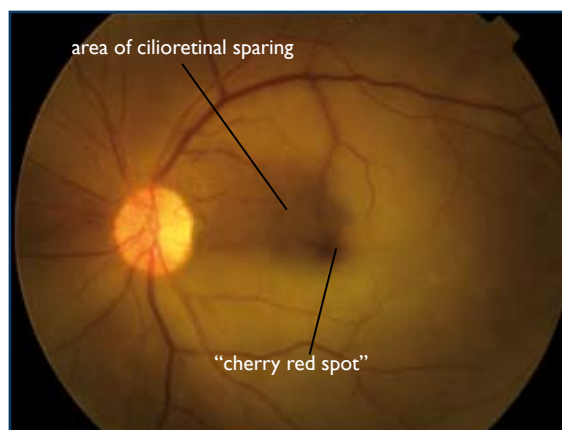

Fig 1 Central Retinal Artery Occlusion

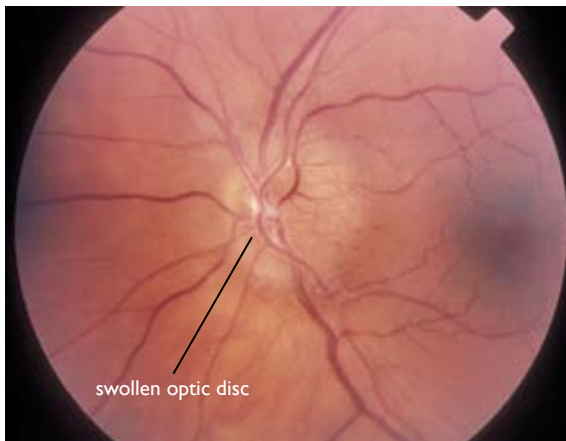


Fig 1 Optic neuritis

## 4. Optic neuritis (Fig 1)

ATS CATEGORY 3 (START TREATMENT WITHIN 30 MINS)

### Symptoms


- Painless loss of vision over hours to days. Vision loss can be subtle or profound.
- Reduced visual acuity, colour and contrast vision.
- Usually unilateral, but may rarely be bilateral.
- More often affecting females aged between 18-45.
- Orbital pain usually associated with eye movement.
- May have other focal neurological symptoms.


### Signs

- Relative Afferent Pupillary Defect (RAPD)
- Decreased visual acuity.
- Decreased colour vision.
- +/- Patchy visual field defects.
- +/- Swollen optic disc.
- May have other focal neurological signs.

### Investigation and Management

- Complete ophthalmic and neurological examination.
- Blood count/Erythrocyte Sedimentation Rate (ESR).

 **Urgent referral to ophthalmologist** may be indicated for further MRI investigation and intravenous steroid treatment may be required.

 **There are NO indications for oral cortico-steroids as initial treatment.**

## 5. Arteritic Ischaemic Optic Neuropathy (AION)/Giant Cell Arteritis (Fig 1)

ATS CATEGORY 3 (START TREATMENT WITHIN 30 MINS)

- Transient visual loss may precede an ischaemic optic neuropathy or central retinal artery occlusion.
- Typically affects patients greater than 50 years.
- Raised Erythrocyte Sedimentation Rate (ESR) and C-Reactive Protein (CRP).

### Symptoms

- Temporal headache.
- Scalp tenderness.
- Jaw claudication.
- Fever and night sweats.
- Generalised muscle pain and weakness.

### Signs

May include any or all of the following:

- Afferent pupillary defect.
- Poor visual acuity, often VA count fingers.
- Palpable and tender non-pulsatile temporal artery.
- Swollen optic disc.

### Investigation and Management

- Immediate ESR/CRP (NB not always raised in GCA).

**Referral to ophthalmologist** on the necessity of steroid treatment and/or temporal artery biopsy. Screen patient for risk factors that may contraindicate or complicate treatment with high dose steroids such as peptic ulcer disease, gastric bleeding, uncontrolled diabetes, and tuberculosis.

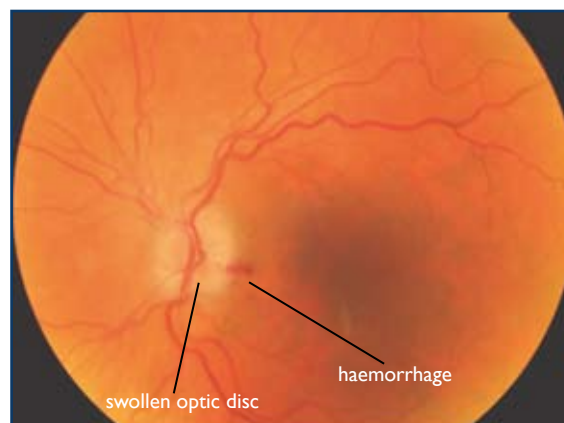


Fig 1 AION due to Giant Cell Arteritis

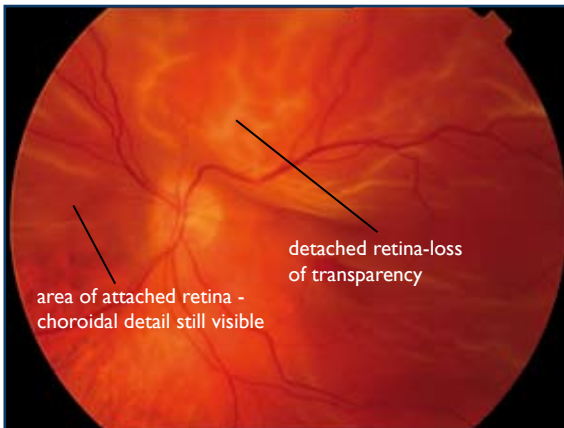


Fig 1 Retinal detachment (macula off)

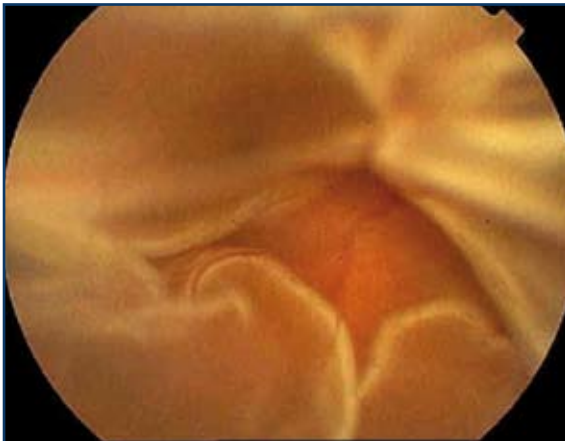


Fig 2 Retinal detachment

## 6. Retinal Detachment (Figs 1 & 2)

ATS CATEGORY 3 (START TREATMENT WITHIN 30 MINS)

- Separation of sensory retina from the retinal pigment epithelium.
- The most common aetiology of this condition is a predisposing retinal defect.

### Symptoms

- Painless loss of vision. The patient may have encountered a recent history of increased number of visual floaters and/or visual flashes. There may be a “dark shadow” in the vision of the affected eye.
- Patients who are myopic (short sighted) or with previous trauma history have a higher risk of this condition.

### Signs

- Reduced visual acuity (if the macula is detached).
- Abnormal red reflex - A mobile detached retina may be visible on ophthalmoscopy.

### Investigation and Treatment

- Minimise activity - bed rest with toilet privileges.



**Urgent opinion from an ophthalmologist.**

- May require workup for surgery under general anaesthesia.



# Chapter Four

## Emergency Contact Information & Glossary

---

## ***Emergency contacts & further information***

**Sydney Hospital & Sydney Eye Hospital: (02) 9382 7111**

**NSW Poisons Information Centre: 131126**

**Current NSW Infection Control Policy:**  
[http://www.health.nsw.gov.au/policies/PD/2005/PD2005\\_247.html](http://www.health.nsw.gov.au/policies/PD/2005/PD2005_247.html)

**Epidemic Keratoconjunctivitis (EKC) Fact Sheet:** [http://www.health.nsw.gov.au/infect/pdf/e\\_keratoconjunctivitis.pdf](http://www.health.nsw.gov.au/infect/pdf/e_keratoconjunctivitis.pdf)

---

## Glossary

### AC/Anterior chamber

Anatomy: space between Iris and corneal endothelium.

### ANISOCORIA

Anatomic defect: different sized pupils.

### AVULSION

Pathologic condition: Tearing or wrenching away of a part eg optic nerve from the globe.

### CHEMOSIS

Pathologic condition: oedema of the conjunctiva.

### CICATRIX

Anatomic defect: A scar formed by connective tissue which replaces a localised tissue loss. May be initially red/purple becoming white and glossy with time. Eg Keloid scar.

### CONTUSION

Injury: A bruise or injury without break in the skin/cover.

### DIPLOPIA

Symptom/Functional defect: double vision.

### ECCHYMOSIS

Pathologic condition: Bruising.

### EROSIONS

Pathologic condition: Destruction/eating away/loss of corneal epithelium.

### FORNIX/FORNICES (pl)

Potential space between the ocular surface and the conjunctival surface of the eyelid.

### HYPERAEMIA

Clinical sign: Increased blood flow. Congestion of conjunctival blood vessels.

### IRIDOSCHISIS

Pathologic condition: Splitting of the iris structure formation of a hole (like a coloboma) in the iris.

### ISCHAEMIA

Pathologic condition: Localised anaemia caused by arterial constriction.

### PALPEBRAL FISSURE

Space between the upper and lower eyelid edges.

### POSTERIOR SYNECHIAE

Pathologic condition: Adhesion of iris to cornea/ lens.

### PROLAPSE

Pathologic condition: Slip/falling down of a part e.g. iris may fall through a wound.

### RED REFLEX

The red reflection seen through the pupil from the retina. This is similar to “red eye” in flash photography. The reflex is missing if there is an opacity at the cornea, anterior chamber, lens and vitreous or if the retina is detached.

### SYMBLEPHARON

Pathologic condition: Adhesion of the eyelid conjunctiva to the conjunctiva of the globe.

### TRICHIASIS

A condition (such as entropion) resulting in the eyelashes to rub against the cornea causing discomfort and with the potential for ulceration.

### ULCERATION

Pathologic condition: Loss of substance in skin/ mucous tissue due to gradual necrosis of the tissue.

## Appendix I - Australasian Triage Scale: Descriptors for Categories <sup>1,2</sup>

ATS CATEGORY	RESPONSE	DESCRIPTION OF CATEGORY	CLINICAL DESCRIPTORS (Indicative Only)
Category 1	Immediate simultaneous assessment and treatment	<b>Immediately Life-Threatening</b> Conditions that are threats to life (or imminent risk of deterioration) and require immediate aggressive intervention.	Cardiac arrest Respiratory arrest Immediate risk to airway - impending arrest Respiratory rate <10/min Extreme respiratory distress BP < 80 (adult) or severely shocked child/infant Unresponsive or responds to pain only (GCS < 9) Ongoing/prolonged seizure IV overdose and unresponsive or hypoventilation Severe behavioural disorder with immediate threat of dangerous violence
Category 2	Assessment and treatment within 10 minutes (assessment and treatment often simultaneous)	<b>Imminently life-threatening</b> The patient's condition is serious enough or deteriorating so rapidly that there is the potential of threat to life, or organ system failure, if not treated within ten minutes of arrival <b>or</b> <b>Important time-critical treatment</b> The potential for time-critical treatment (e.g. thrombolysis, antidote) to make a significant effect on clinical outcome depends on treatment commencing within a few minutes of the patient's arrival in the ED <b>or</b> <b>Very severe pain</b> Humane practice mandates the relief of very severe pain or distress within 10 minutes	Airway risk - severe stridor or drooling with distress Severe respiratory distress Circulatory compromise Clammy or mottled skin, poor perfusion HR < 50 or > 150 (adult) Hypotension with haemodynamic effects Severe blood loss Chest pain of likely cardiac nature Very severe pain - any cause BSL < 2 mmol/l Drowsy, decreased responsiveness any cause (GCS < 13) Acute hemiparesis/dysphasia Fever with signs of lethargy (any age) Acid or alkali splash to eye - requiring irrigation Major multi trauma (requiring rapid organised team response) Severe localised trauma - major fracture, amputation High-risk history: Significant sedative or other toxic ingestion Significant/dangerous envenomation Severe pain suggesting PE, AAA or ectopic pregnancy Behavioural/Psychiatric: violent or aggressive immediate threat to self or others requires or has required restraint severe agitation or aggression

continued...

<sup>1</sup> G24 Guidelines for the implementation of the Australasian Triage Scale in Emergency Departments. Revised 05 August 2005

<sup>2</sup> Reproduced with permission of the Australasian College for Emergency Medicine (NSW Branch).

Category 3	Assessment and treatment start within 30 mins	<p><b>Potentially Life-Threatening</b> The patient's condition may progress to life or limb threatening, or may lead to significant morbidity, if assessment and treatment are not commenced within thirty minutes of arrival</p> <p><b>or</b></p> <p><b>Situational Urgency</b> There is potential for adverse outcome if time-critical treatment is not commenced within thirty minutes</p> <p><b>or</b></p> <p>Humane practice mandates the relief of severe discomfort or distress within thirty minutes</p>	<p>Severe hypertension Moderately severe blood loss - any cause Moderate shortness of breath SAO<sub>2</sub> 90 - 95% BSL &gt;16 mmol/l Seizure (now alert) Any fever if immunosuppressed eg oncology patient, steroid Rx Persistent vomiting Dehydration Head injury with short LOC- now alert Moderately severe pain - any cause - requiring analgesia Chest pain likely non-cardiac and mod severity Abdominal pain without high risk features - mod severe or patient age &gt;65 years Moderate limb injury - deformity, severe laceration, crush Limb - altered sensation, acutely absent pulse Trauma - high-risk history with no other high-risk features Stable neonate Child at risk Behavioural/Psychiatric: very distressed, risk of self-harm acutely psychotic or thought disordered situational crisis, deliberate self harm agitated / withdrawn potentially aggressive</p>
Category 4	Assessment and treatment start within 60 mins	<p><b>Potentially serious</b> The patient's condition may deteriorate, or adverse outcome may result, if assessment and treatment is not commenced within one hour of arrival in ED. Symptoms moderate or prolonged.</p> <p><b>or</b></p> <p><b>Situational Urgency</b> There is potential for adverse outcome if time-critical treatment is not commenced within hour</p> <p><b>or</b></p> <p><b>Significant complexity or Severity</b> Likely to require complex work-up and consultation and/or inpatient management</p> <p><b>or</b></p> <p>Humane practice mandates the relief of discomfort or distress within one hour</p>	<p>Mild haemorrhage Foreign body aspiration, no respiratory distress Chest injury without rib pain or respiratory distress Difficulty swallowing, no respiratory distress Minor head injury, no loss of consciousness Moderate pain, some risk features Vomiting or diarrhoea without dehydration Eye inflammation or foreign body - normal vision Minor limb trauma - sprained ankle, possible fracture, uncomplicated laceration requiring investigation or intervention - Normal vital signs, low/moderate pain Tight cast, no neurovascular impairment Swollen "hot" joint</p> <p>Non-specific abdominal pain Behavioural/Psychiatric: Semi-urgent mental health problem Under observation and/or no immediate risk to self or others</p>
Category 5	Assessment and treatment start within 120 minutes	<p><b>Less Urgent</b> The patient's condition is chronic or minor enough that symptoms or clinical outcome will not be significantly affected if assessment and treatment are delayed up to two hours from arrival</p> <p><b>or</b></p> <p><b>Clinico-administrative problems</b> results review, medical certificates, prescriptions only</p>	<p>Minimal pain with no high risk features Low-risk history and now asymptomatic Minor symptoms of existing stable illness Minor symptoms of low-risk conditions Minor wounds - small abrasions, minor lacerations (not requiring sutures) Scheduled revisit eg wound review, complex dressings Immunisation only Behavioural/Psychiatric: Known patient with chronic symptoms Social crisis, clinically well patient</p>

## Appendix II - Fact Sheet for Epidemic Keratoconjunctivitis (EKC)



### Communicable Diseases Factsheet

# Epidemic Keratoconjunctivitis

*Epidemic keratoconjunctivitis is a highly contagious infection of the front surfaces of the eye. There is no specific treatment, and symptoms will resolve in around two weeks. Hygienic practices are important to stop the infection spreading to others.*

**Issued:** 20 December 2006

### What is epidemic keratoconjunctivitis?

Epidemic keratoconjunctivitis (also sometimes referred to as viral keratoconjunctivitis) is highly contagious and symptoms can last up to two weeks or more. This viral infection is often caused by an Adenovirus and there is no specific treatment. Bacteria, other viruses, allergies or chemical irritation can also cause types of conjunctivitis.

### What are the symptoms?

The symptoms of epidemic keratoconjunctivitis can commence in one or both eyes and include:

- Redness, irritation and itchiness of the eyes ("pink eye")
- Swelling of the eyelids
- Sensitivity to light (photophobia)
- Clear or yellow discharge that may make the eyelids stick together when you wake in the morning
- Blurred vision
- Eye pain

Occasionally, people may also get:

- Fever
- Headache
- Extreme tiredness
- Swollen lymph nodes

### How do you get epidemic keratoconjunctivitis?

- People get epidemic keratoconjunctivitis by coming into contact with tears or discharge from the eyes of an infected person and then touching their own eyes. This can happen by touching the hands of someone with the infection, or by touching contaminated surfaces or objects.
- Usually the symptoms develop between 5 days and two weeks after exposure to an infected person or surface, however this can take longer.
- People are thought to be infectious from a day or two prior to the onset of symptoms until around 2 weeks after symptoms develop.

### Who is at risk?

Anyone can get epidemic keratoconjunctivitis. It is easily spread between people.

### How is it prevented?

Epidemic keratoconjunctivitis is a **highly contagious** disease and children should stay home from school until symptoms have resolved or until cleared by a doctor, whichever is earlier. It is usually OK to go to work, but follow the infection control measures outlined below. However, health care workers should be clear of infection prior to returning to work.

If you have epidemic keratoconjunctivitis:

- Avoid touching your eyes whenever possible. If you do touch your eyes, wash your hands thoroughly with soap and running water

- Avoid touching other people unless your hands are freshly washed
- Throw away or carefully wash items (in hot water and detergent) that touch your eyes
- Do not share eye makeup or other items used on the eyes (i.e. towels, tissues, eye drops, eye medications)
- Use a separate towel and face cloth for each member of the household
- Cover your mouth and nose when coughing or sneezing
- Use disposable tissues to blow your nose, sneeze or cough
- If you visit another doctor or clinic, make sure you tell them that you have or have recently had epidemic keratoconjunctivitis so they can implement measures to prevent spread of infection.

### How is it diagnosed?

Epidemic keratoconjunctivitis is diagnosed by the signs and symptoms outlined above. Your doctor may also take a swab of your eyes to identify the responsible virus. A swab takes several days to return a result.

### How is it treated?

There is no treatment available for epidemic keratoconjunctivitis, and it will usually go away by itself in around two weeks (this can range from one to six weeks). Paracetamol and cold showers have been found to be helpful for relieving symptoms. Specific treatment is available for the other forms of conjunctivitis (bacterial, allergic).

### What is the public health response?

Epidemic keratoconjunctivitis is not a notifiable disease in NSW. However public health units can provide advice on the control of outbreaks.

#### Further information – Public Health Units in NSW

For more information please contact your doctor, local public health unit or community health centre – look under *NSW Government* at the front of the White Pages.

Metropolitan Areas		Rural Areas			
<b>Northern Sydney / Central Coast</b>	Hornsby	02 9477 9400	<b>Greater Southern</b>	Goulburn	02 4824 1837
	Gosford	02 4349 4845		Albury	02 6021 4799
<b>South Eastern Sydney / Illawarra</b>	Randwick	02 9382 8333	<b>Greater Western</b>	Broken Hill	08 8080 1499
	Wollongong	02 4221 6700		Dubbo	02 6841 5569
<b>Sydney South West</b>	Camperdown	02 9515 9420		Bathurst	02 6339 5601
	Liverpool	02 9828 5944	<b>Hunter / New England</b>	Newcastle	02 4924 6477
<b>Sydney West</b>	Penrith	02 4734 2022		Tamworth	02 6767 8630
	Parramatta	02 9840 3603	<b>North Coast</b>	Port Macquarie	02 6588 2750
<b>Justice Health Service</b>	Matraville	02 9311 2707		Lismore	02 6620 7500
<b>NSW Department of Health</b>	Nth Sydney	02 9391 9000			
<b>NSW Health website</b>	www.health.nsw.gov.au				© NSW Department of Health 2006

## Appendix III - Infection Control Guidelines

### The Royal Australian and New Zealand College of Ophthalmologists (RANZCO)

#### INFECTION CONTROL GUIDELINES TO PREVENT NOSOCOMIAL EPIDEMIC KERATOCONJUNCTIVITIS (EKC)

EKC is usually caused by adenovirus. Adenovirus is readily transmissible by infected secretions, and can persist on surfaces and fomites for several weeks. Alcohol is ineffective against adenovirus, however it is a useful disinfectant of other organisms and can be used for routine disinfection of tonometer prisms between non-EKC patients.

To minimize the risk of EKC outbreaks, eye practices should:

1. Practise hand hygiene between each patient, as per infection control standards promulgated in each jurisdiction. Ensure that good hand hygiene facilities are readily accessible for all staff and that hands are cleaned between each consultation.
2. Clean all equipment surfaces with a neutral detergent between at risk patients. This should be done by squirting the detergent onto a clean cloth and wiping down the equipment surface (ie not spraying).
3. Train reception and front line staff to ensure that persons presenting with “red eye” not undergo routine preliminary examination protocols without first checking with the clinician. Where possible, such patients should be isolated from other staff and patients.
4. Use single-dose vials of anaesthetic and dilating drops, discarded after each patient. Where single dose vials are unavailable, the use of individual fluorescein strips to instill anaesthetic or dilating solutions to each patient is acceptable. At all times clinicians and staff must ensure the dilating and anaesthetic bottles do not contact patients or their own hands. If contact occurs the bottle must be discarded.
5. Use tonometry appropriately for each patient. Consider the option of single use tonometer prisms that can be discarded after each patient.
6. If reusable tonometer prisms are utilised in the practice, have sufficient prisms for the patient load. Inspect the tonometer prisms for damage before use and discard any damaged prisms.
7. Ensure that reusable tonometer prisms are disinfected between each patient by wiping with an isopropyl alcohol swab and allowing to air dry before use.
8. Any tonometer prism used on a patient with suspected conjunctivitis must be removed from further use until decontaminated by the following procedure. All tonometer prisms should also be decontaminated by this method at the end of each clinic session:
  - Don personal protective equipment (minimum: gloves and eye protection from splashing).
  - Wash under running water to remove any visible debris.
  - Dry with clean tissue, wipe with 70% isopropyl alcohol swab.
  - Allow to air dry.
  - Soak for 10 minutes in 0.05% sodium hypochlorite solution
  - Thoroughly rinse and store dry for future use.
  - Discard the sodium hypochlorite solution each day and wash the soapy container in hot soapy water then store dry between each use.

Ensure that all practice staff are aware of these guidelines, and regularly review compliance.

September 2006

These guidelines were developed by Sydney Hospital/Sydney Eye Hospital, adopted by the NSW Department of Health and adapted for national use by RANZCO.

G 00/55





