

BELS (Basic echo in life  
support)

# What is the purpose of echo in the ED?

- A basic, focused echo to answer specific questions:
  - Is the heart beating? (e.g. in cardiac arrest)
  - Is there a pericardial effusion or signs of tamponade?
  - Is the LV hypodynamic suggesting LV failure? (e.g. in CCF, or drug overdose)
  - Is the LV hyperdynamic suggesting hypovolaemia? (e.g. In sepsis, or shock)
  - Is the RV grossly dilated suggesting right heart strain (e.g in PE)
  - Is the IVC small and collapsing (suggesting underfilling) or wide and fixed (suggesting overload)

# What is the purpose of this module?

- This is a simple overview of how to perform a basic echo, designed as a refresher for people who have already done a certified course, or to help people understand what they're looking at when reviewing cases involving ultrasound images of the heart
  - It is not designed as a standalone course that would enable you to practice independently
- 
- All the drawings are licenced under creative commons, and the ultrasound images and labels are all copyright of T Withers

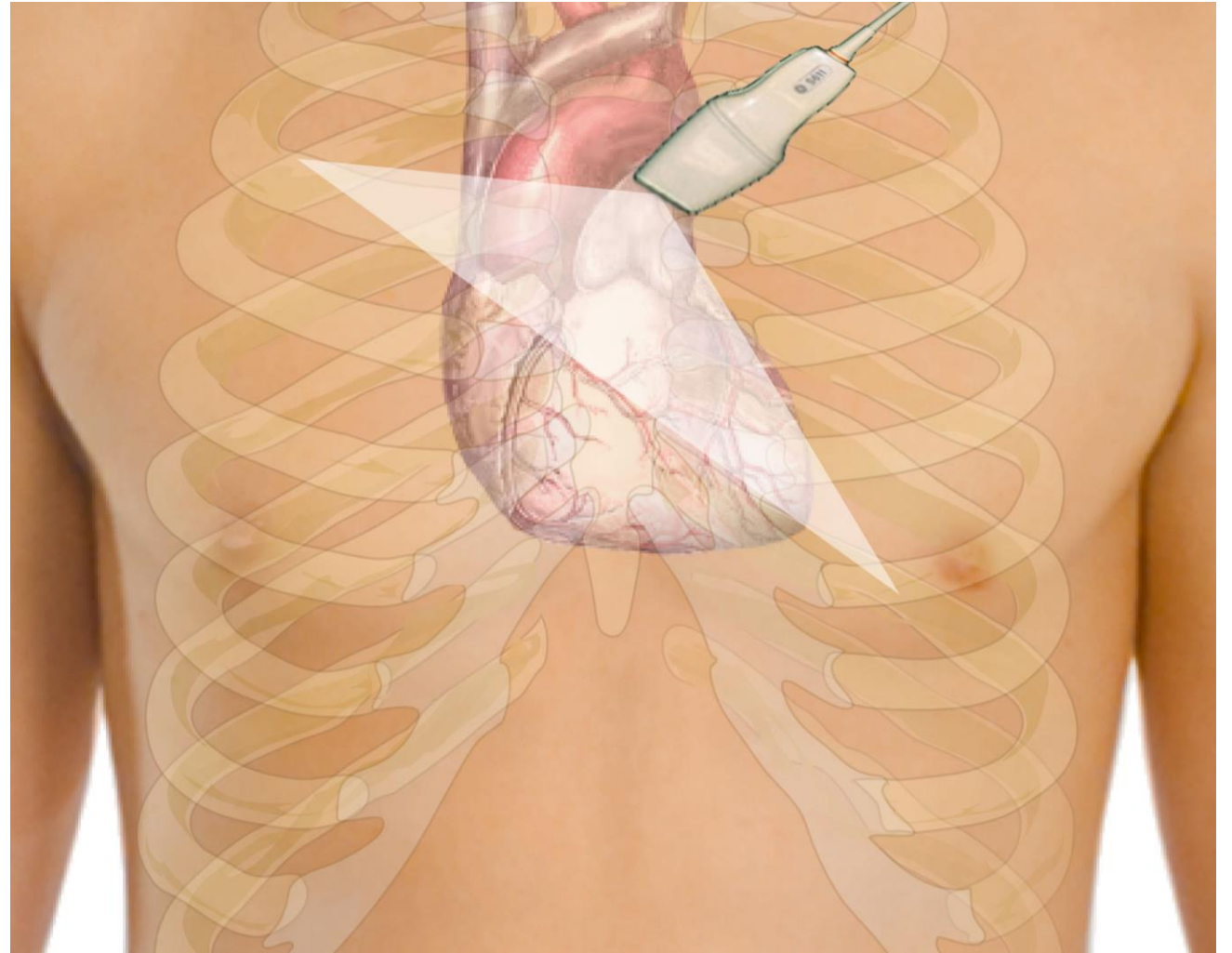
Parasternal long axis

# Probe position

Start with the probe in the second intercostal space right next to the sternum

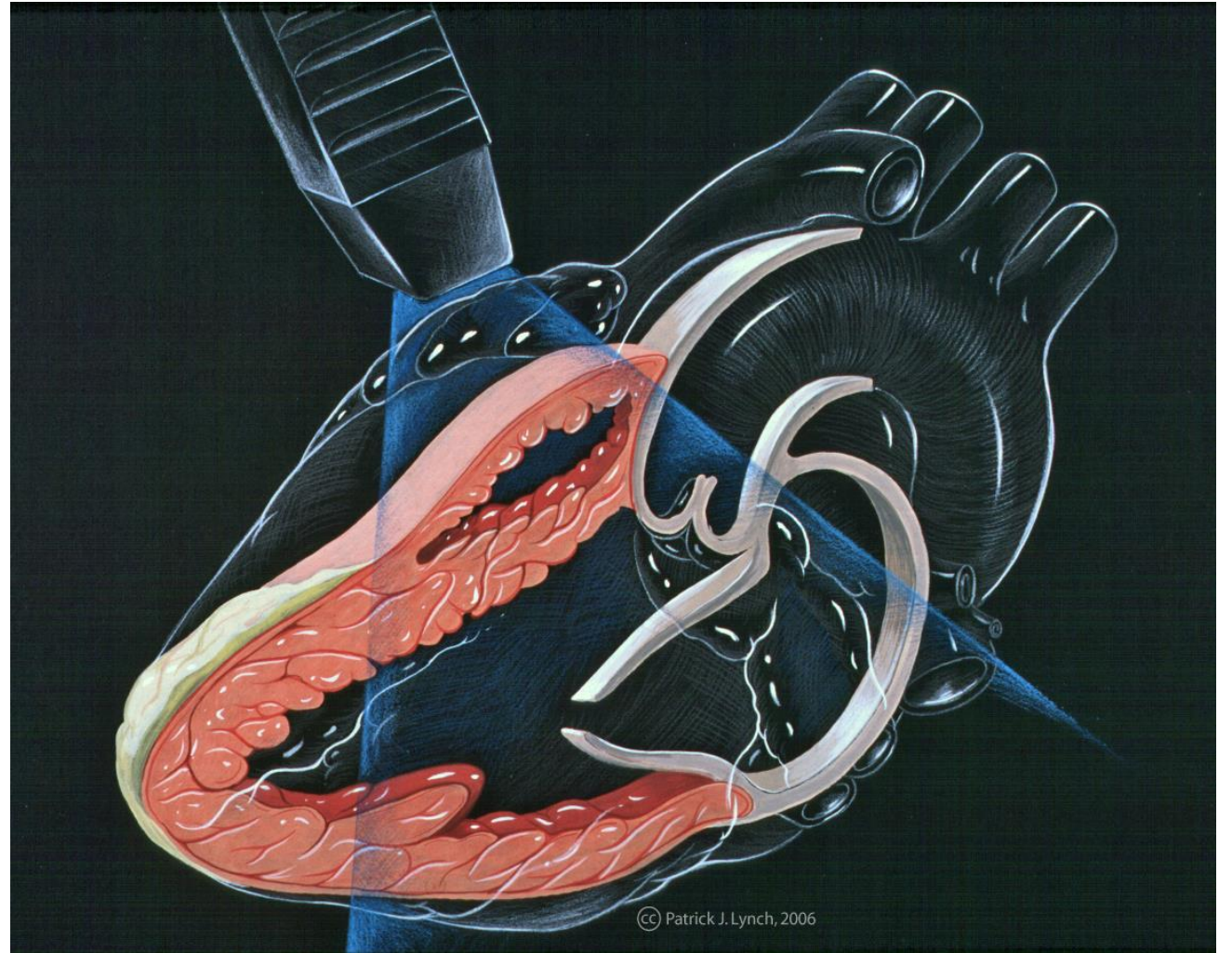
The probe marker is at 11 o' clock (pointing roughly at the patient's right shoulder)

If you cannot see anything, slowly slide the probe down into the next space until the image comes into view



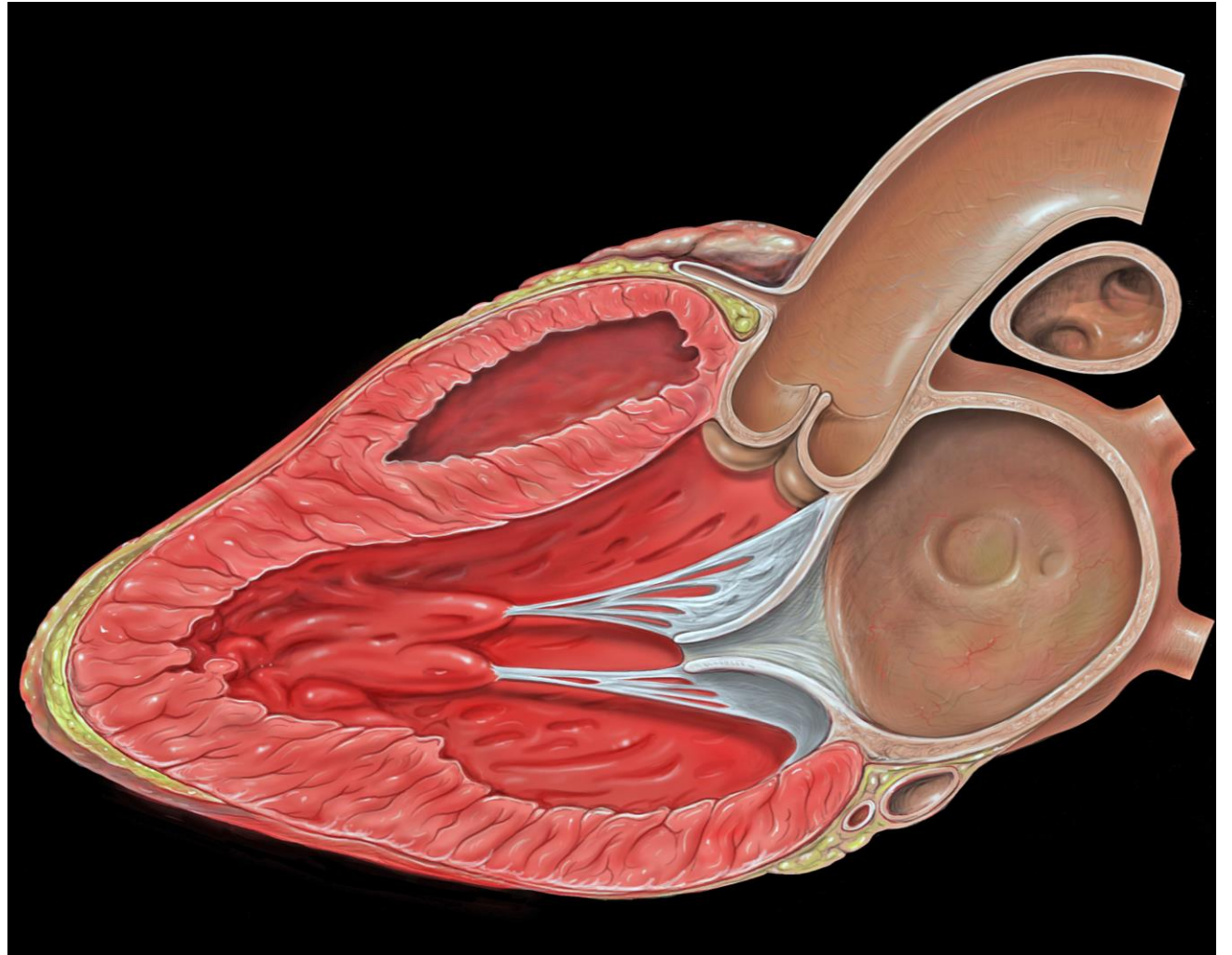
# Cross section

This image shows the cross section of the heart created by the beam



# Crosssection of the PLAX

This image shows the 2 dimensional slice we  
are trying to get



# PLAX image

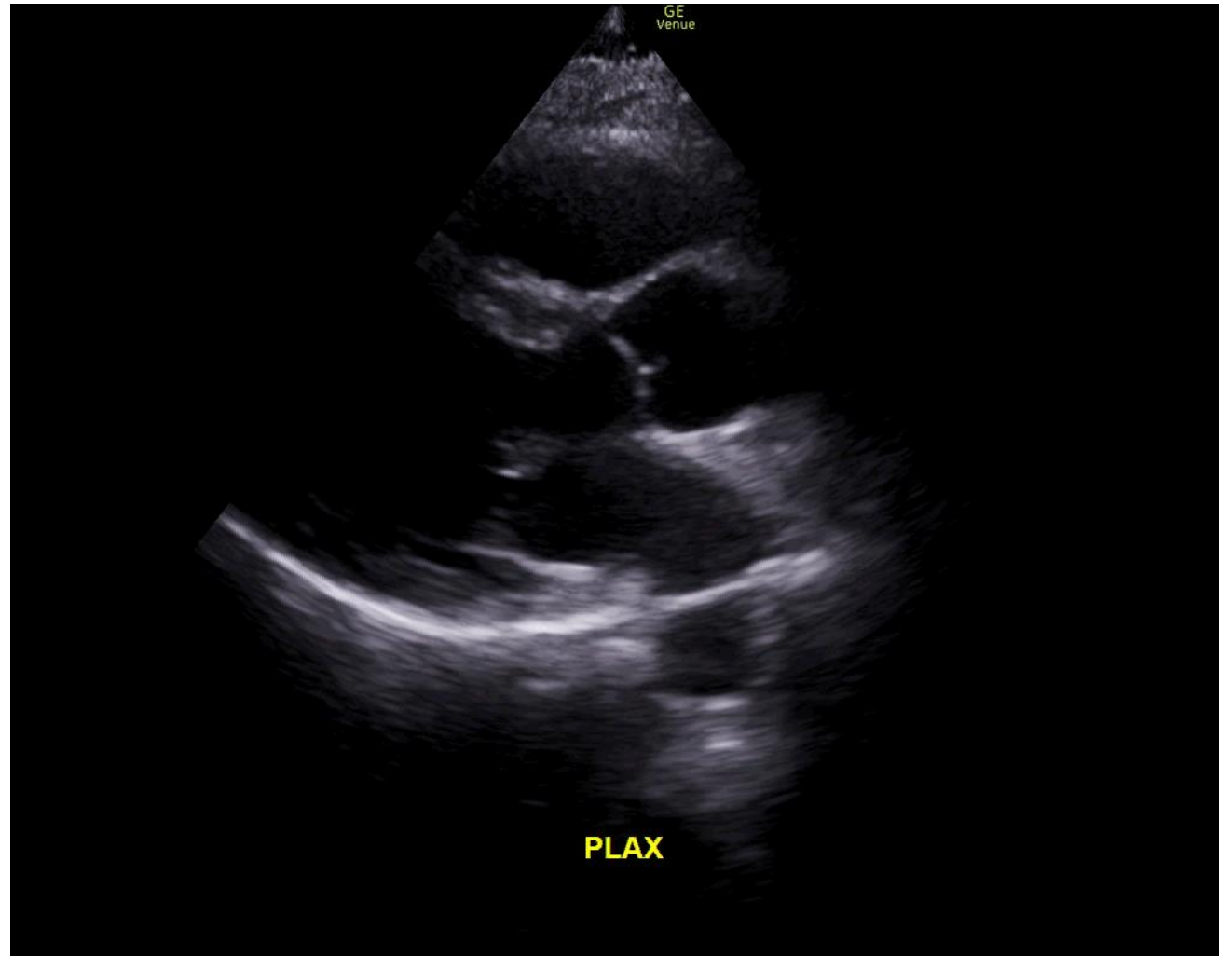
This is the picture we're aiming for

Look to see:

Is there a pericardial effusion? (making the bright white line of the pericardium look like two separate lines with a black area in between)

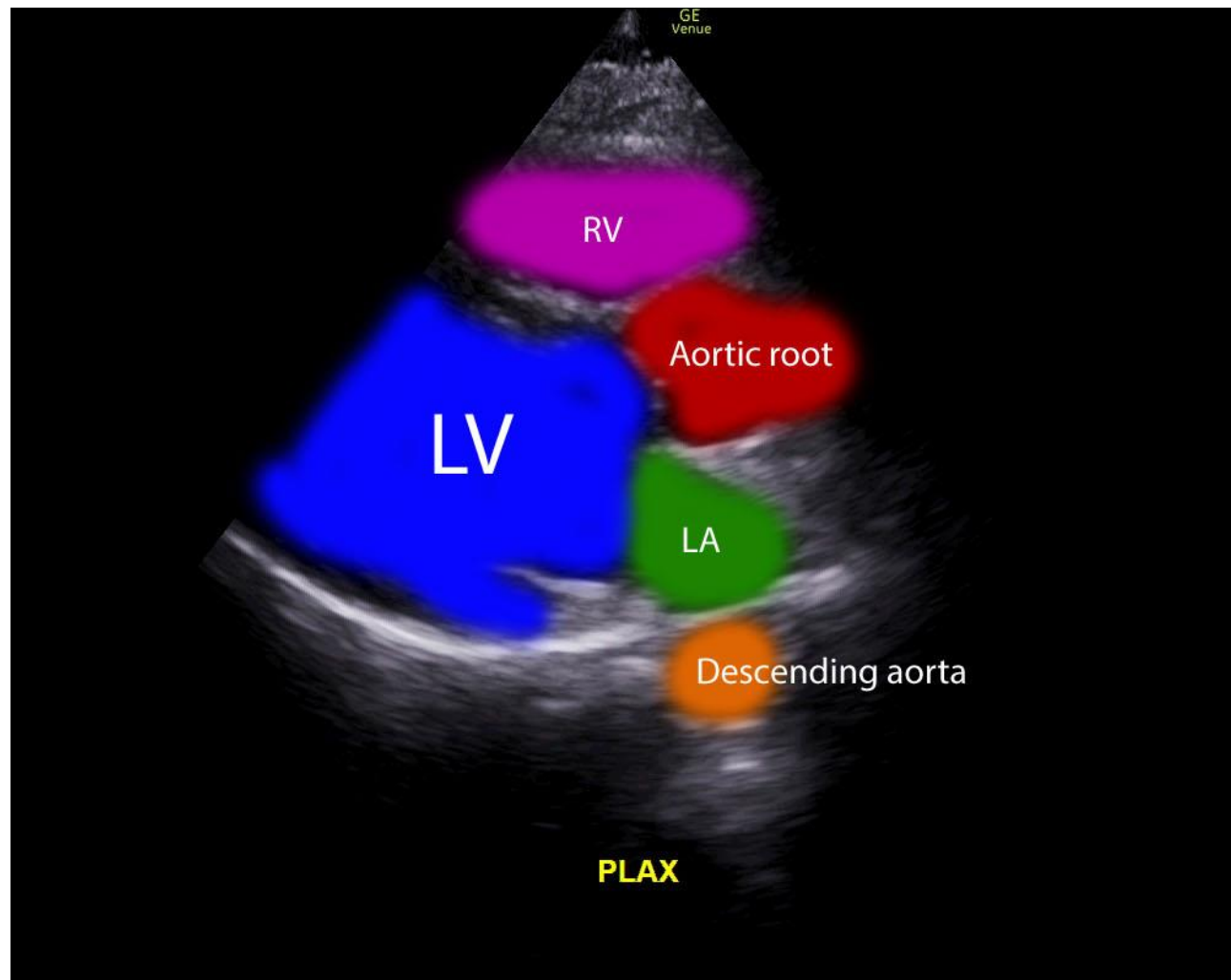
Is there normal contractility of the LV?

Are the LA, aortic root, and RV all approximately the same size?

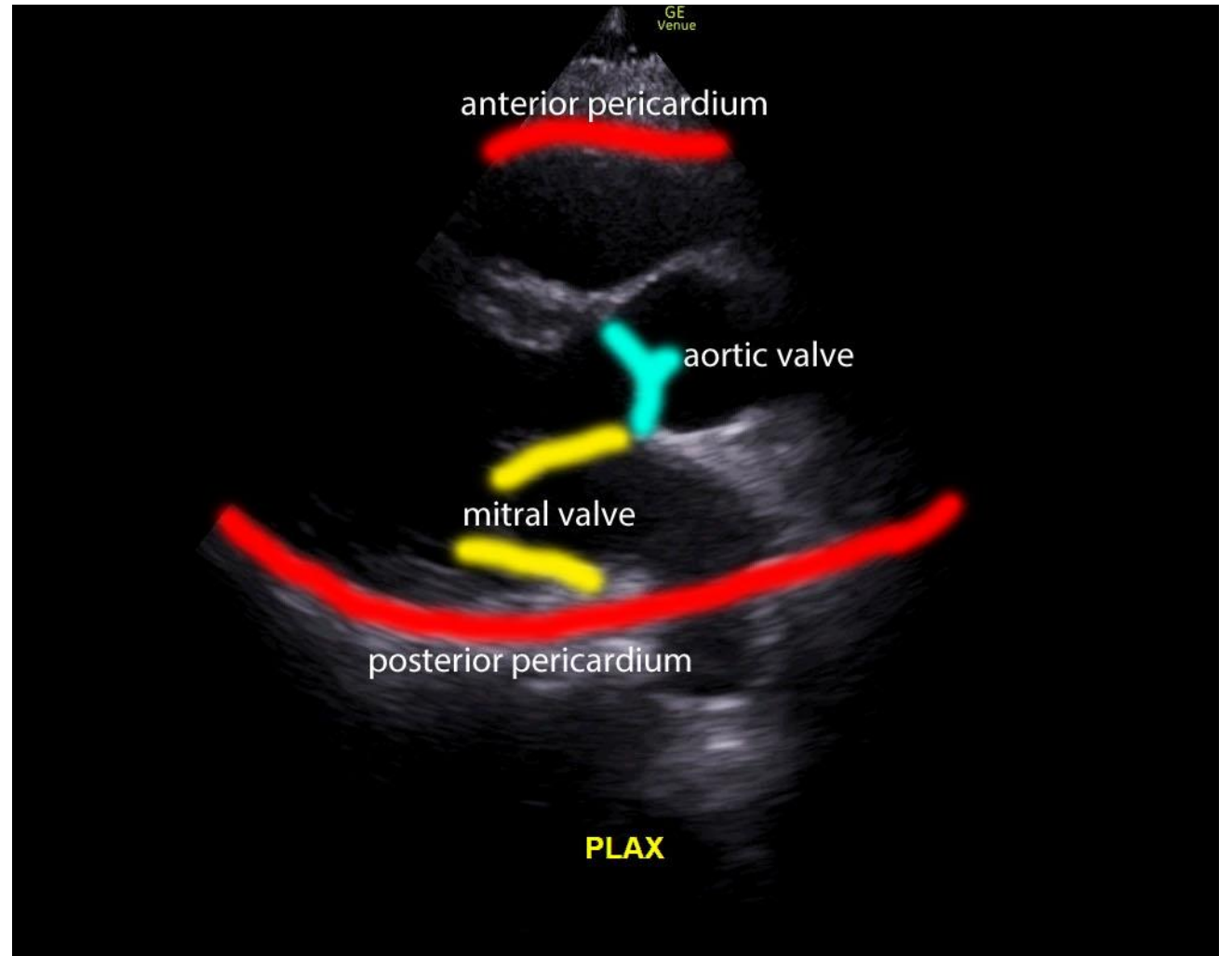




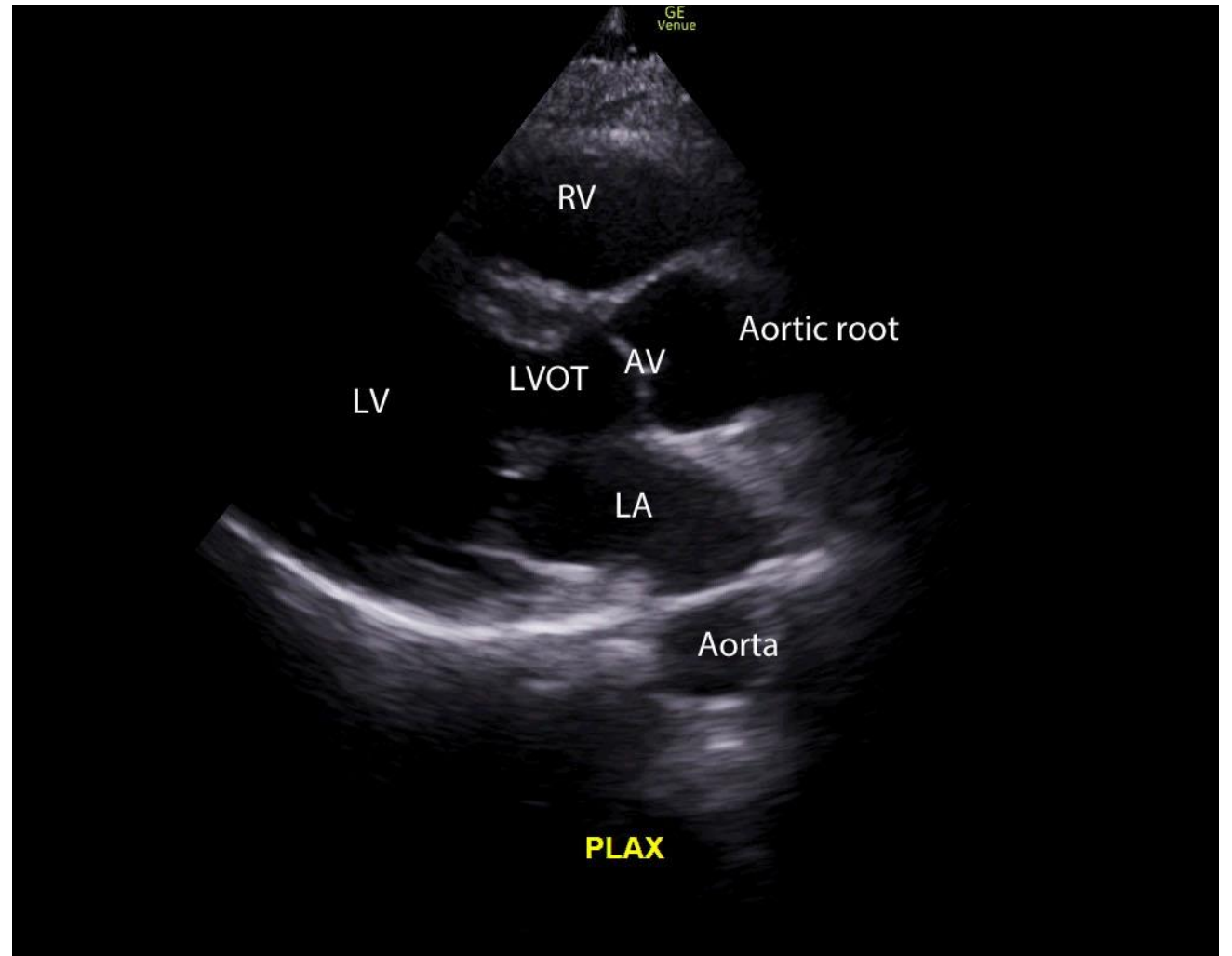
With labels



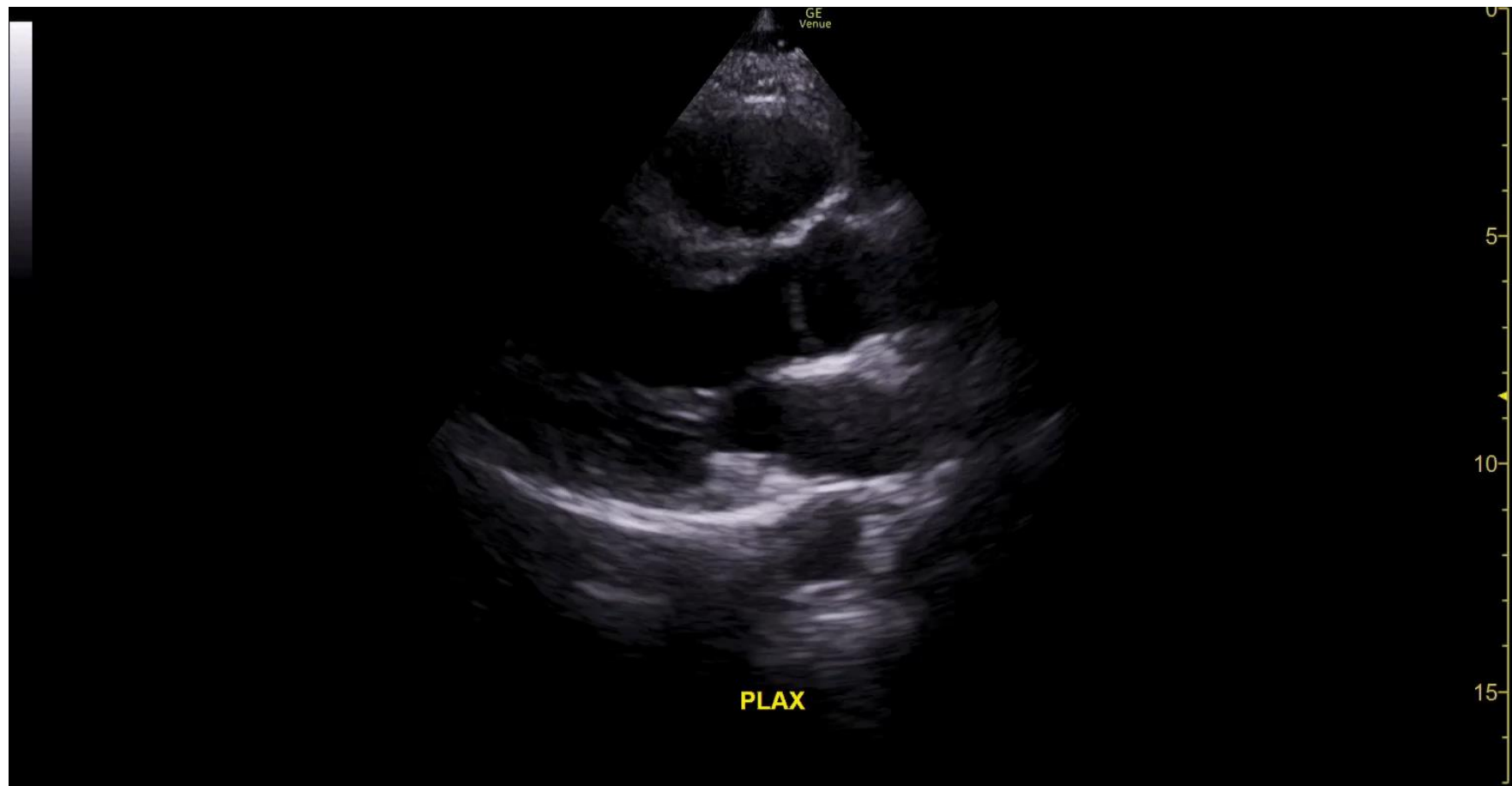
# Valves and pericardium



Original image



# PLAX video loop



Parasternal short axis

# Probe position

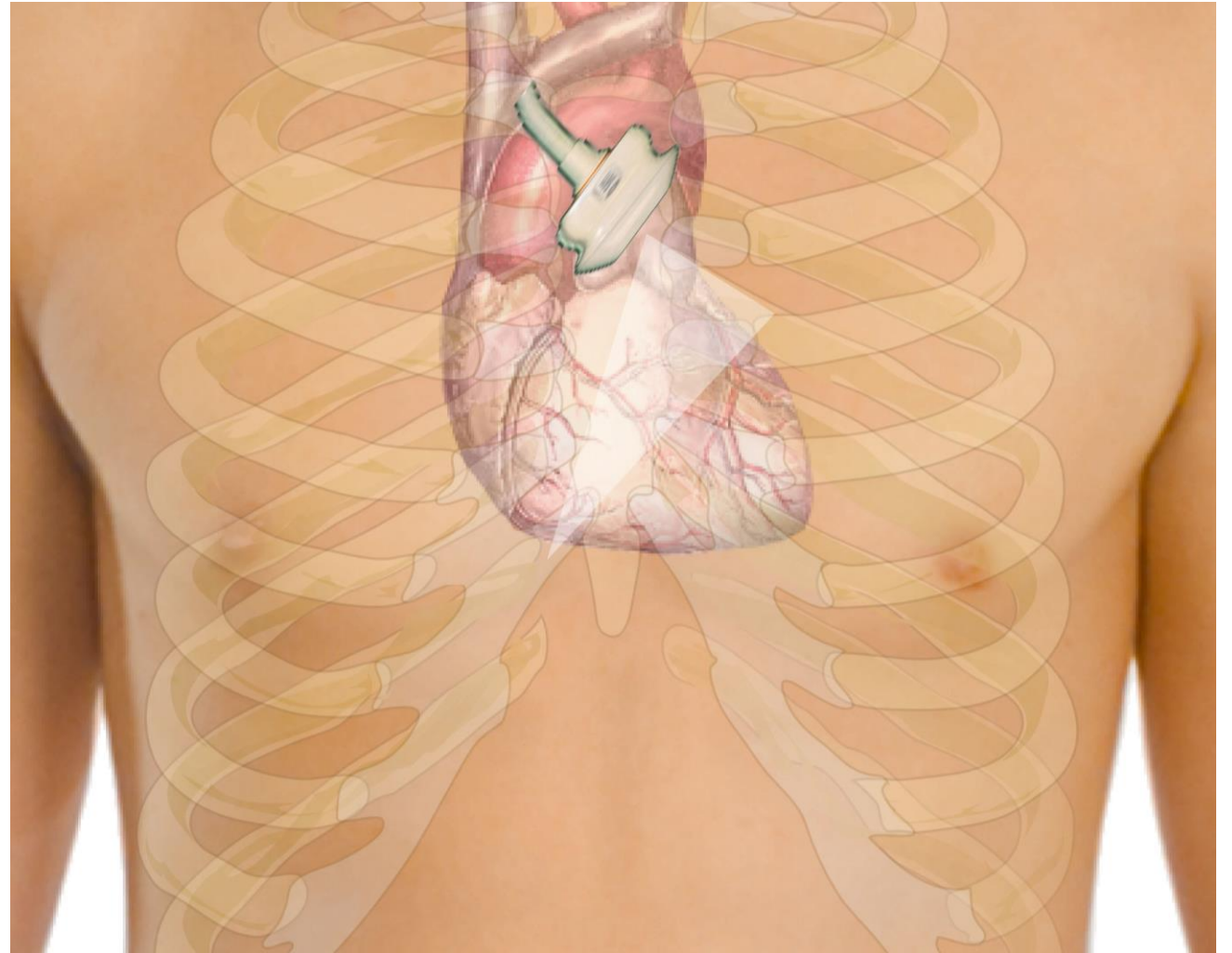
Starting with the parasternal long axis view, get the mitral valve in the middle of the screen

Rotate the probe 90 degrees clockwise

The probe marker should now be pointing roughly towards the patient's left shoulder

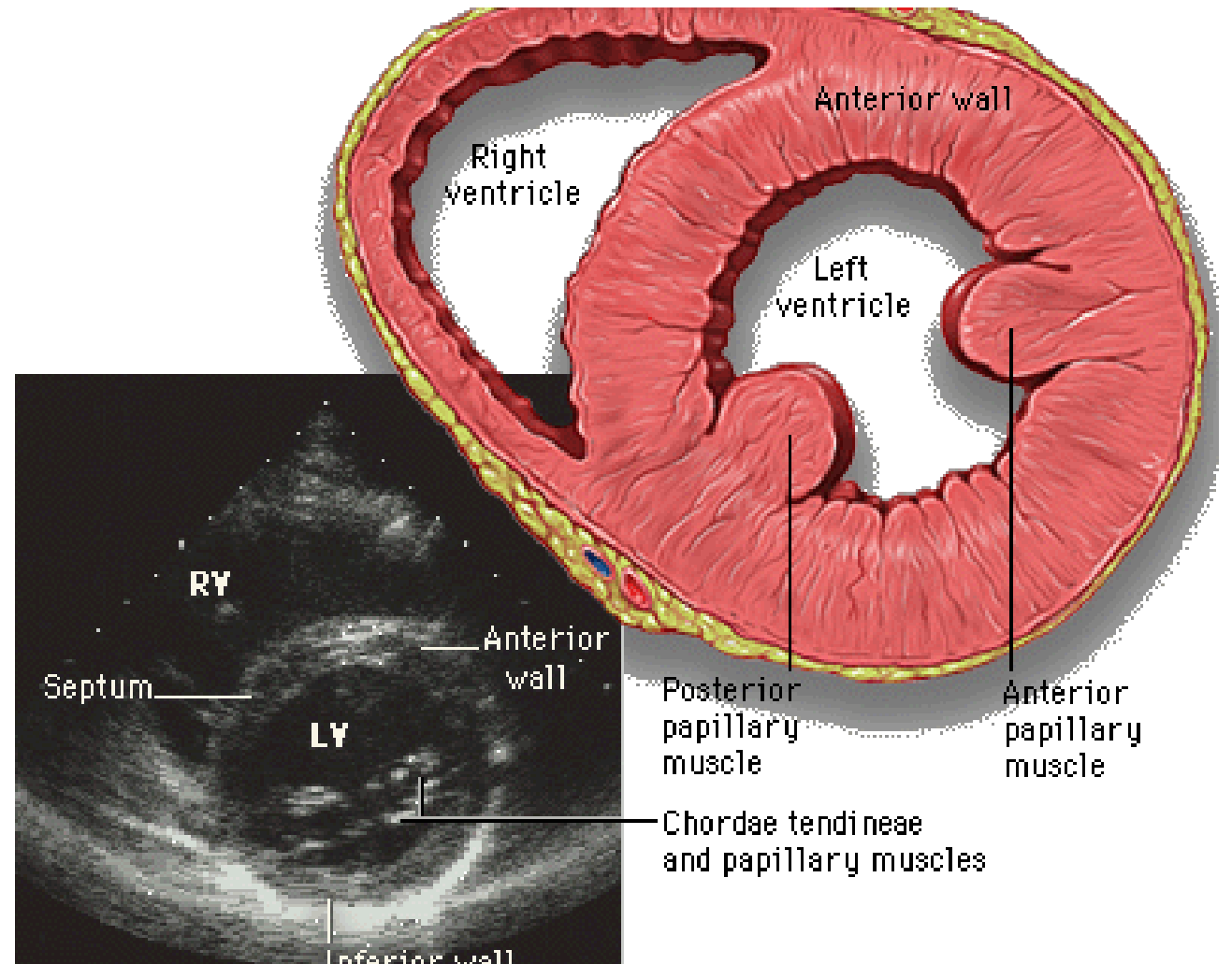
Fan up towards the aortic valve and down towards the apex

Just below the mitral valve are the papillary muscles, and the essential view is at this level



# Cross section

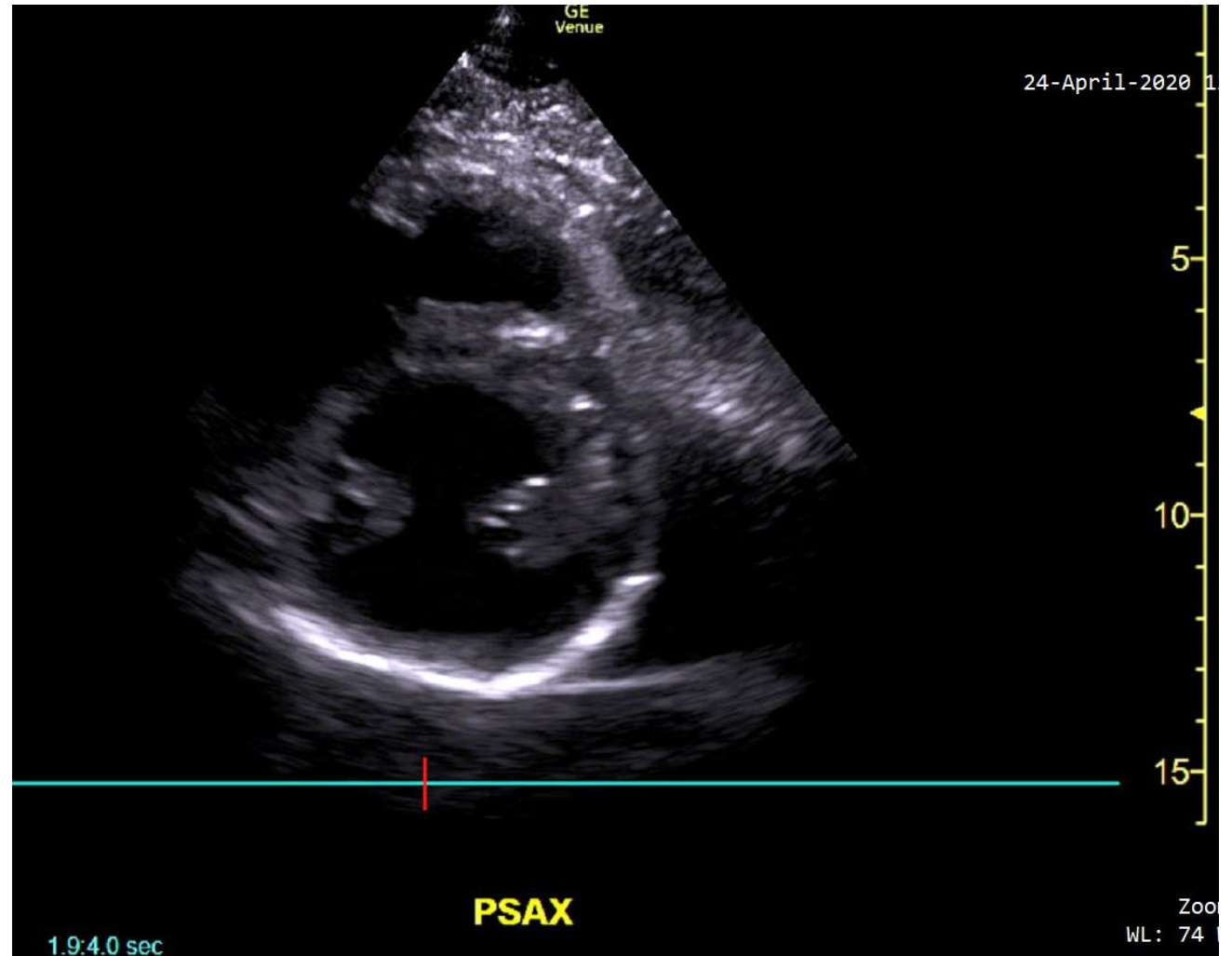
This image shows the cross section of the heart created by the beam



# PSAX image

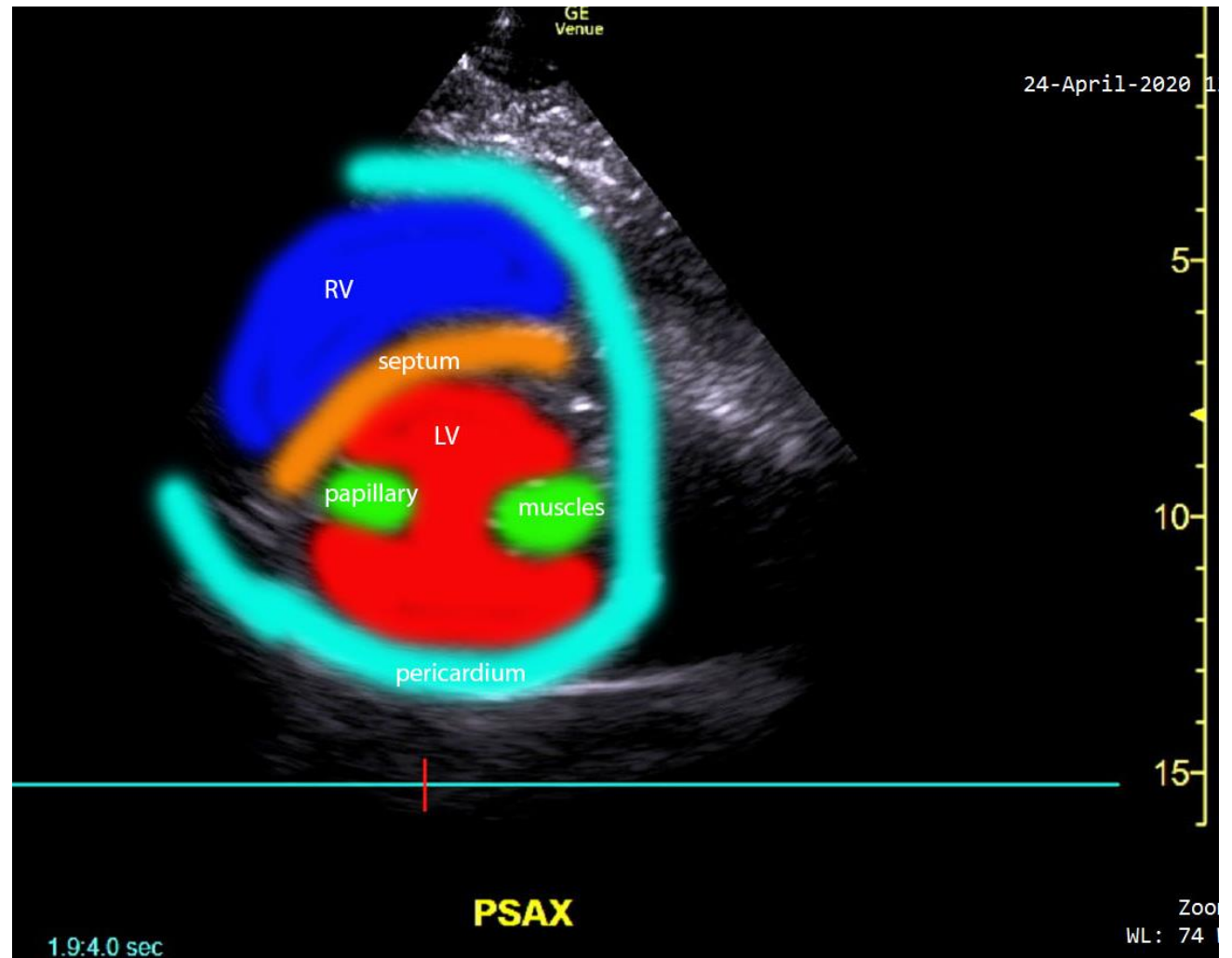
This is the picture we're aiming for

The left ventricle should look round, and the septum should not be flattened

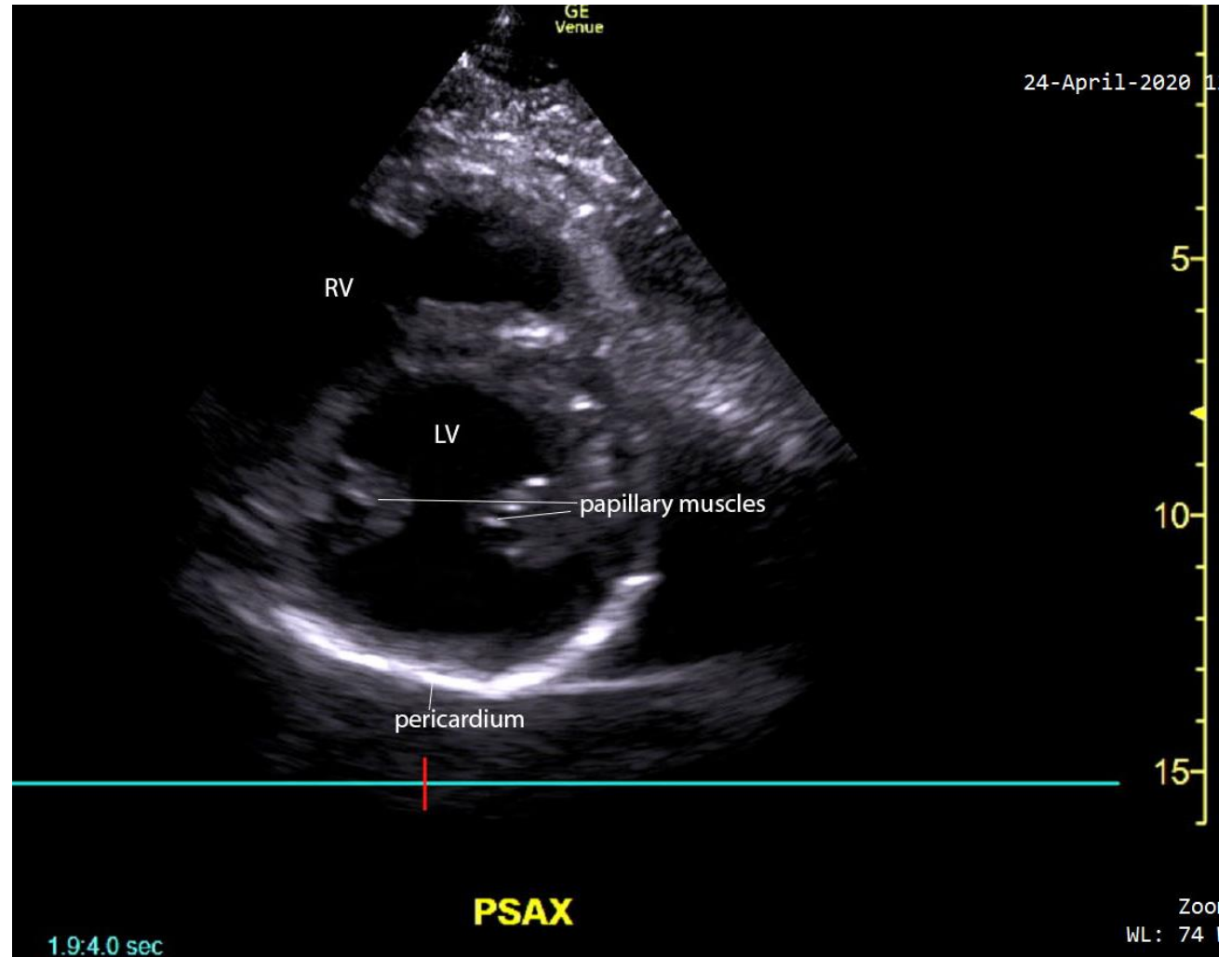




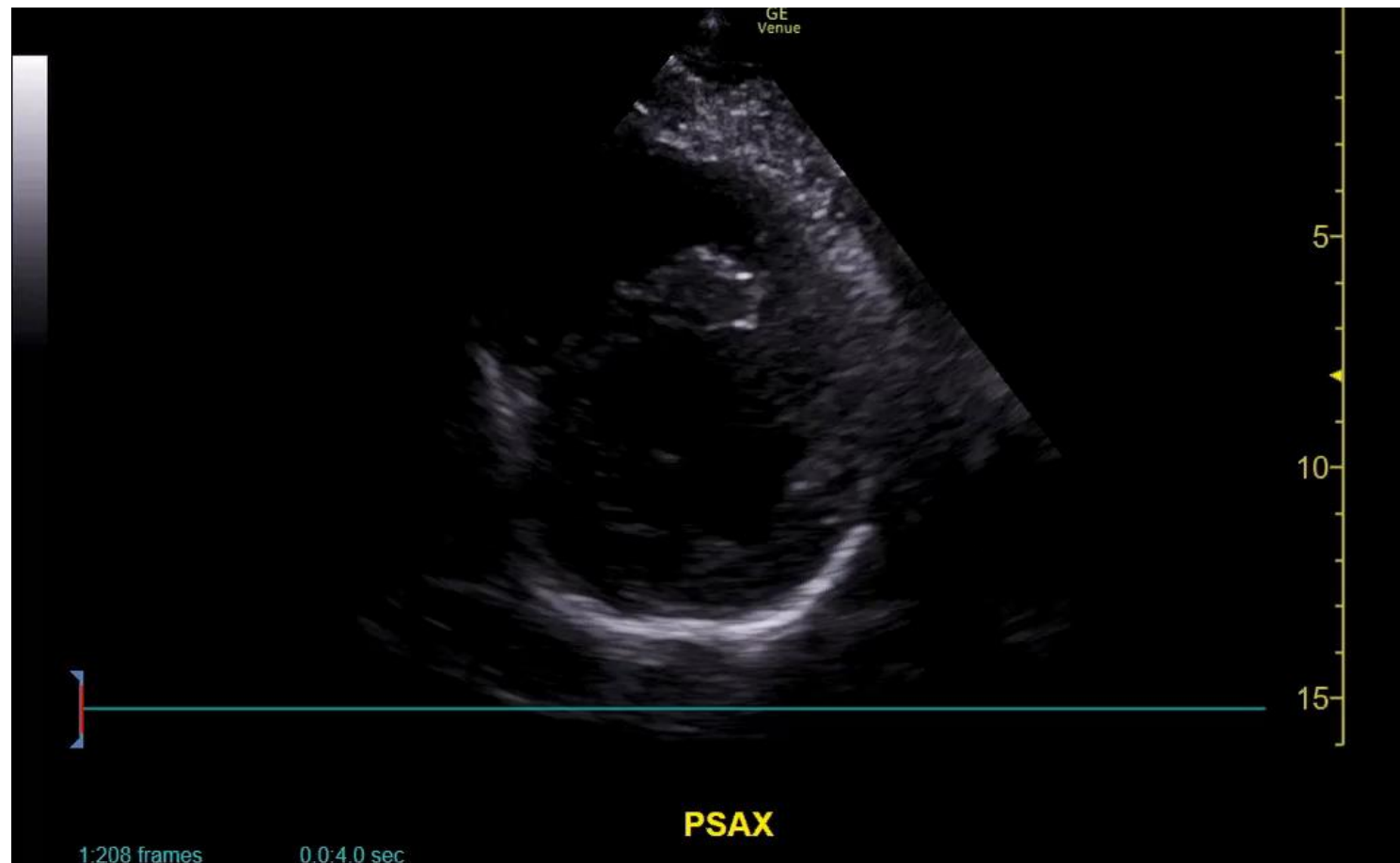With labels



Original image



# PSAX video loop



Apical 4 chamber

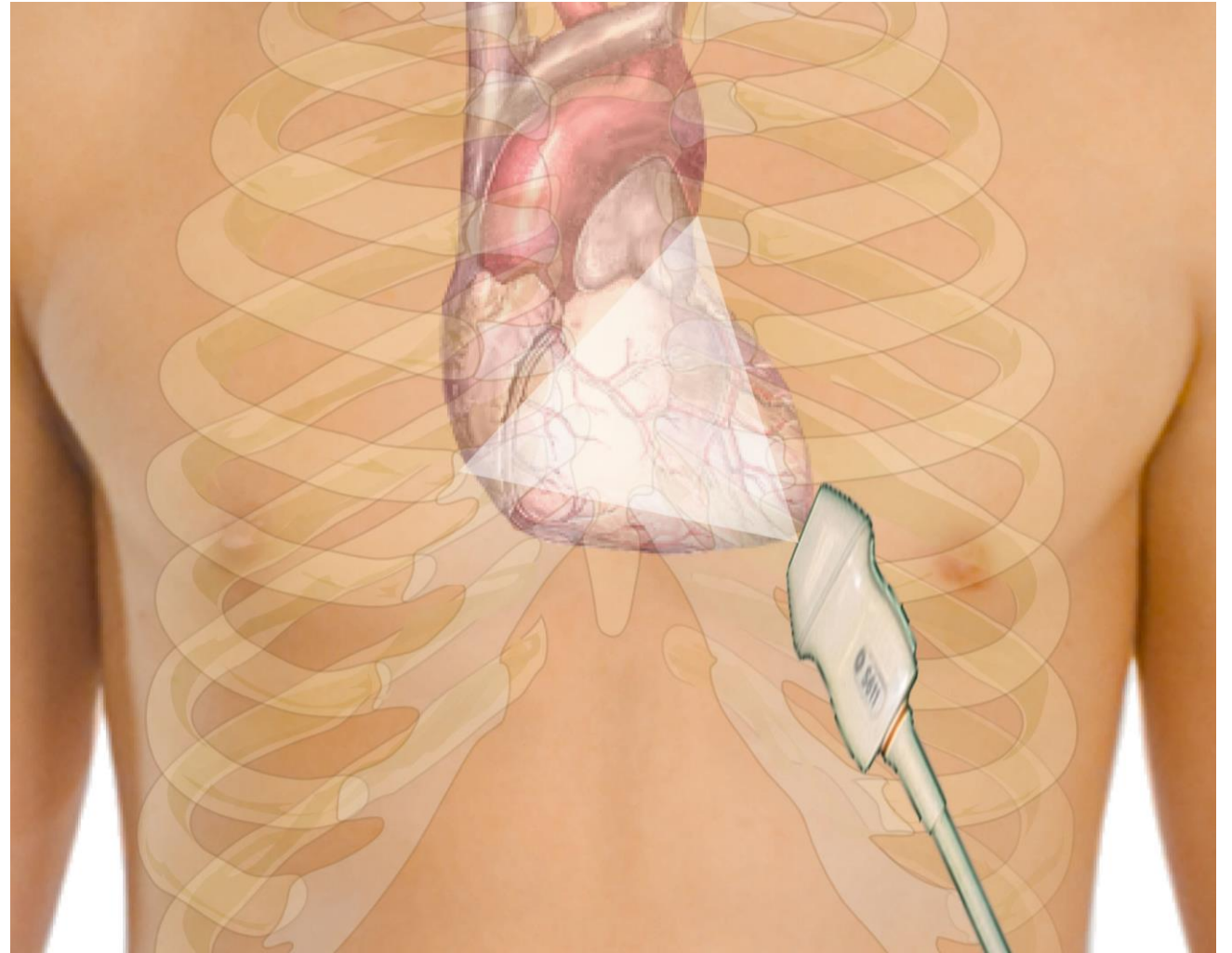
# Probe position

Rotate the probe clockwise a little so the marker is at 2 o'clock or 3 o'clock (pointing at their left upper arm)

Place the probe on the chest where the apex beat is (roughly at the level of the xiphoid, the 6<sup>th</sup> intercostal space, in the mid-clavicular line)

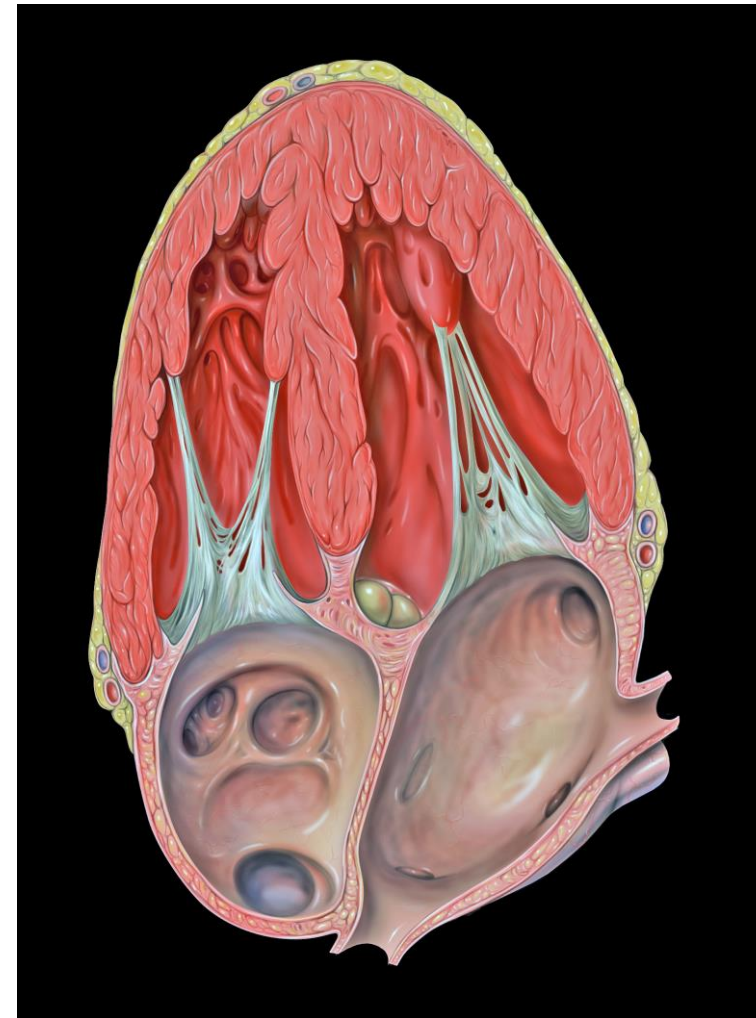
Shine the beam of the probe towards the patient's right shoulder so it goes through the whole heart

(Alternatively, start from the PSAX and slide round towards the patient's left, pointing the beam up towards the patient's right shoulder)



# Cross section

This image shows the cross section of the heart created by the beam

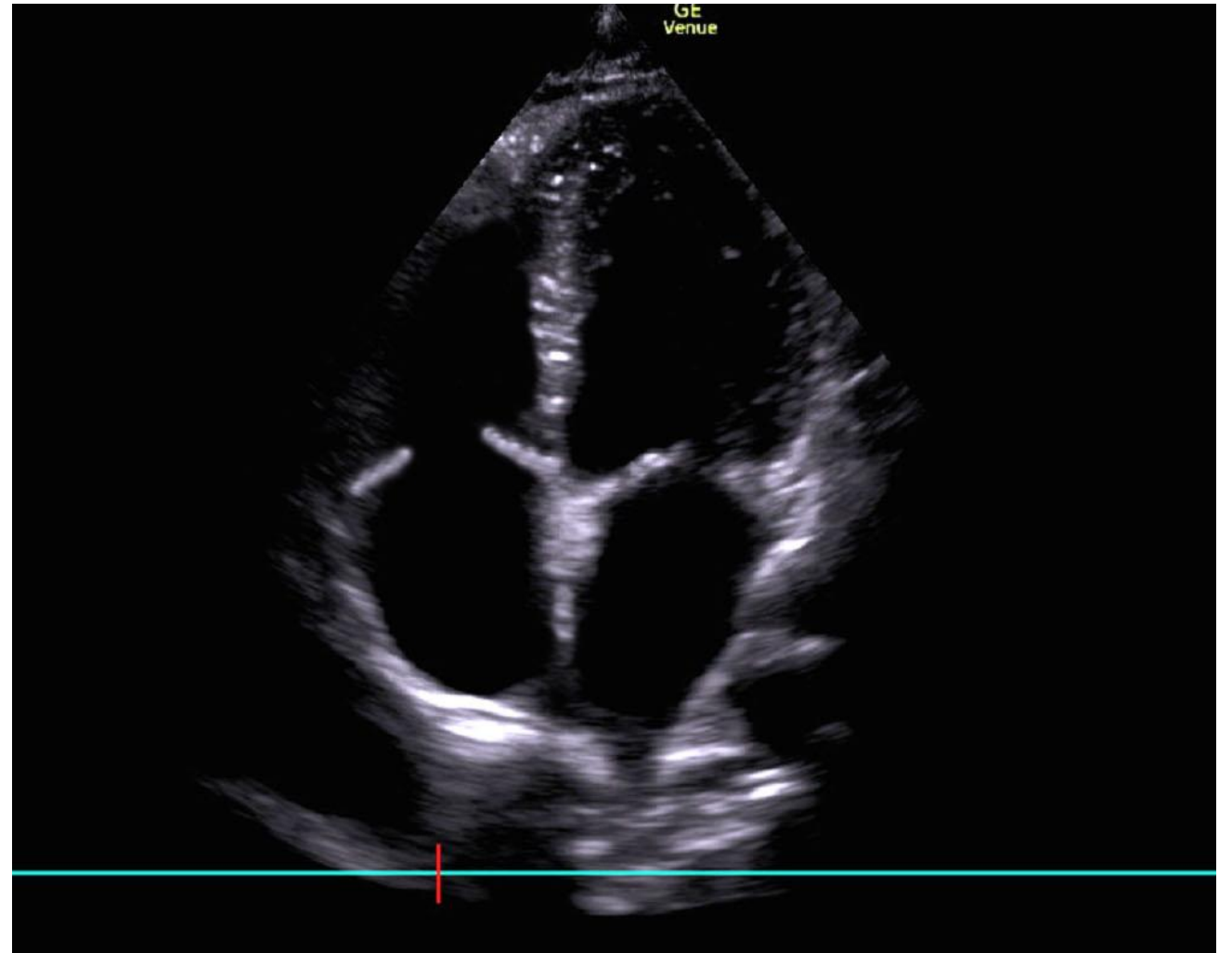


# Apical cross section

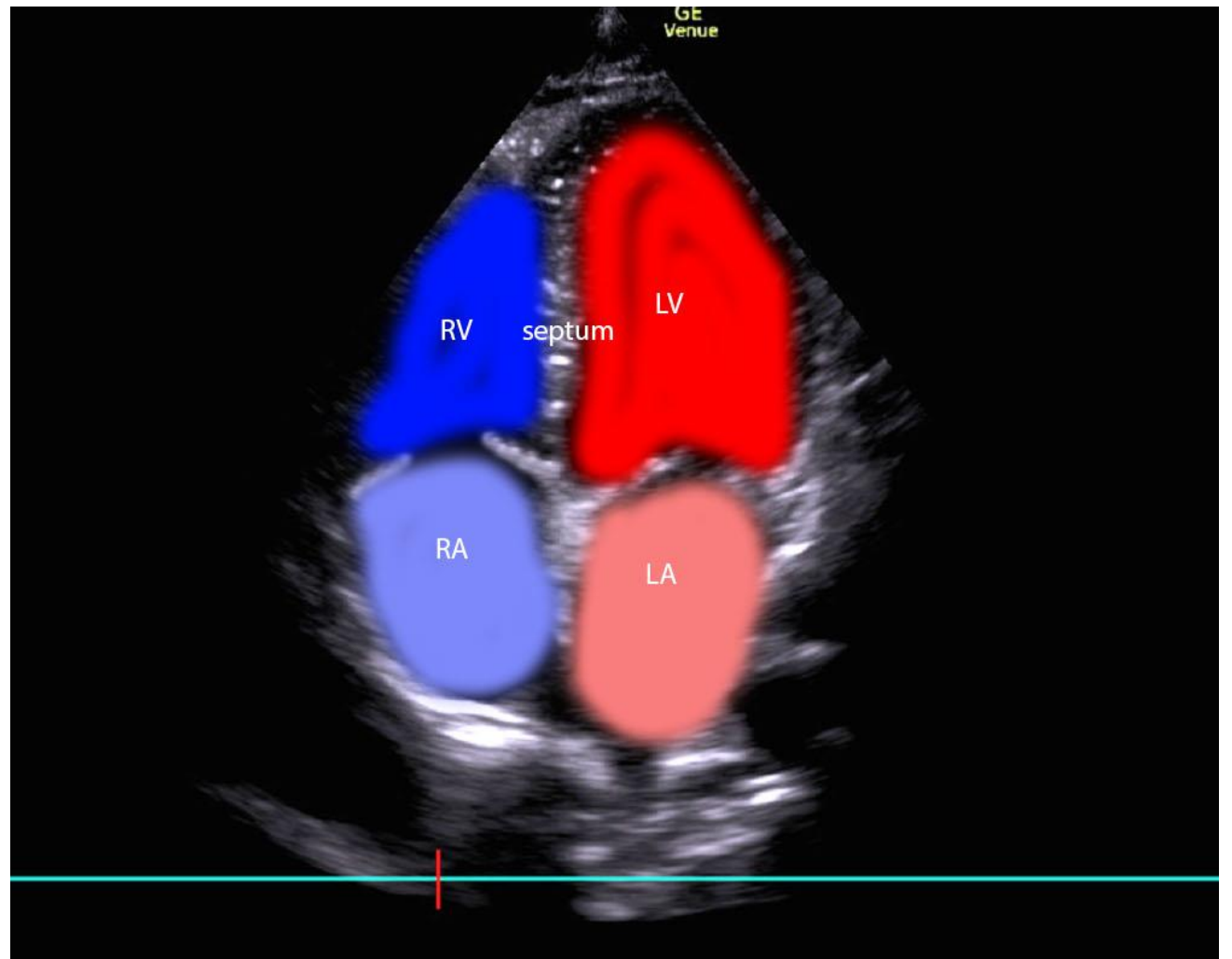
This image shows the 2 dimensional slice we are trying to get

The RV should be smaller than (about 2/3 the size of) the LV

Look at whether the LV is contracting well

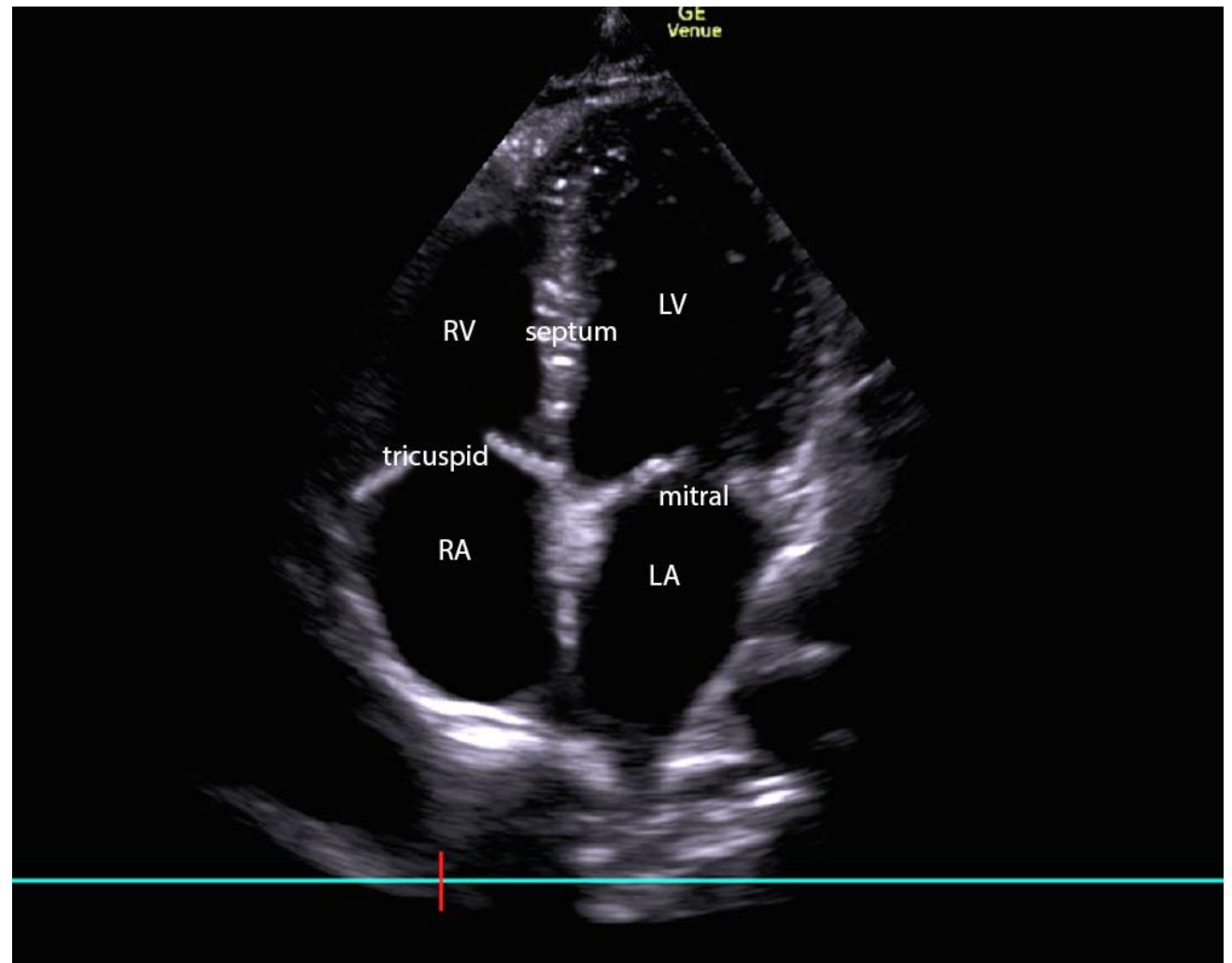


With labels

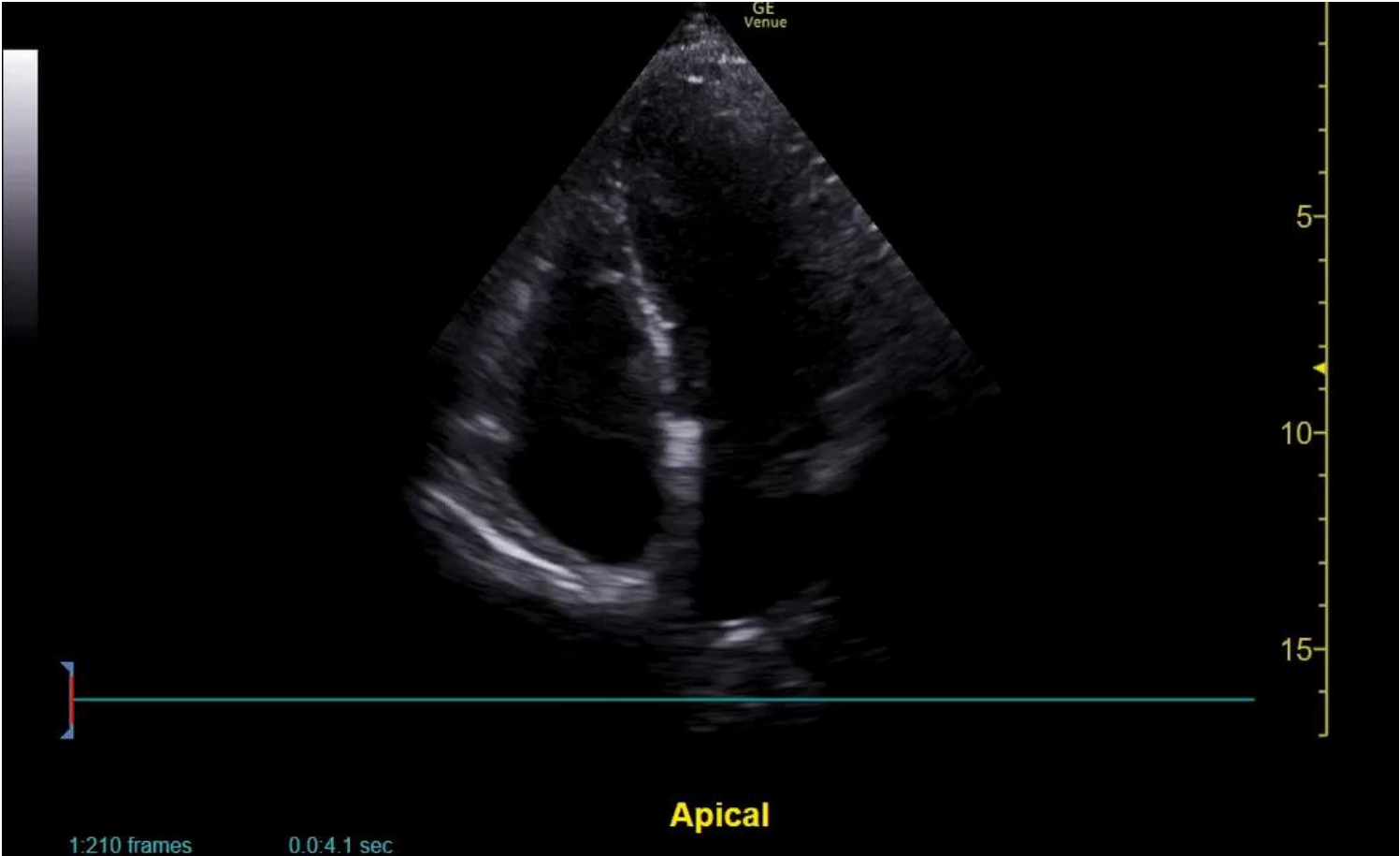




Original image



# Apical video loop



Subcostal

# Probe position

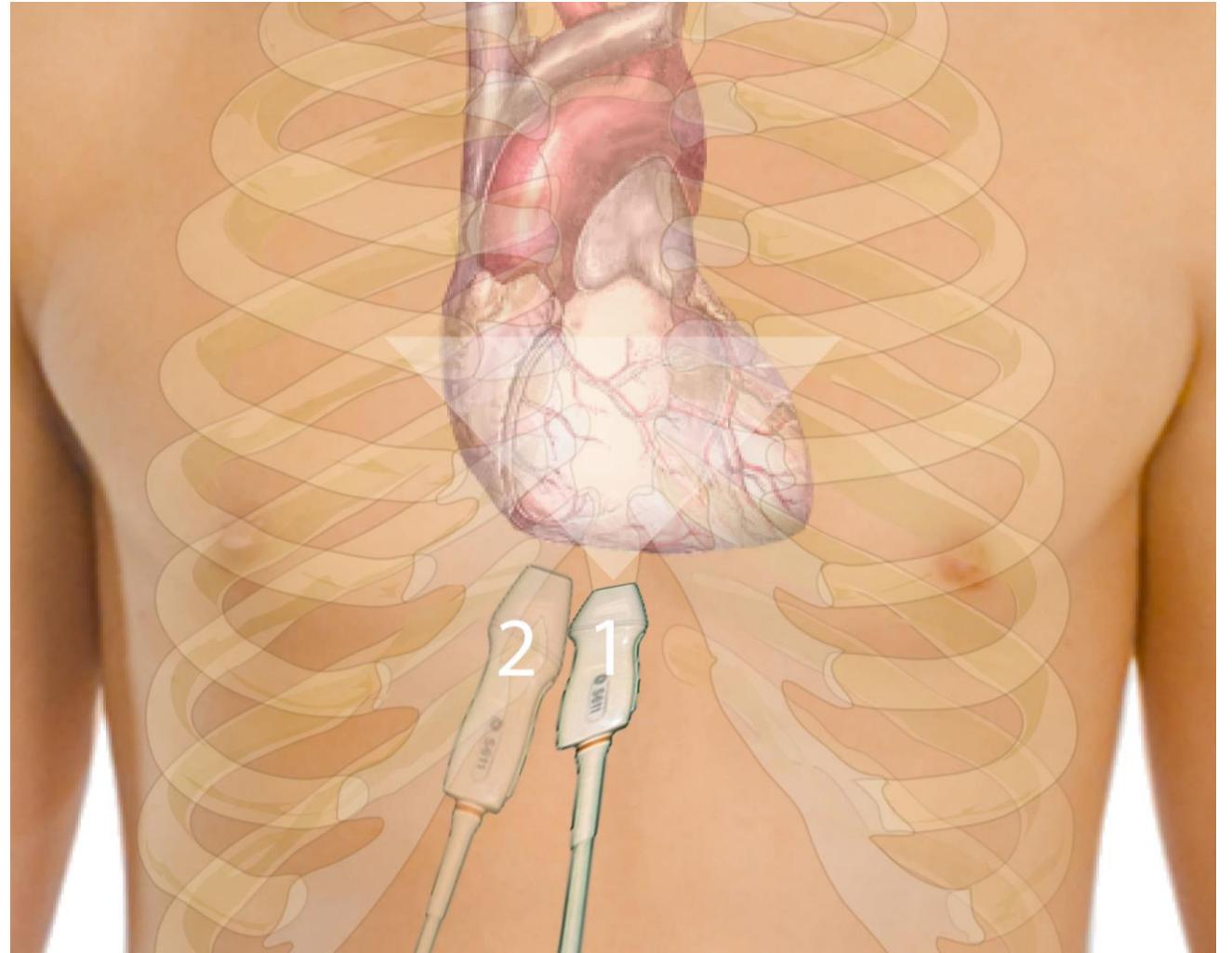
1) With the probe marker pointing towards the patient's left, place the probe underneath the xiphisternum

Slowly press the probe gently but firmly into the patient's abdomen to get underneath the ribcage

Try to shine the beam of the ultrasound up towards the patient's head or left shoulder to show the heart, rather than towards the spine

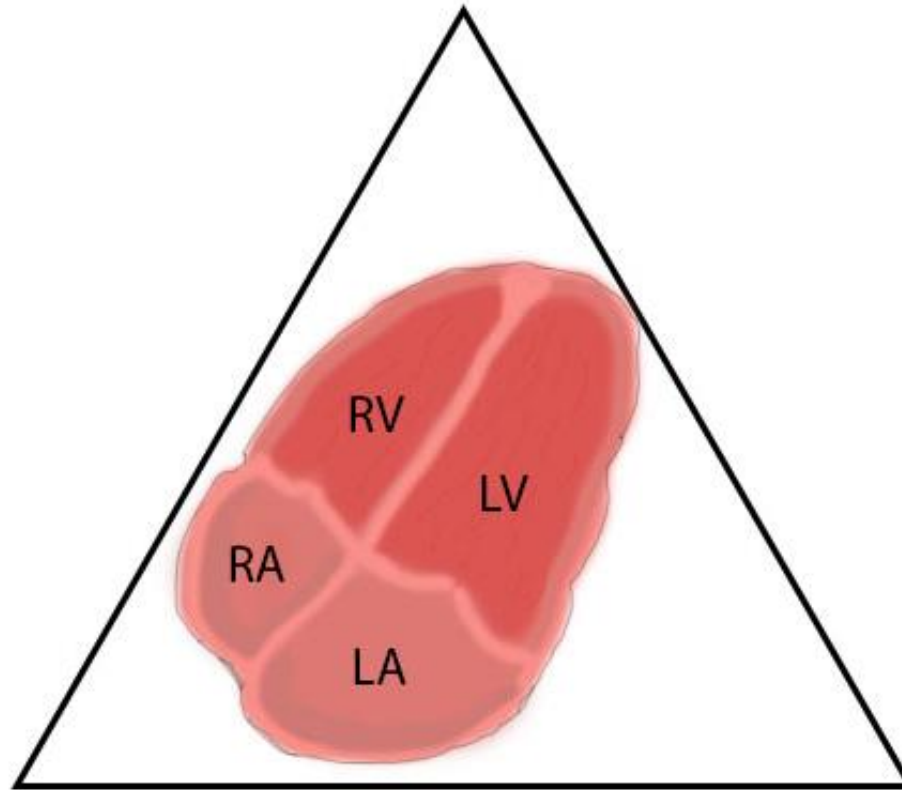
It can help to ask the patient to take a deep breath in and hold it

2) If bowel gas obscures the view, try moving the probe to the patient's right and shining the ultrasound beam through the liver towards the heart



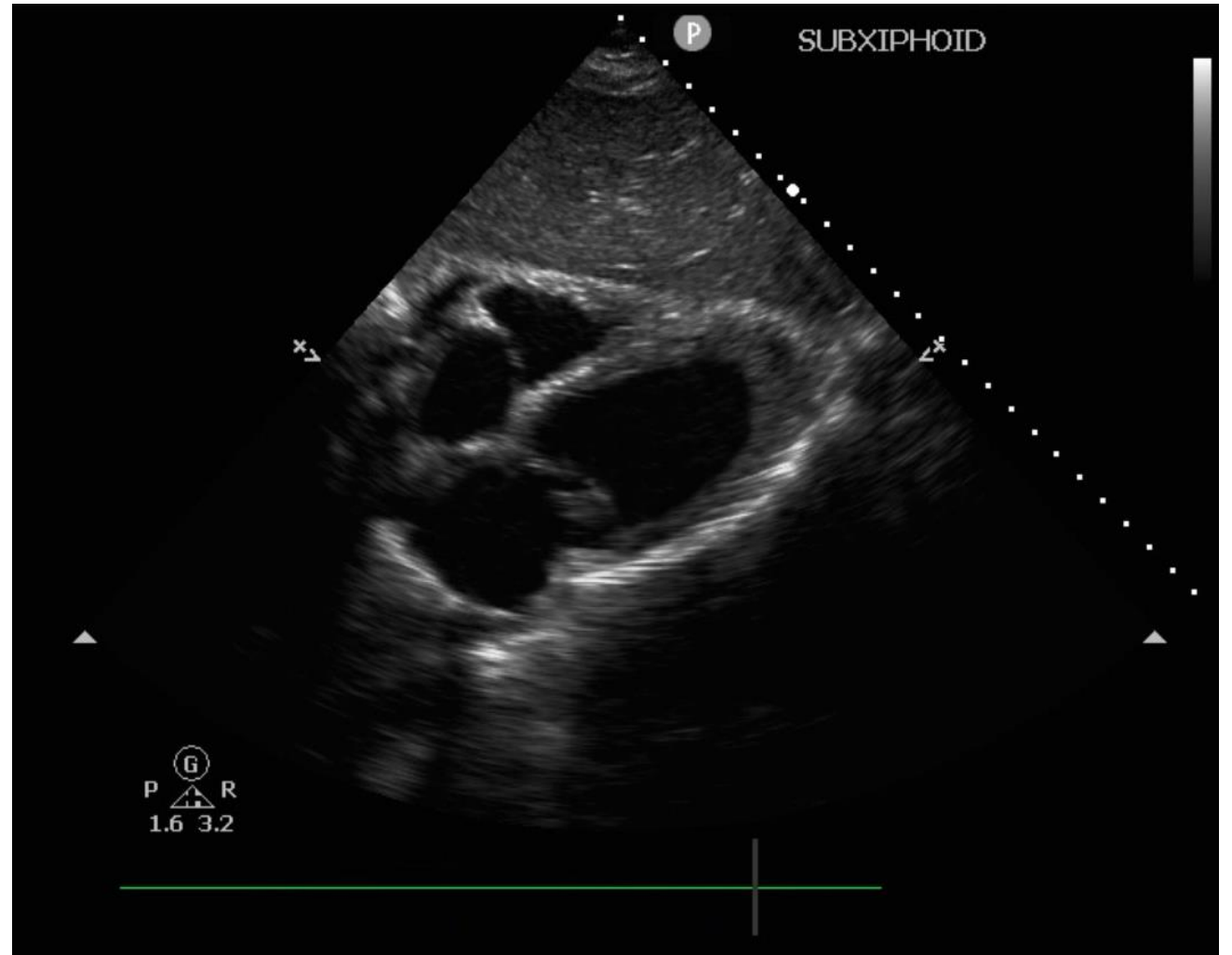
# Cross section

This image shows the cross section of the heart created by the beam

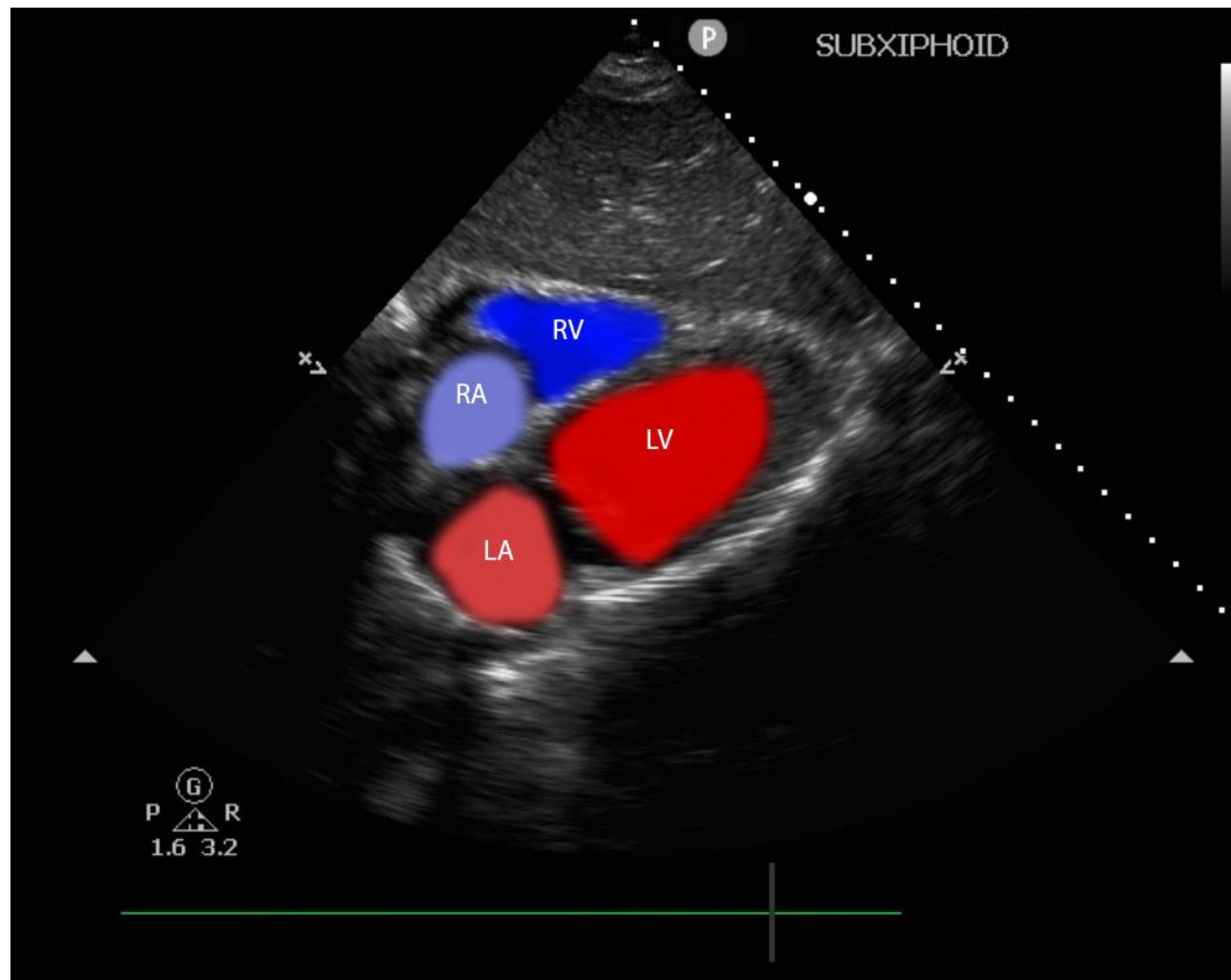


# Subcostal image

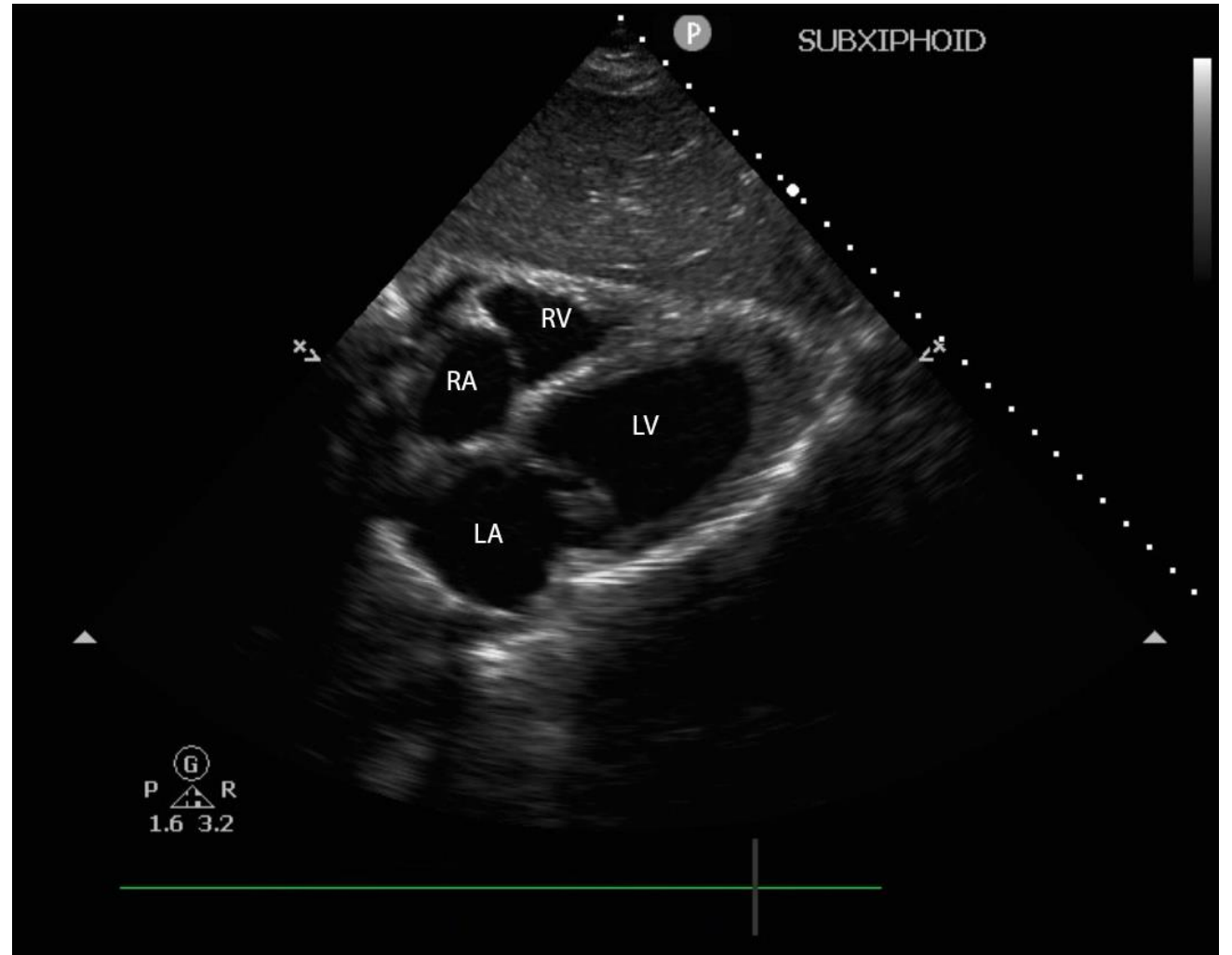
This image shows the 2 dimensional slice we are trying to get



With labels

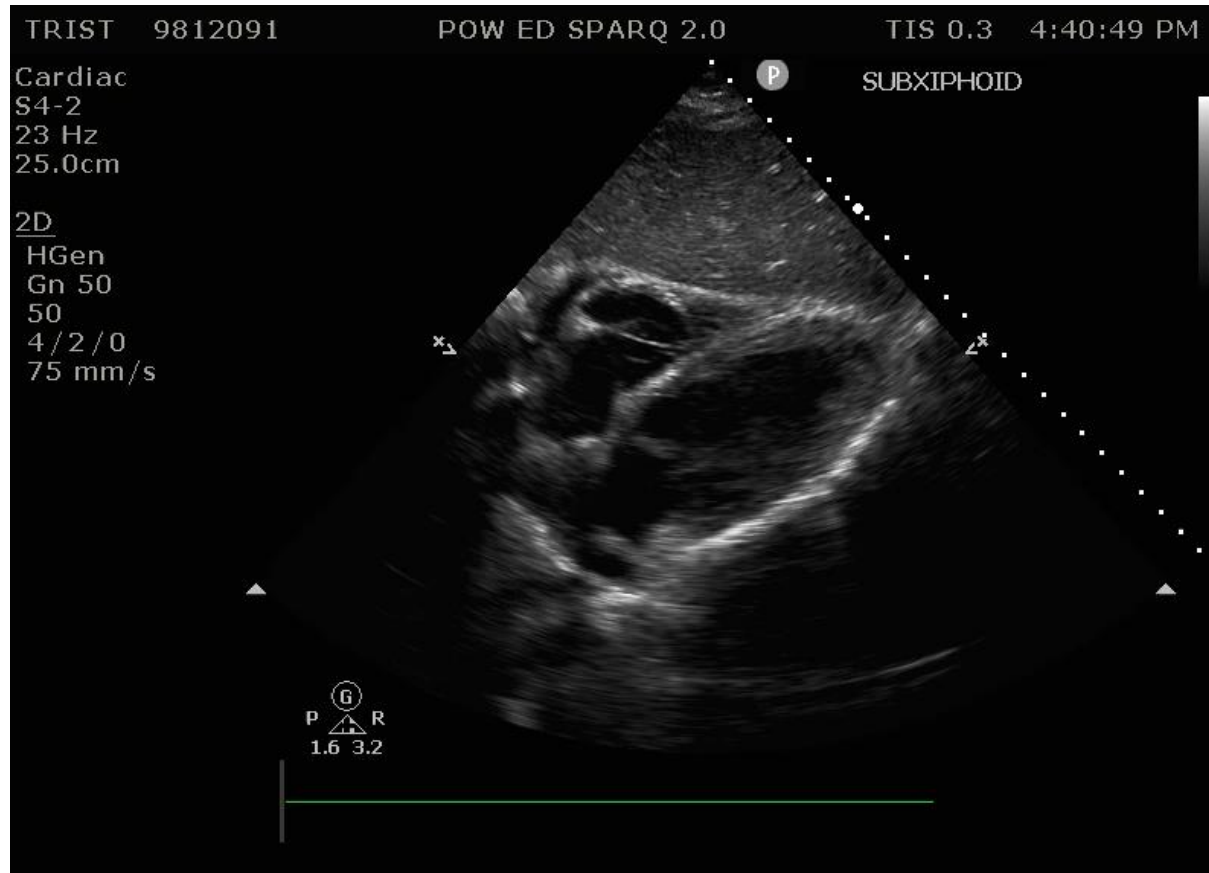


Original image





# Subcostal video loop



IVC

# IVC

From the subcostal view, get the right atrium in the middle of the screen and rotate the probe anti-clockwise to be pointing at the patient's head

Look for the IVC entering the patient's RA. Be careful not to get confused with the thicker walled aorta which is just to the left of the IVC. Another potential mistake is looking at the portal vein, which runs horizontally. To avoid this make sure you're probe is in the longitudinal plane (marker towards the head)

Check for normal respiratory variability. If the IVC is small (<1cm) and collapses a lot (>50%) this indicates underfilling. If it is large (>2cm) and does not collapse much (<50%) this suggests overload. If the measurements are somewhere between these two extremes, then the information is not conclusive.

