

# GSSE Embryology Tutorial

Matthew Jacob Smith

Eastern and Greater Southern Surgical Skills Network

2021

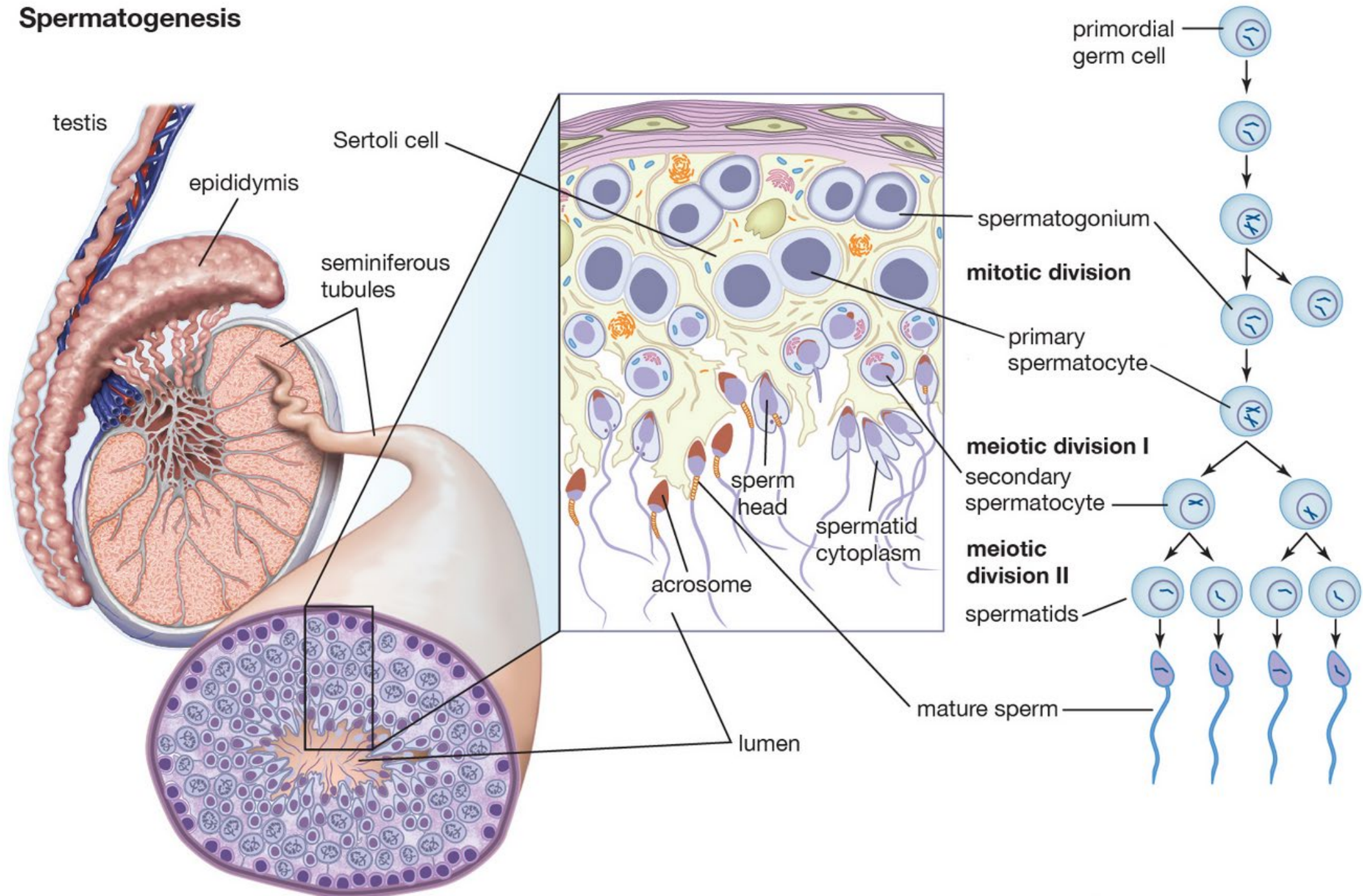
# Overview

1. Early embryonic development
2. Central nervous system development
3. Endodermal tube formation and derivatives
4. Urogenital system development
5. Branchial cleft derivatives
6. Cardiac and vasculature development

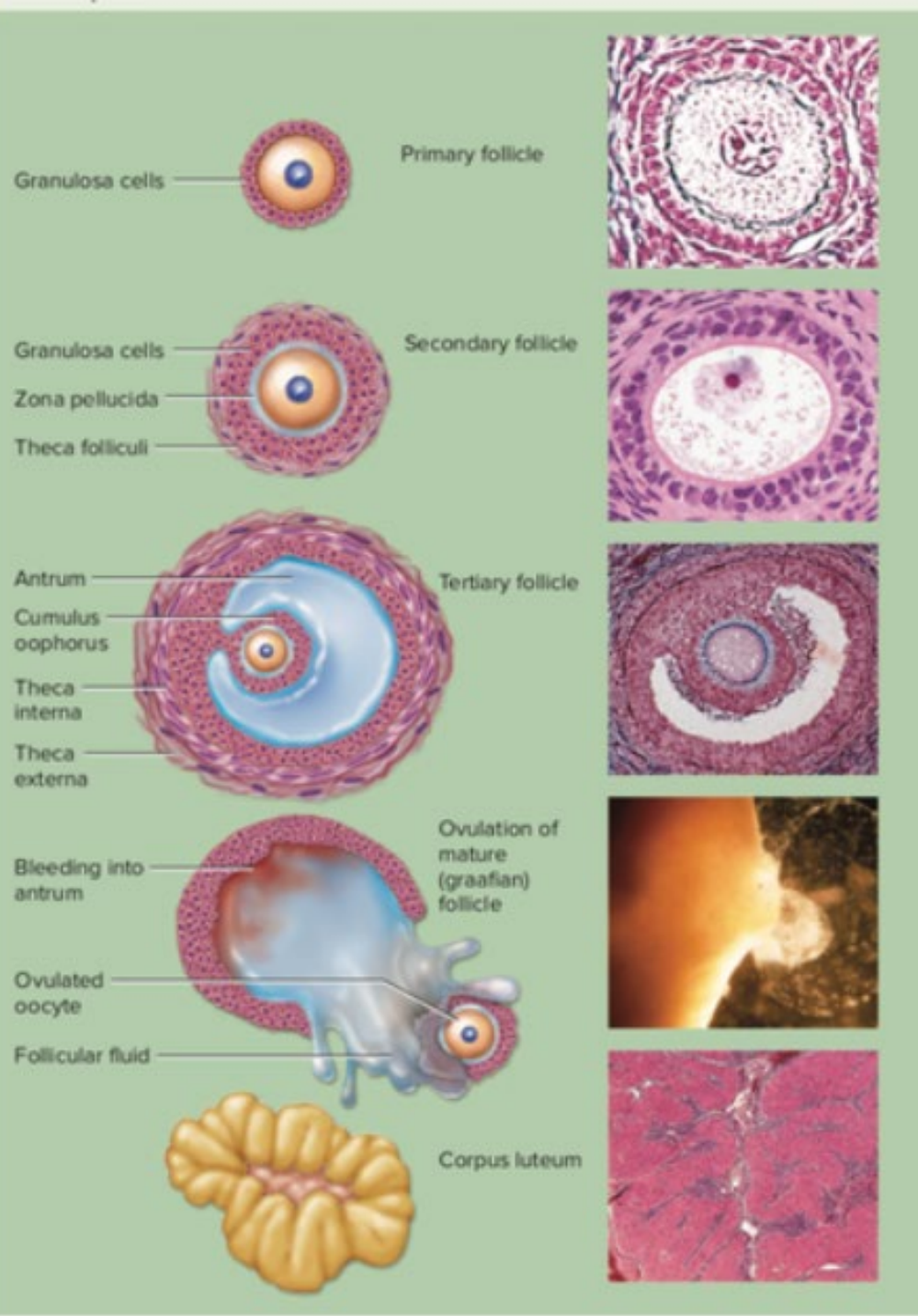
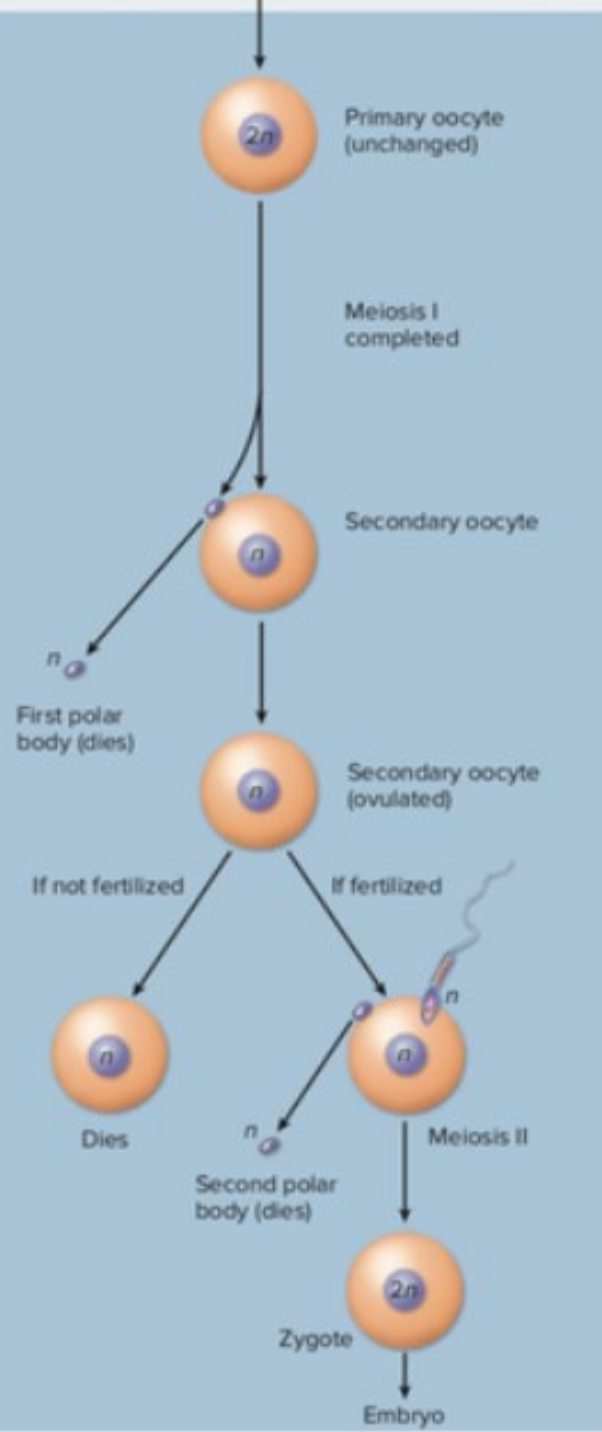
# Overview

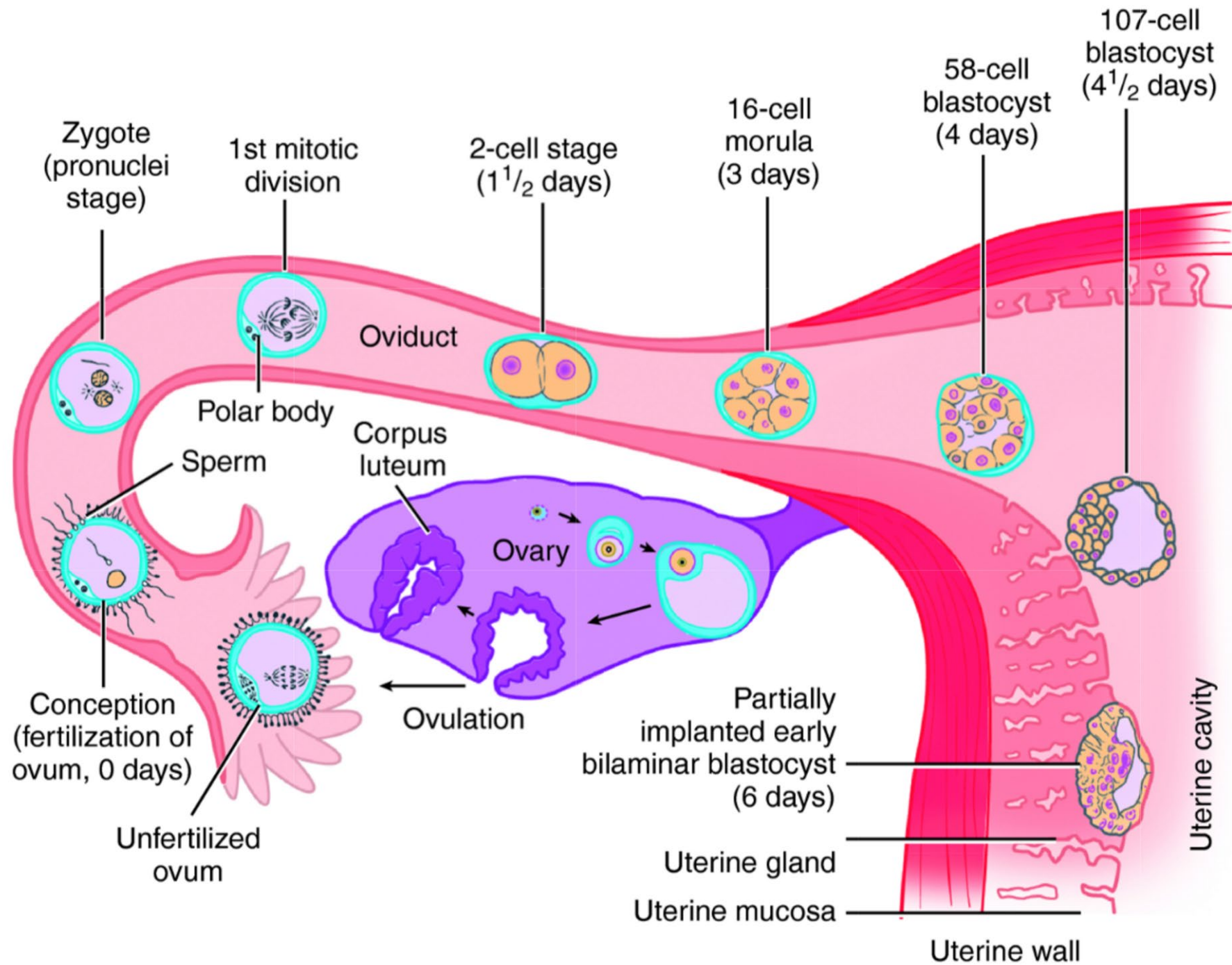
1. **Early embryonic development**
2. Central nervous system development
3. Endodermal tube formation and derivatives
4. Urogenital system development
5. Branchial cleft derivatives
6. Cardiac and vasculature development

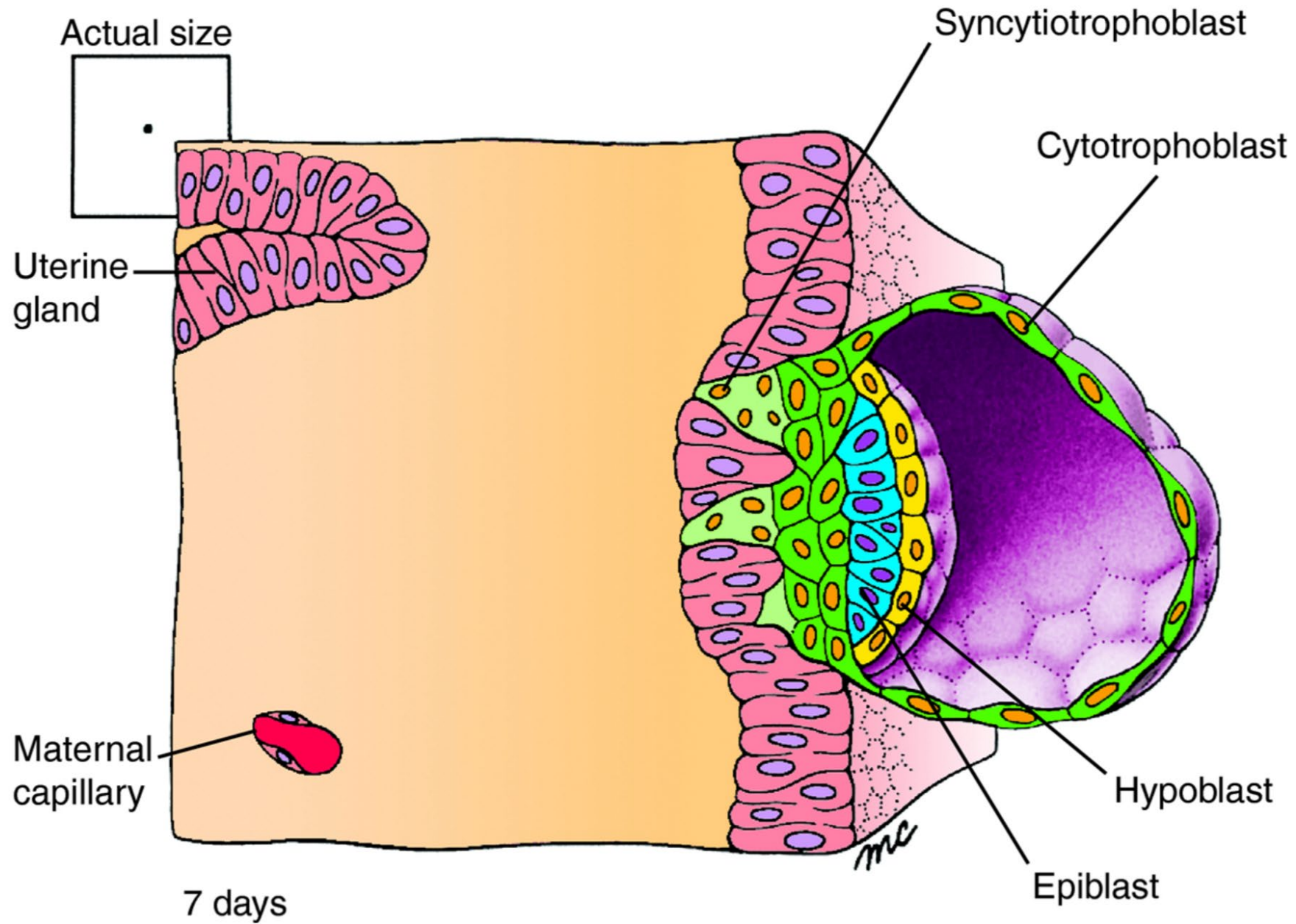
# Spermatogenesis



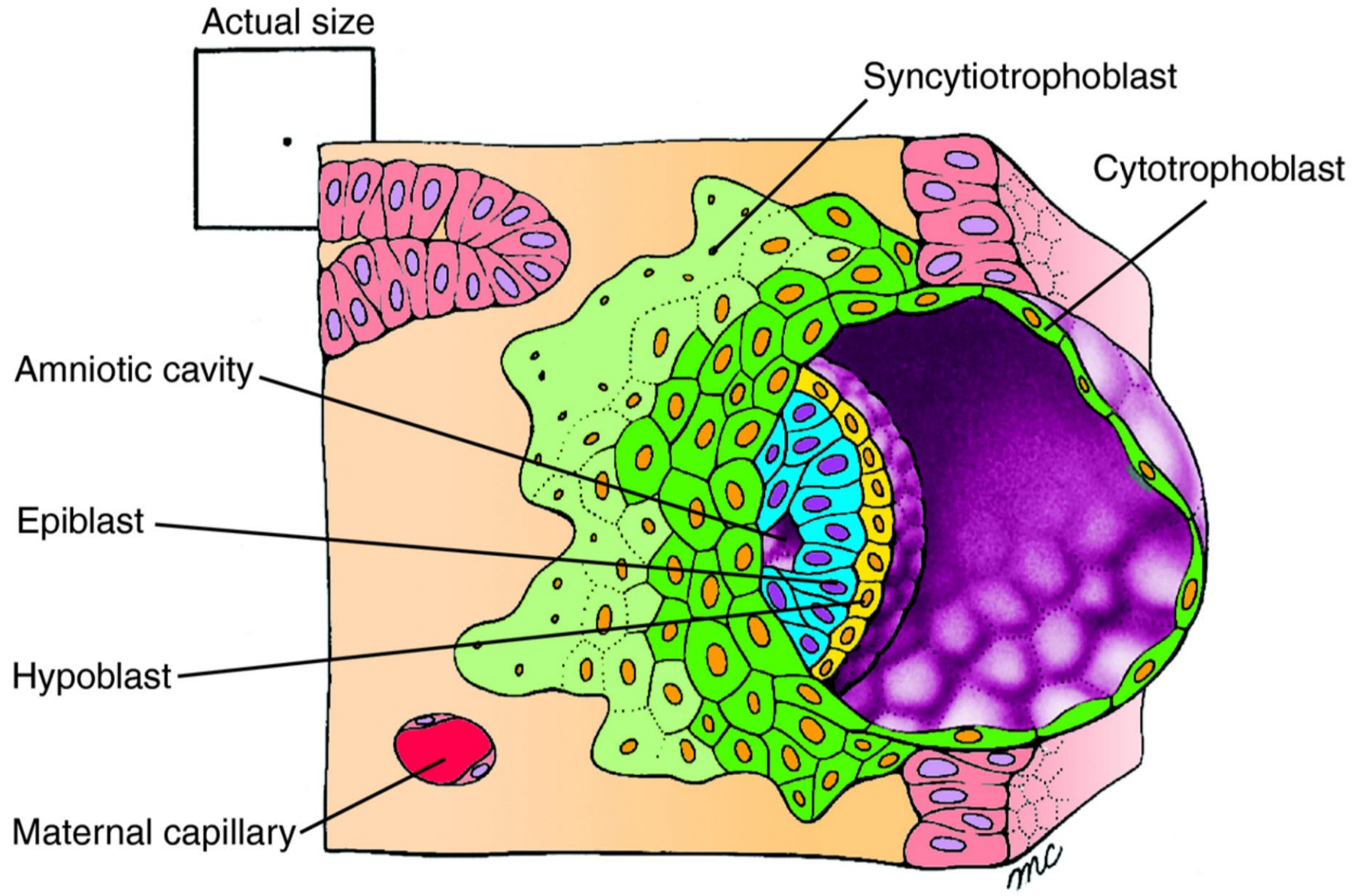




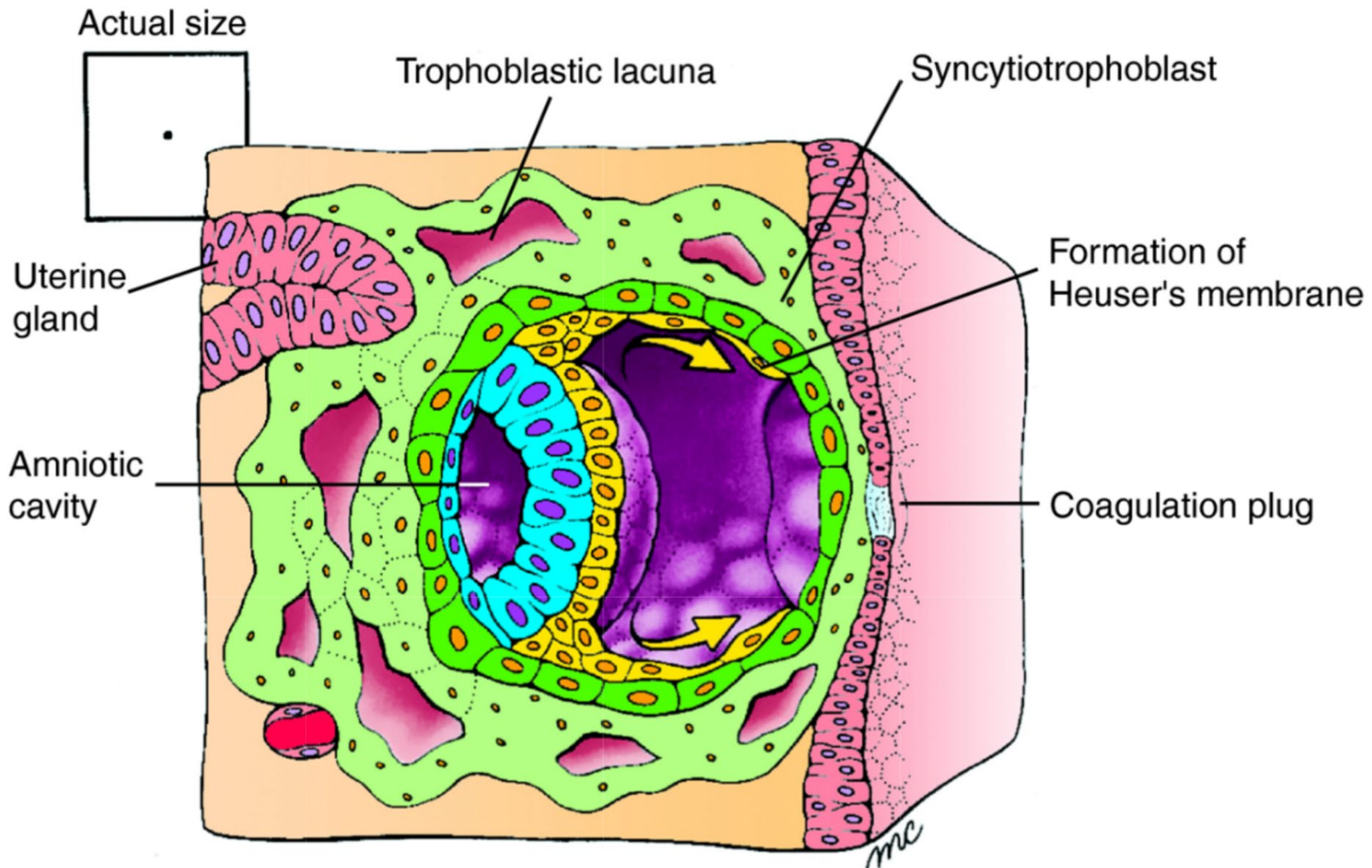








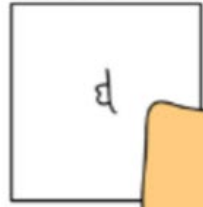8 days



9 days



Actual size



Primary yolk sac

Heuser's membrane

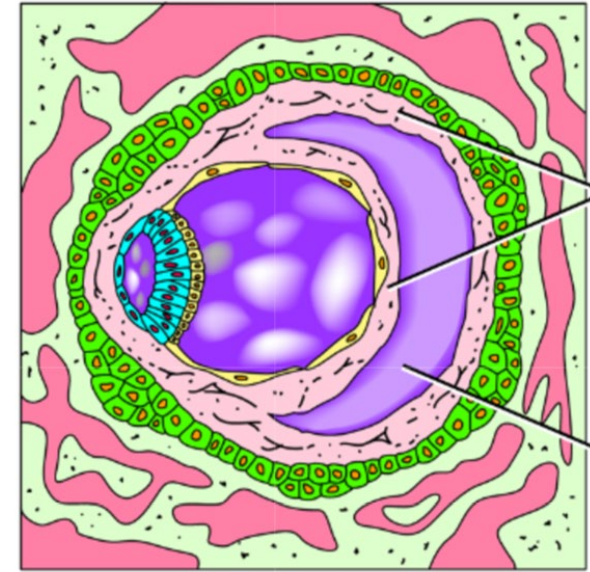
Amniotic cavity

Cytotrophoblast

Extraembryonic mesoderm

A

10-11 days



Extraembryonic mesoderm

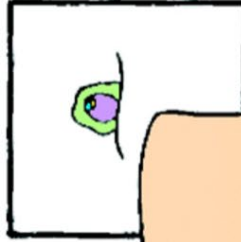
Chorionic cavity

C

12-13 days



Actual size



Syncytiotrophoblast

Connecting stalk

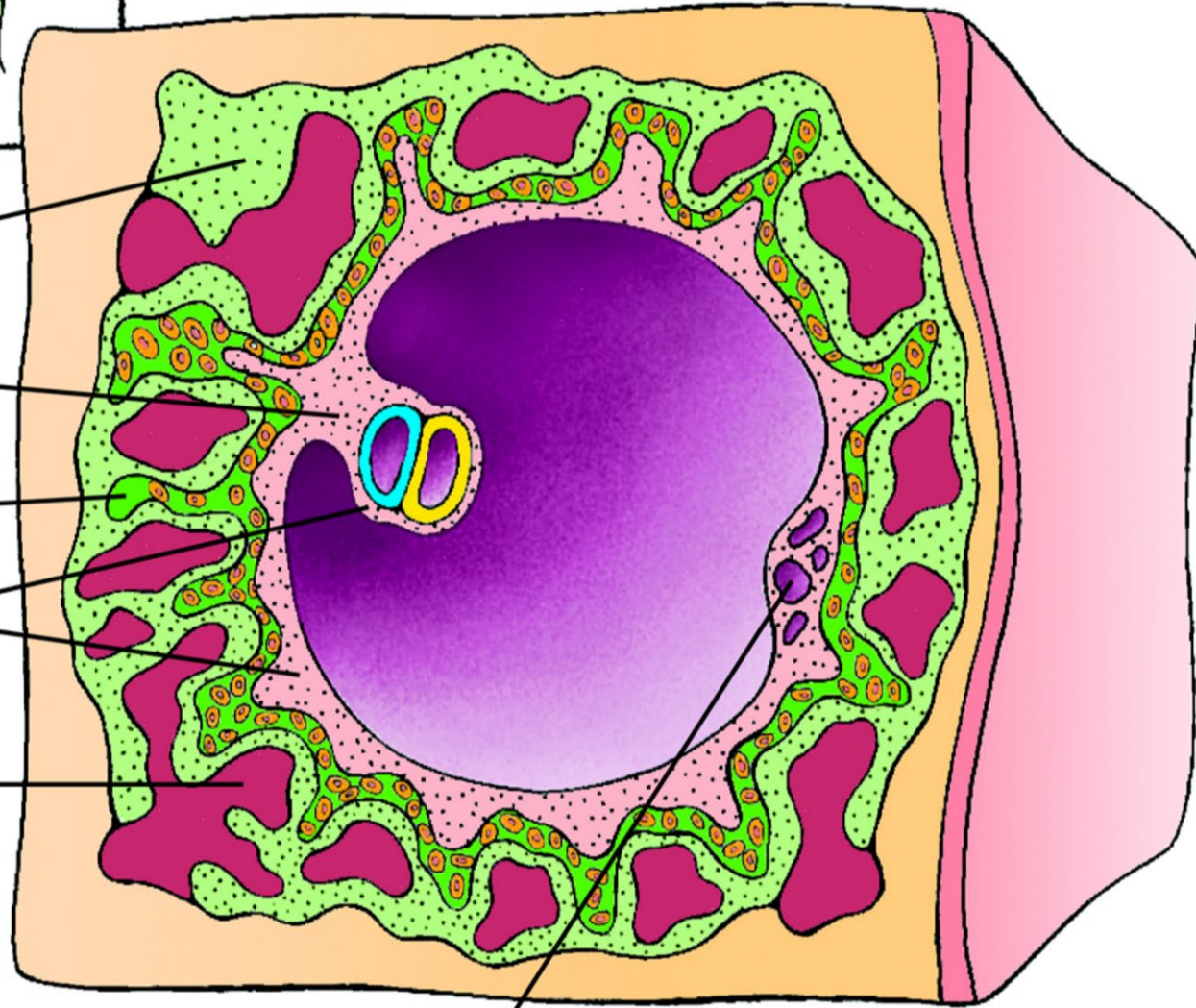
Cytotrophoblast

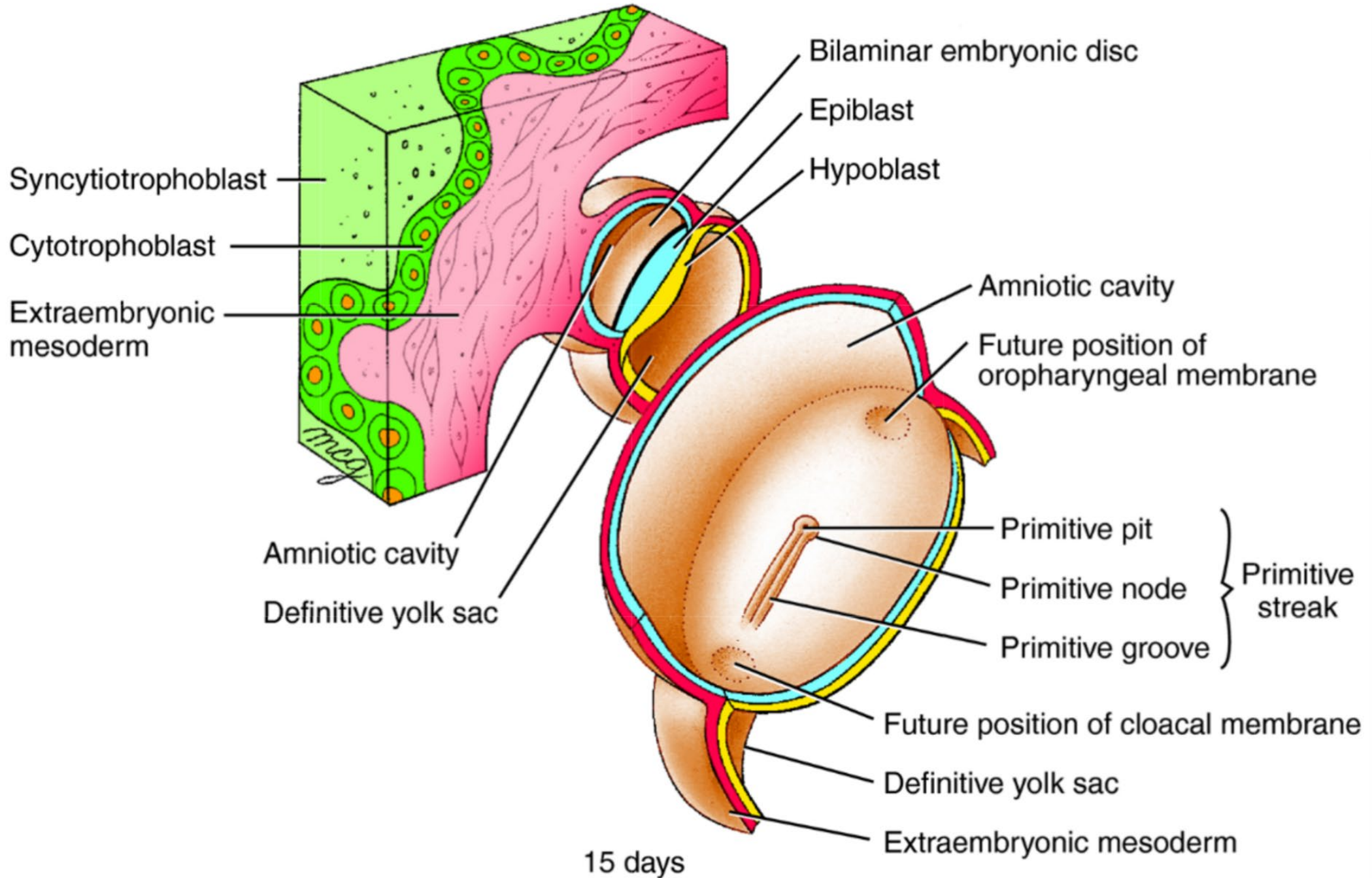
Extraembryonic mesoderm

Trophoblastic lacuna

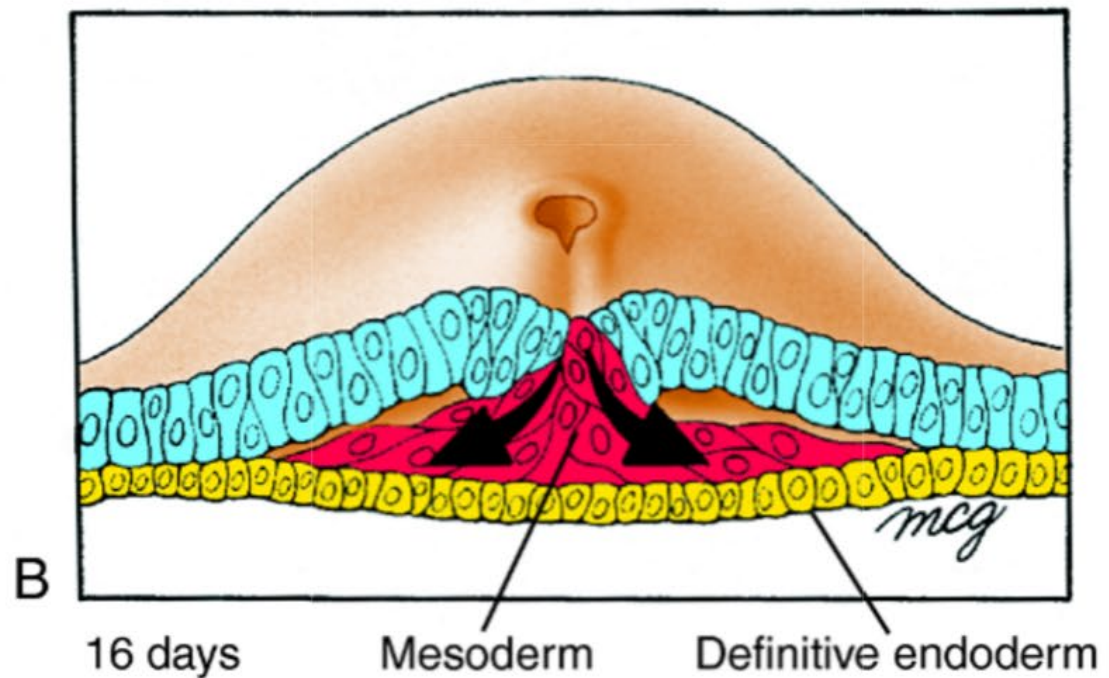
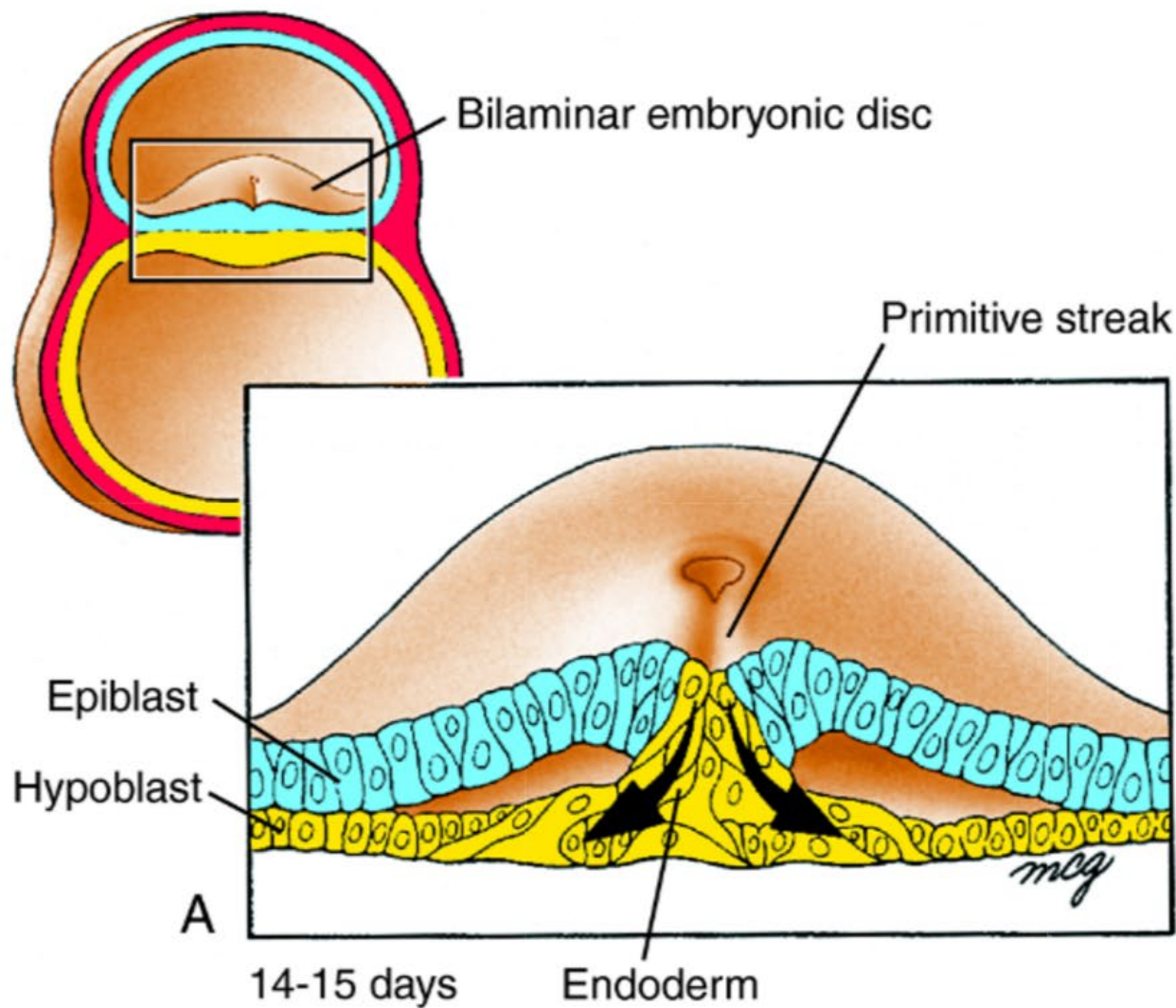
14–15 days

Remnants of primary yolk sac

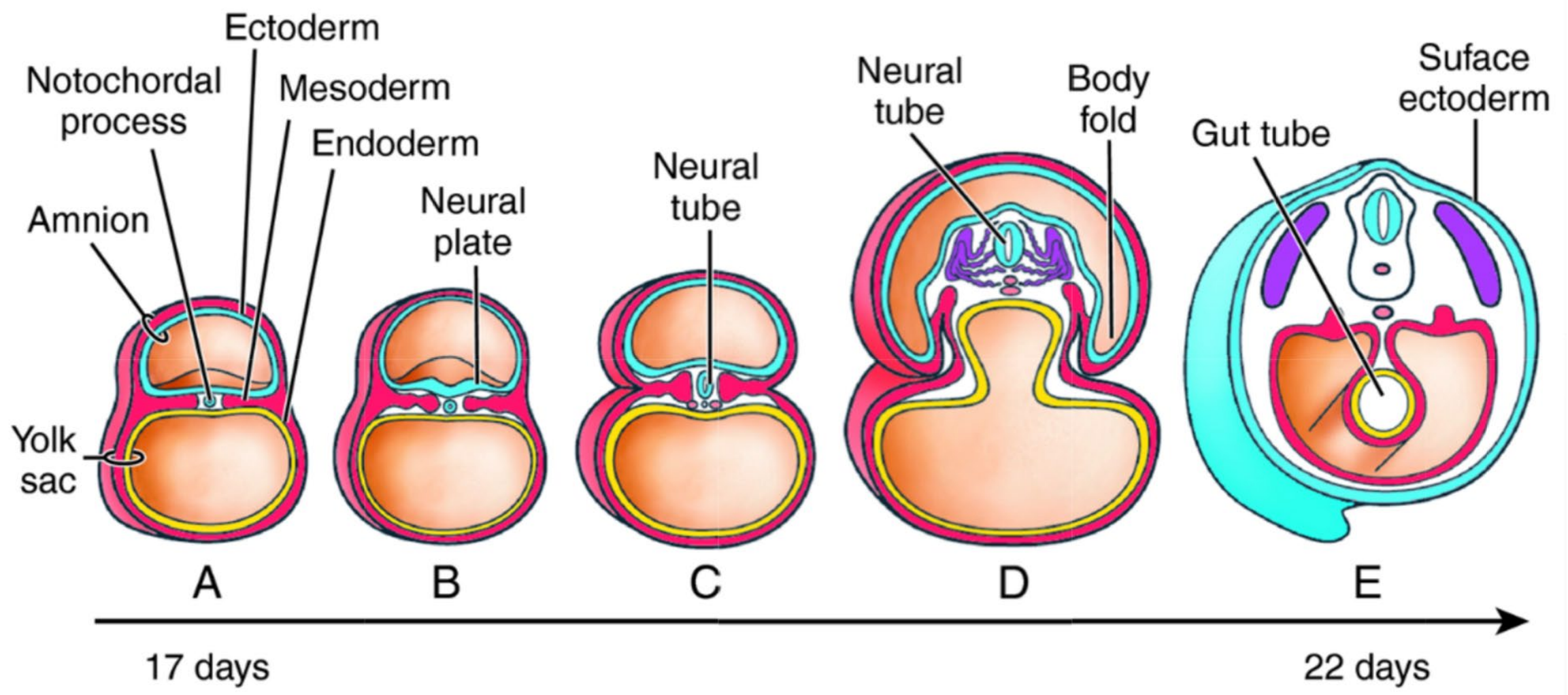




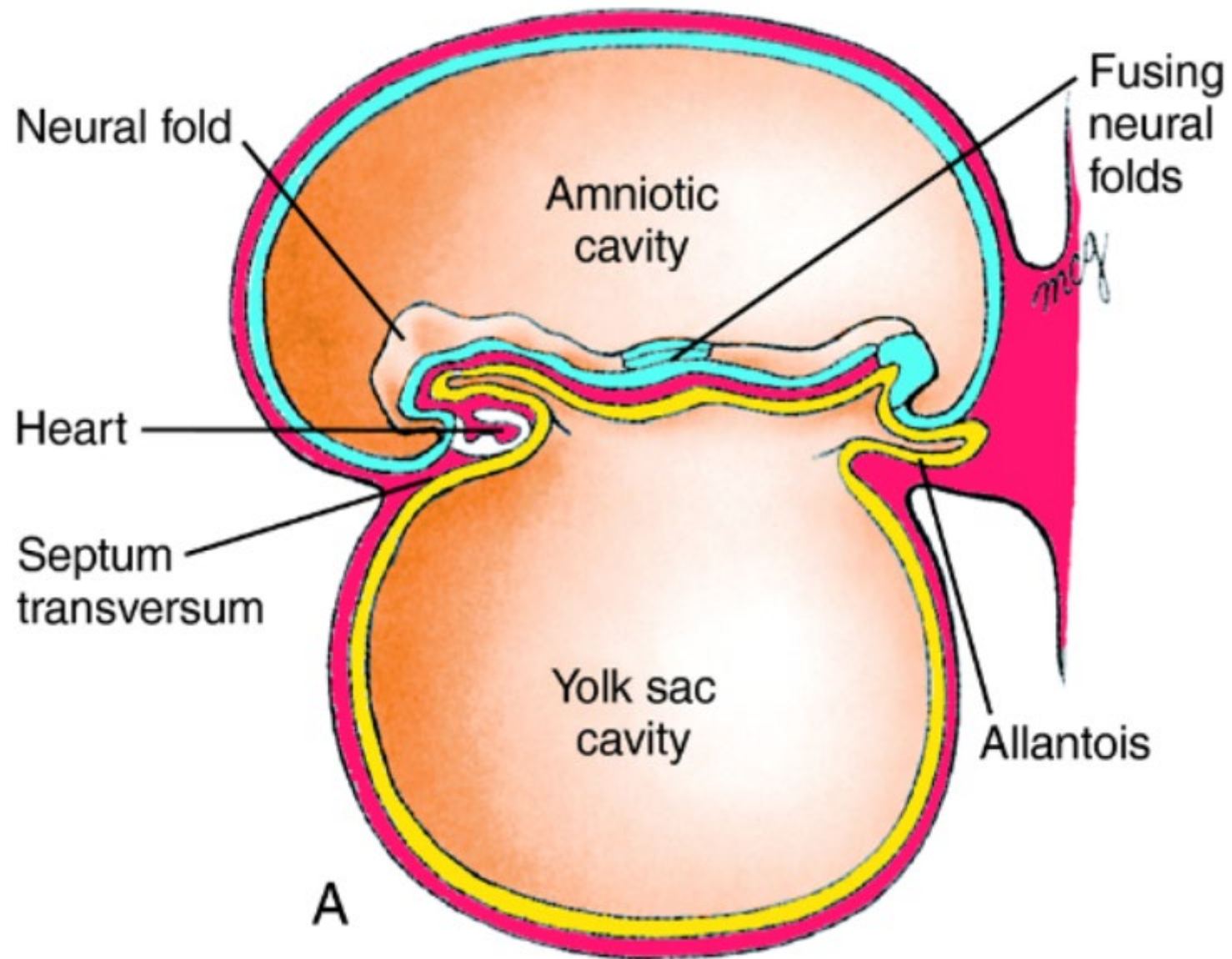




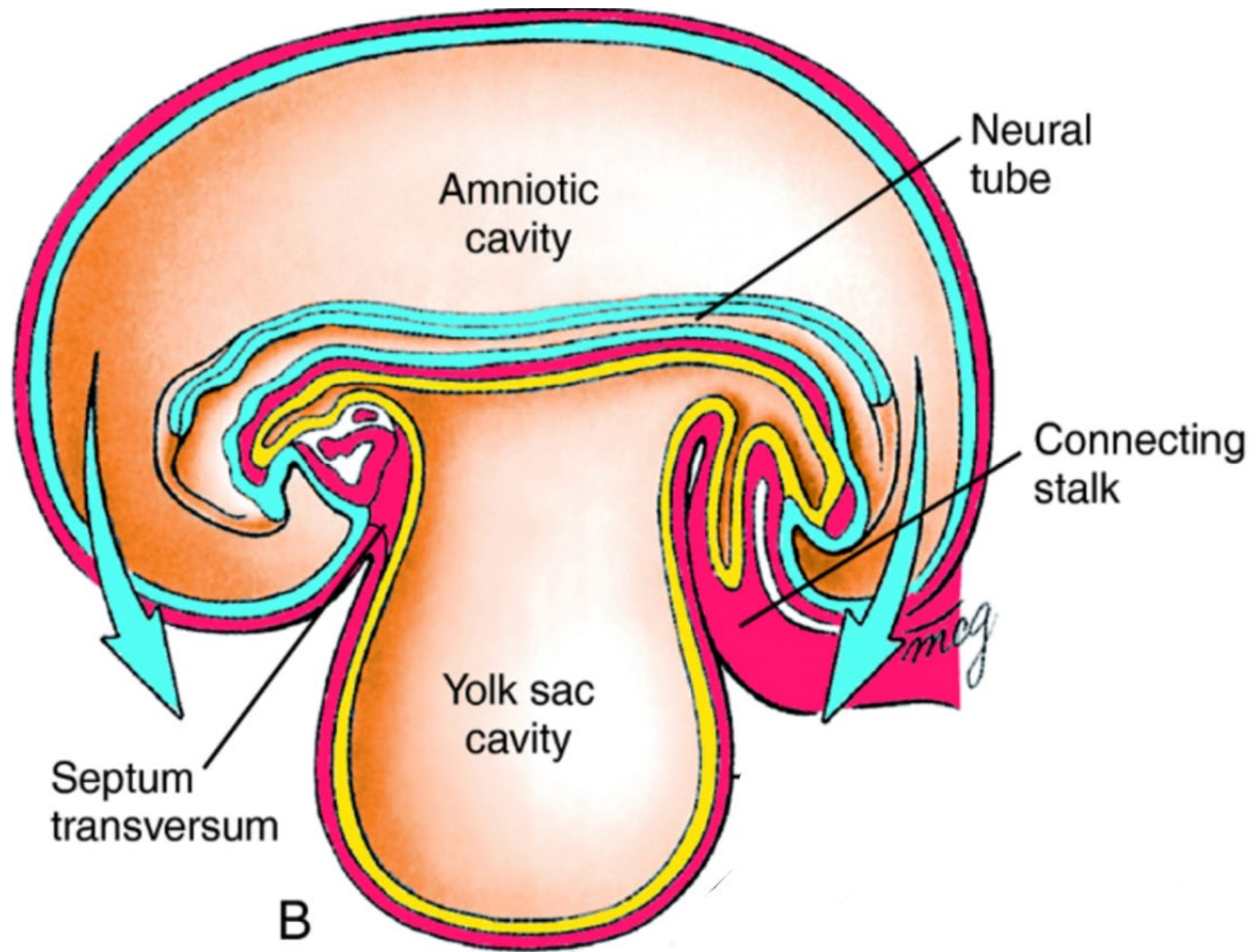


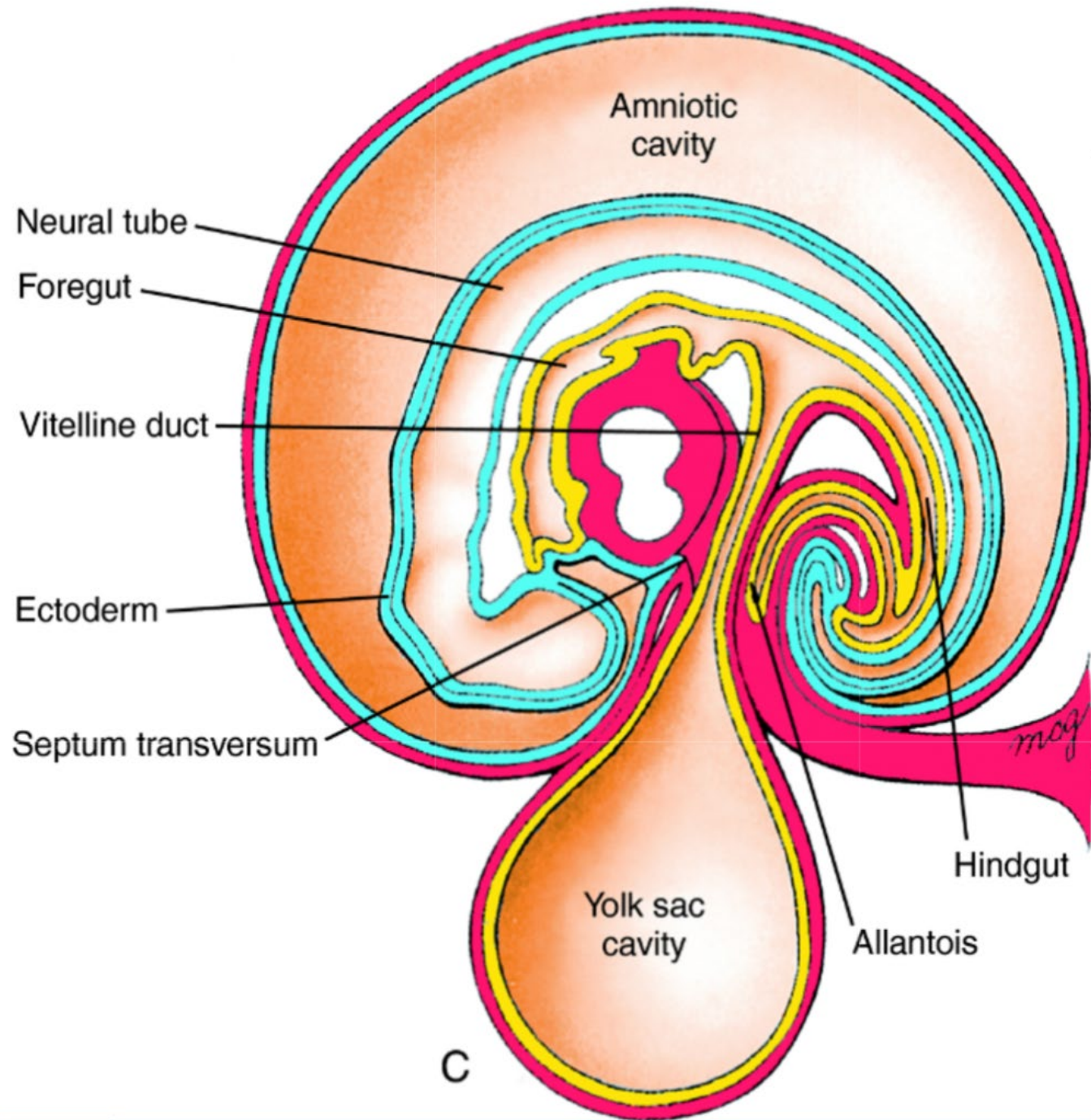






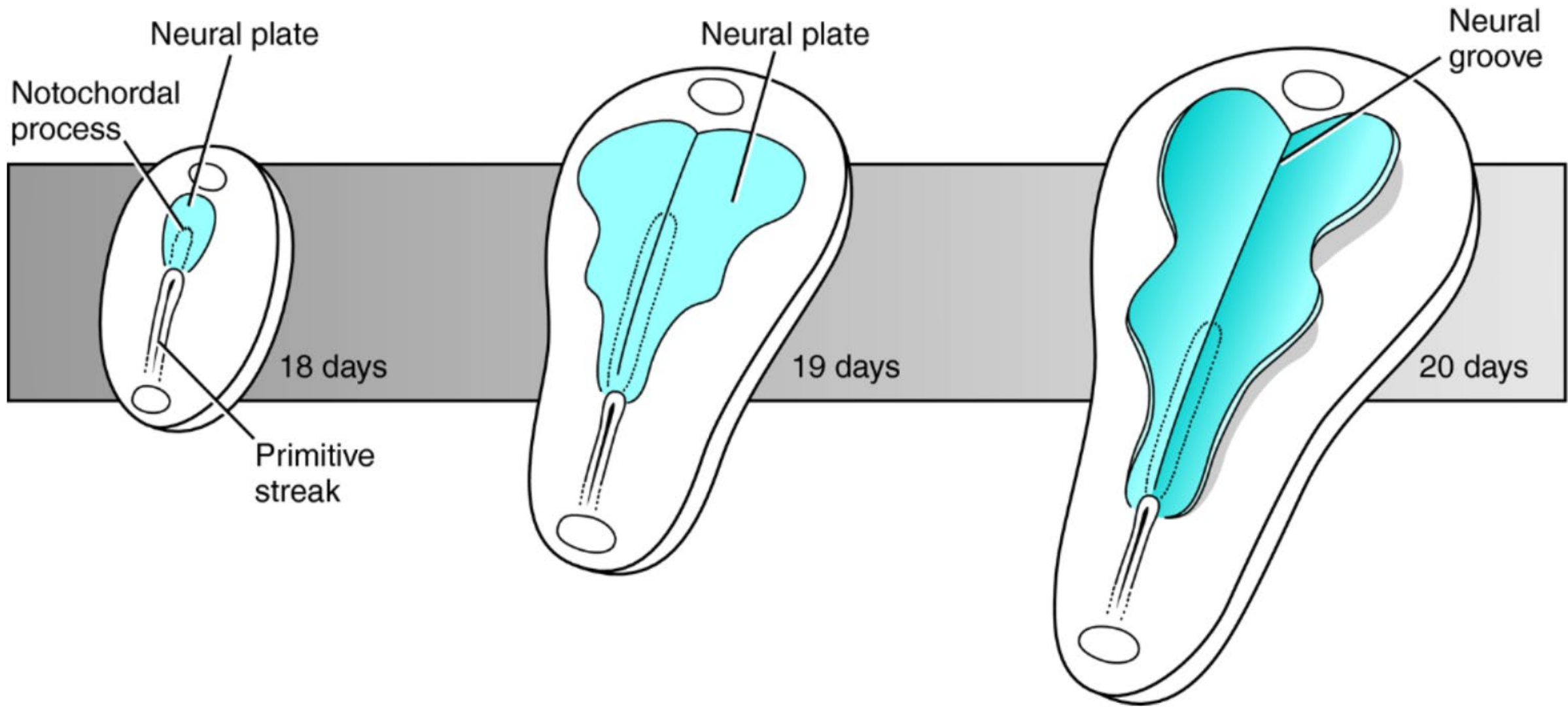




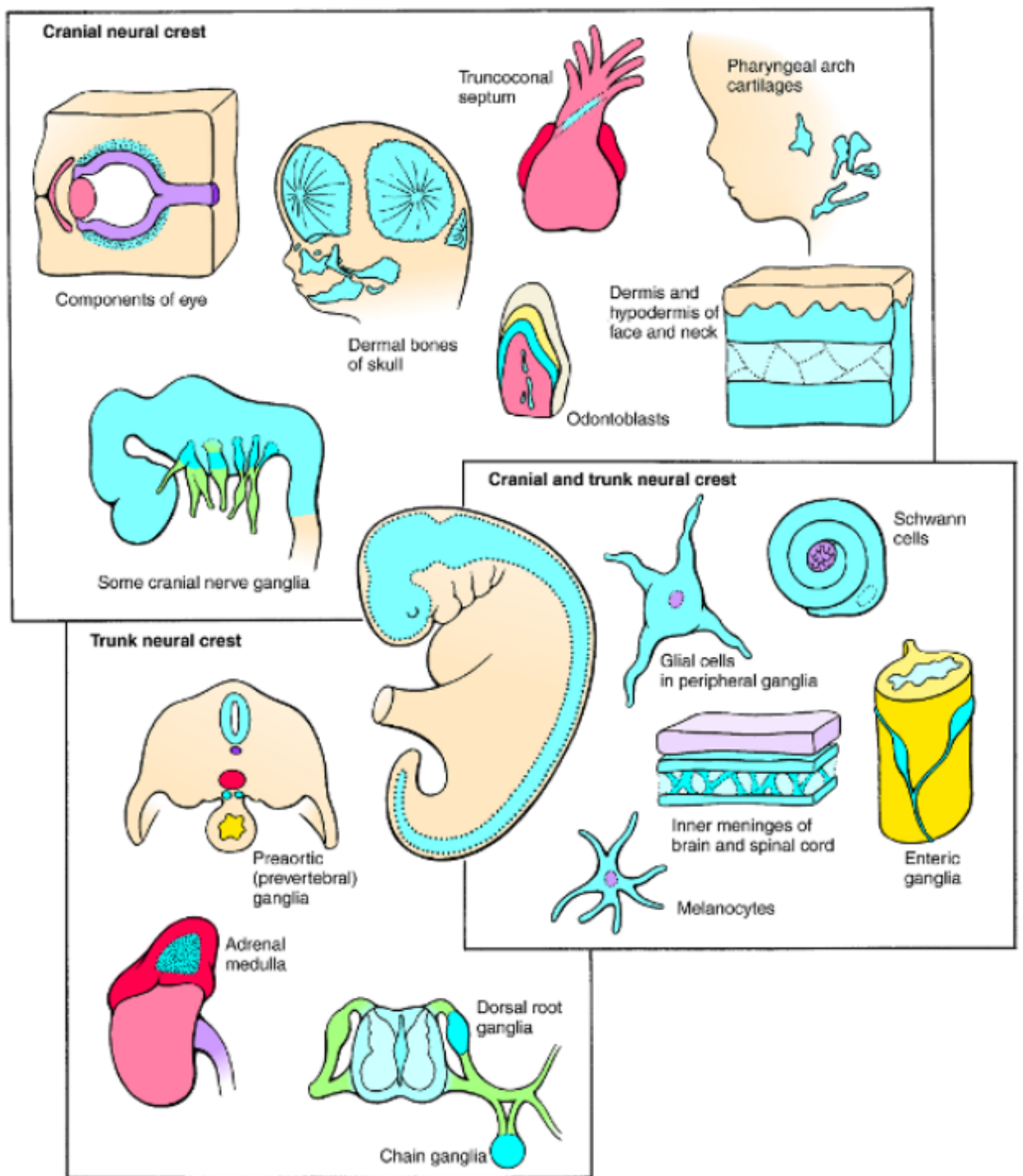
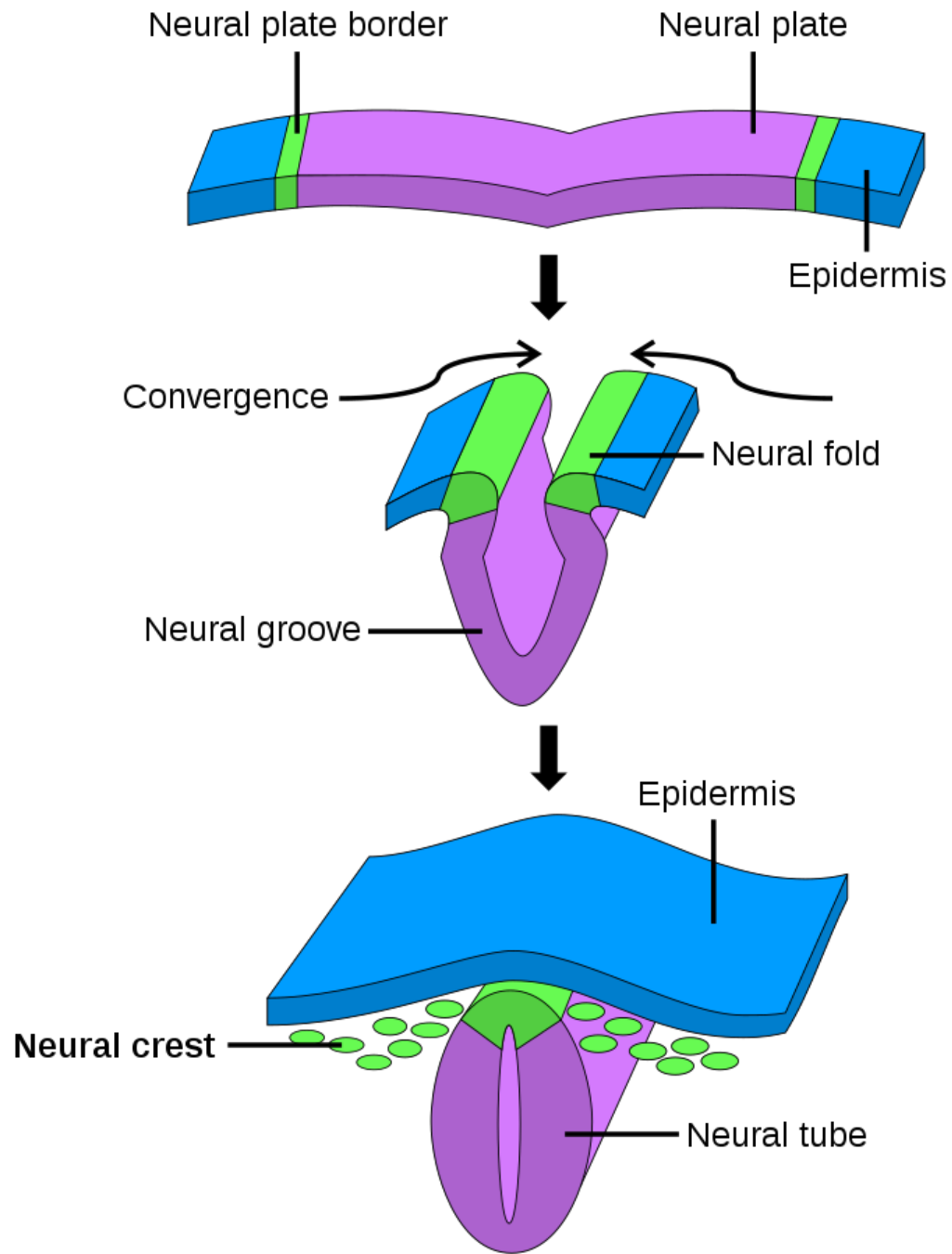


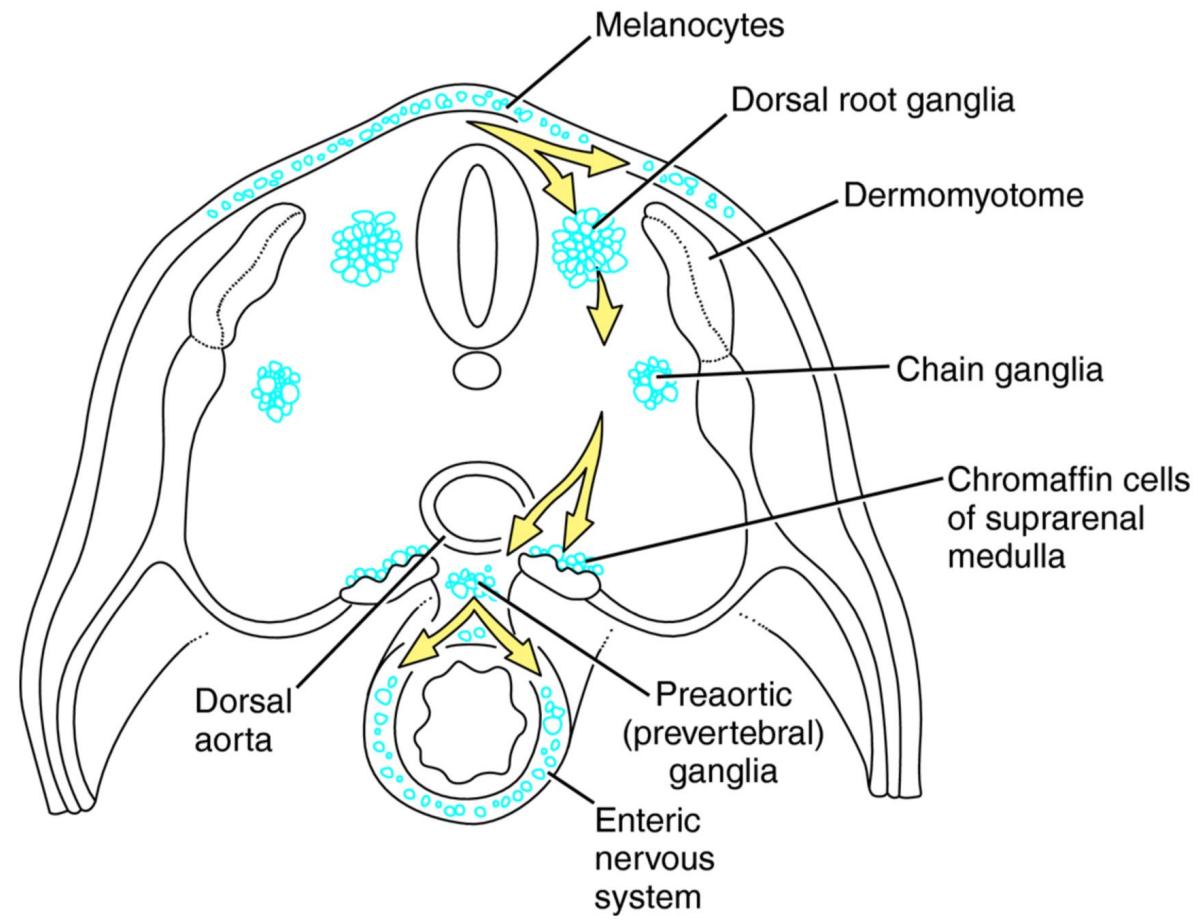
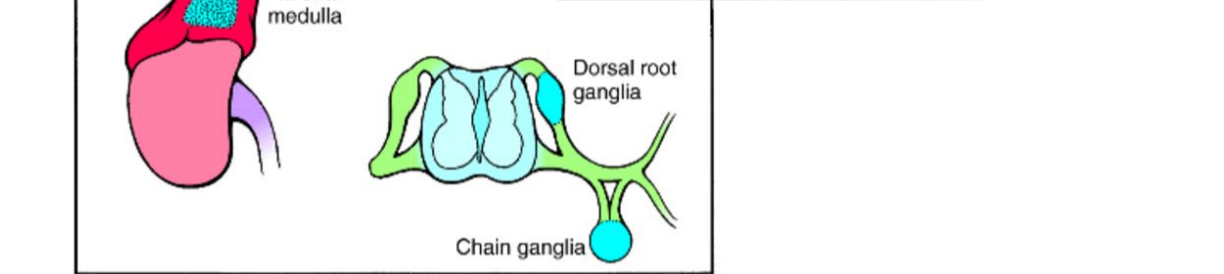
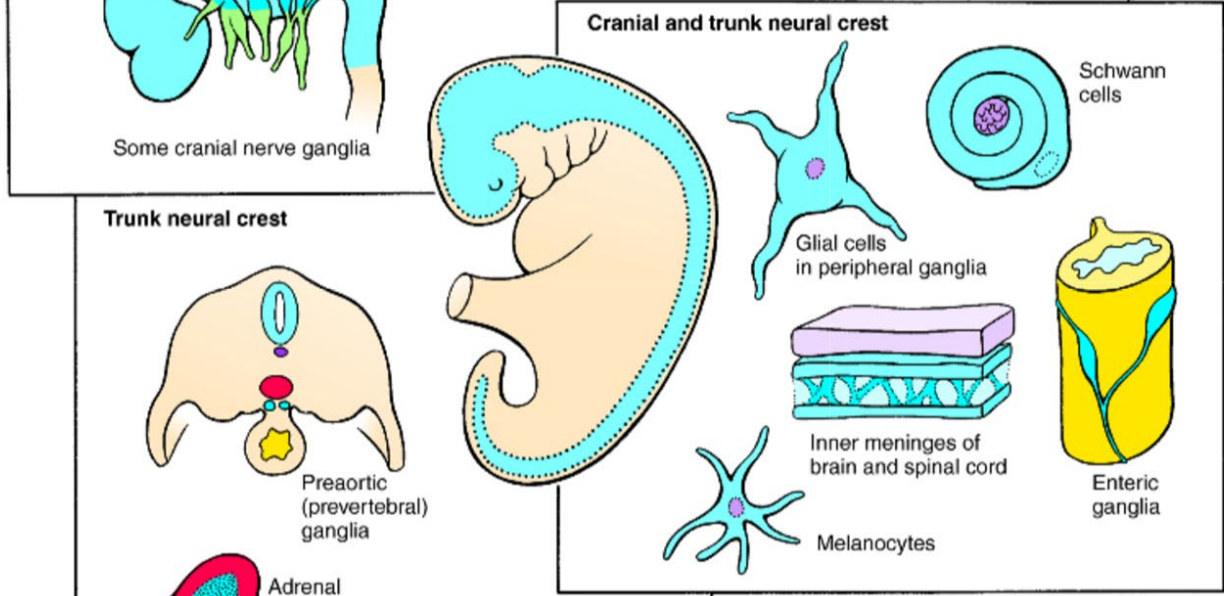
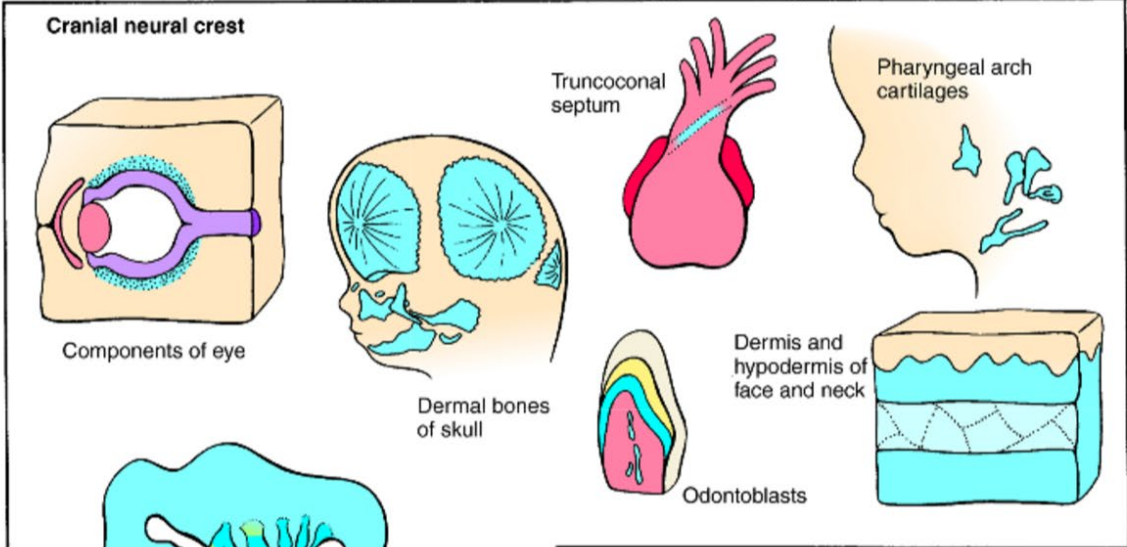
# Overview

1. Early embryonic development
2. **Central nervous system development**
3. Endodermal tube formation and derivatives
4. Urogenital system development
5. Branchial cleft derivatives
6. Cardiac and vasculature development

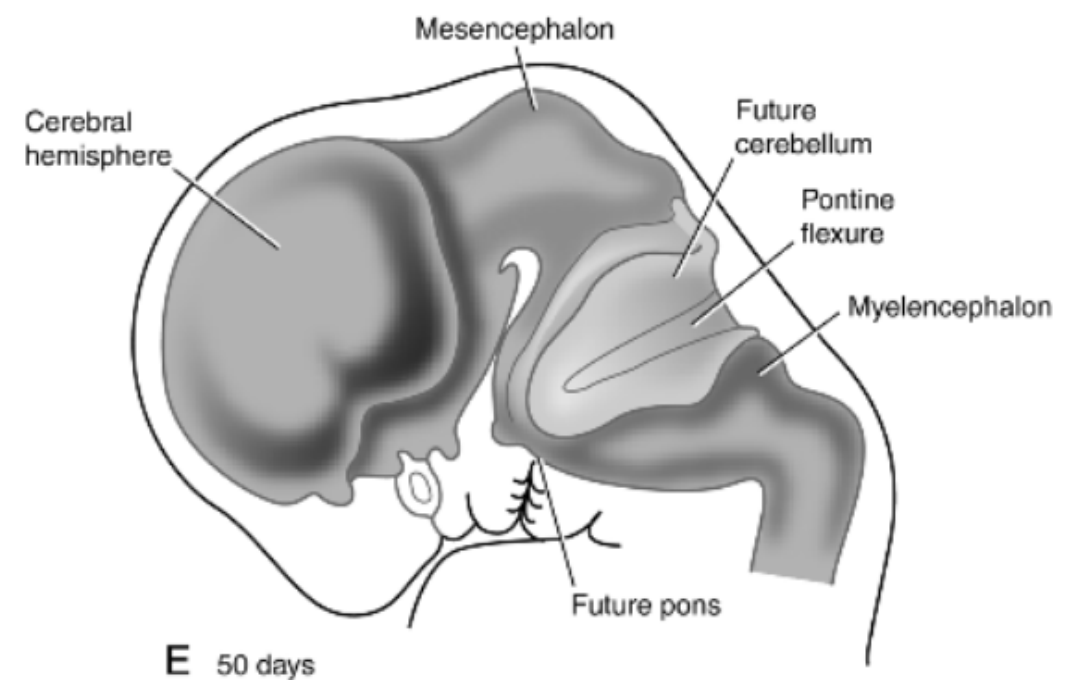
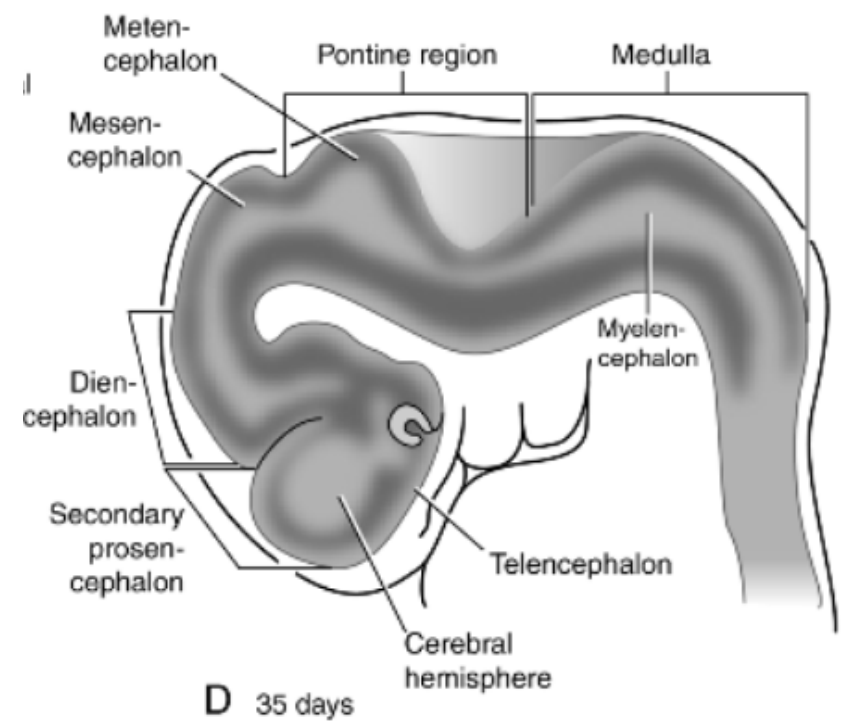
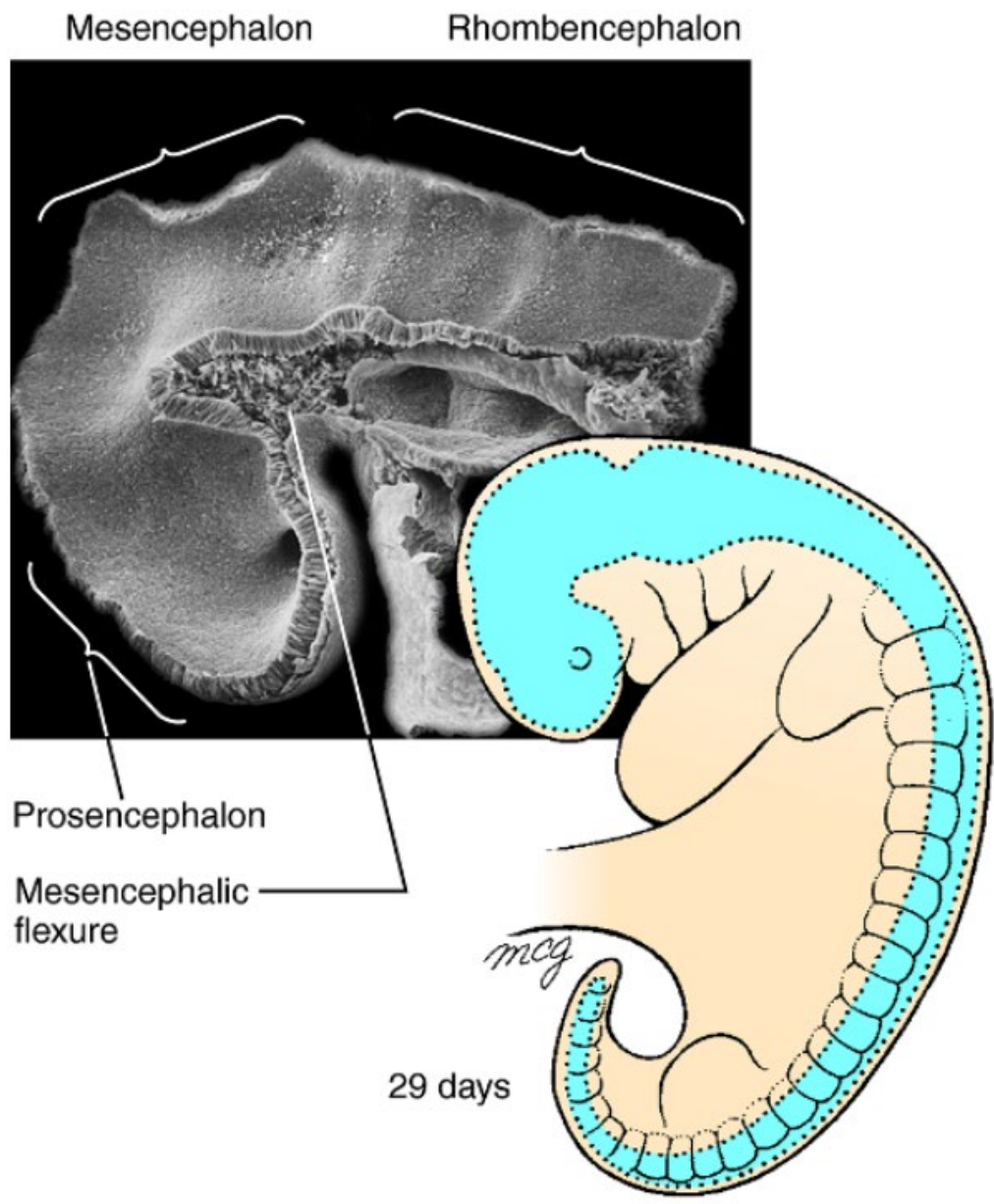






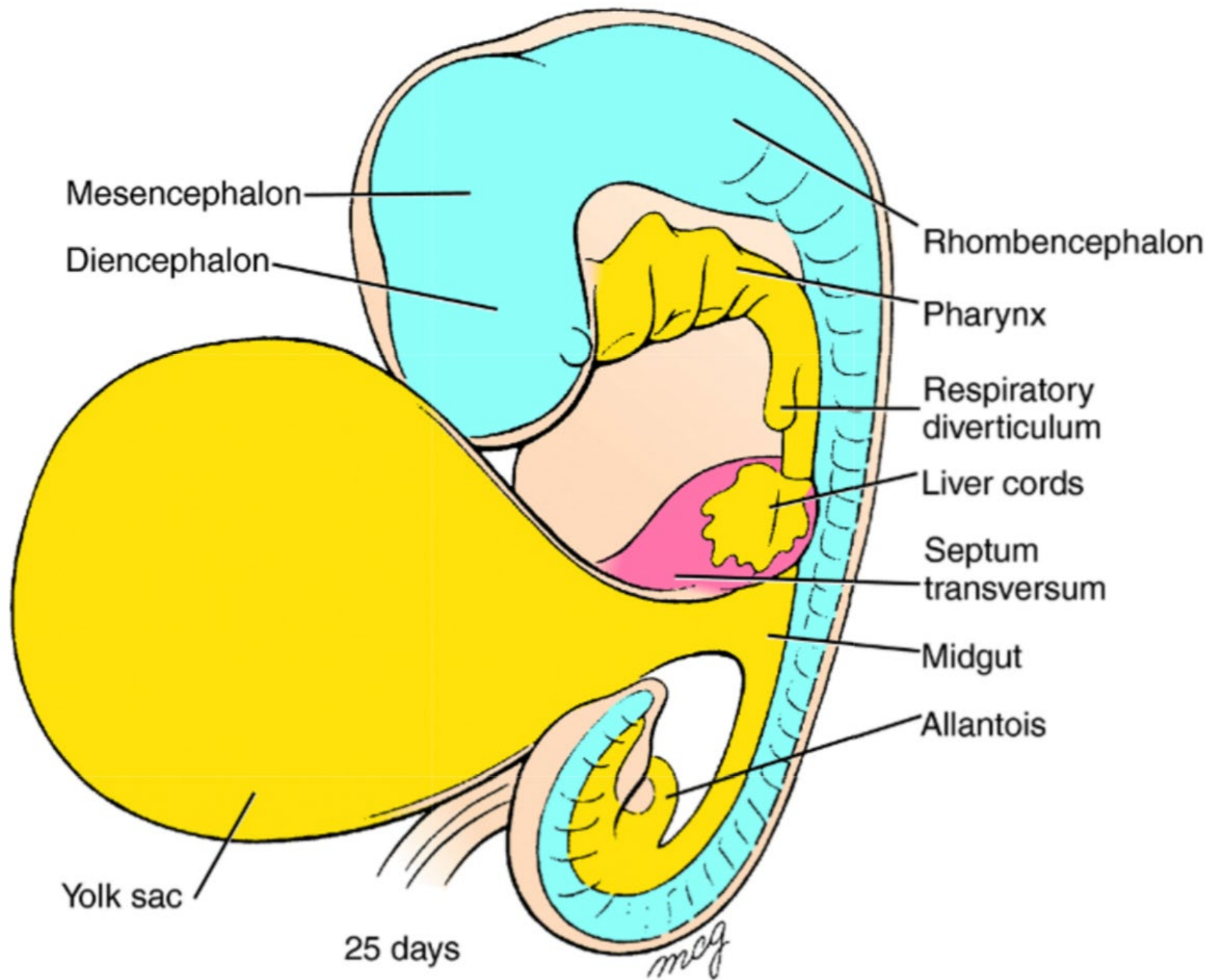


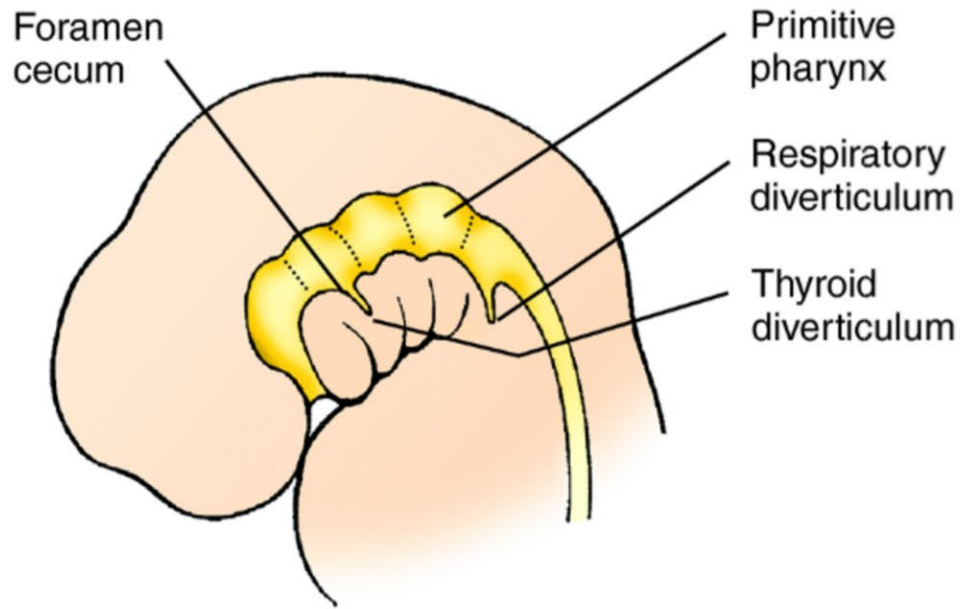




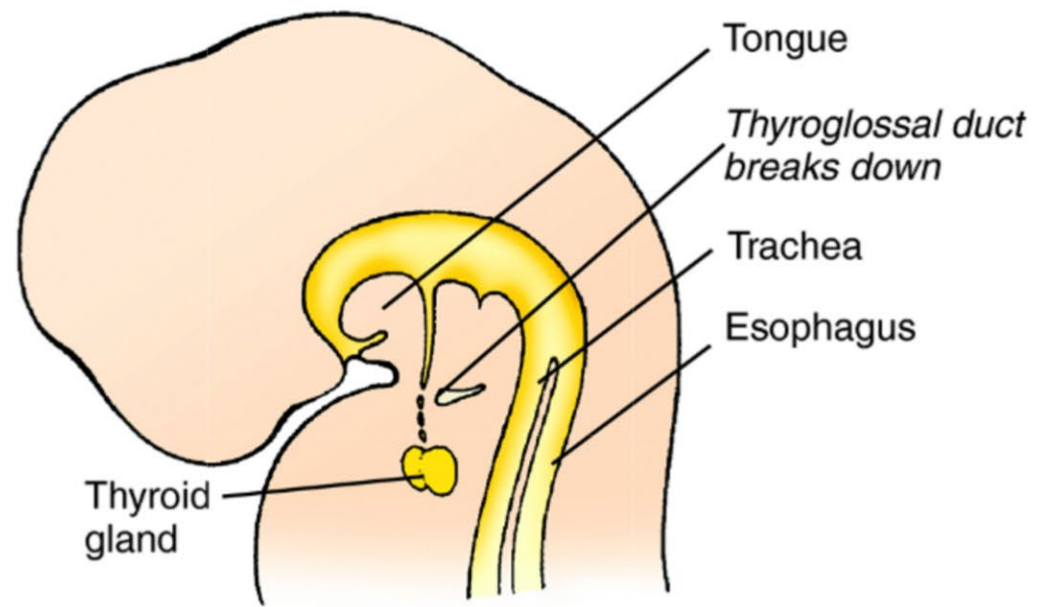
# Overview

1. Early embryonic development
2. Central nervous system development
3. **Endodermal tube formation and derivatives**
4. Urogenital system development
5. Branchial cleft derivatives
6. Cardiac and vasculature development

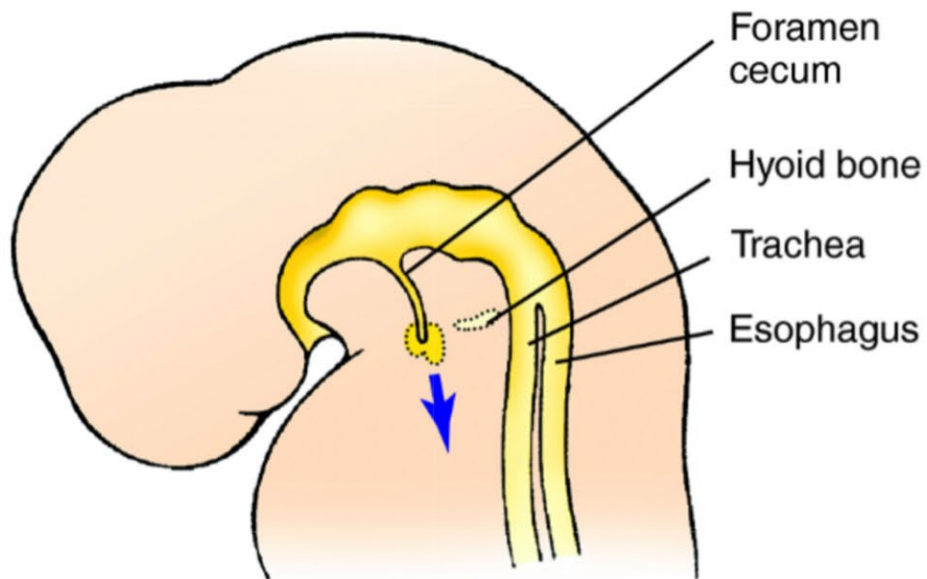




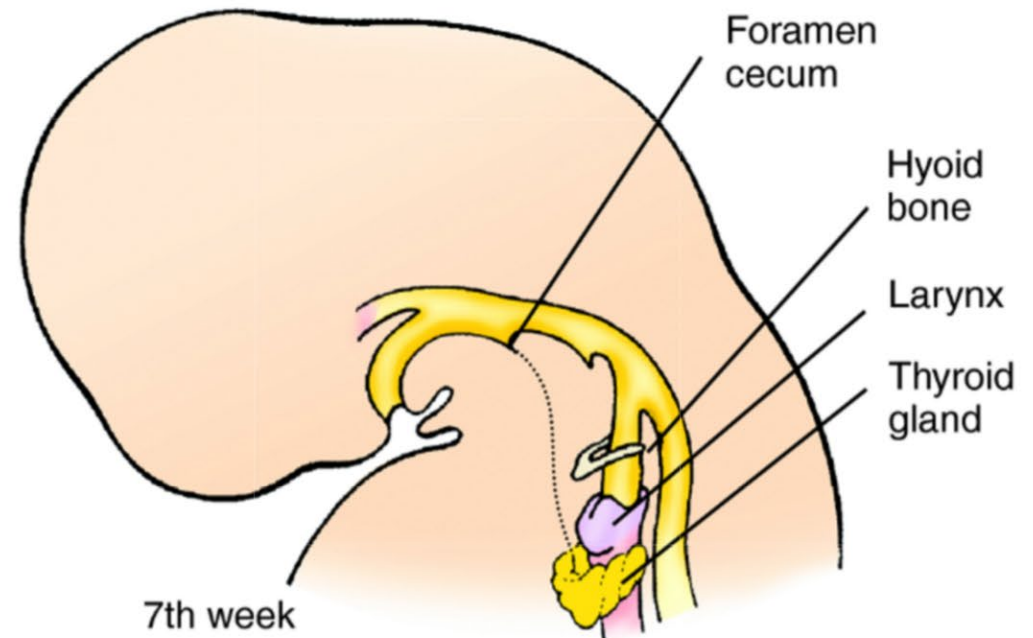
4th week



Late 5th week

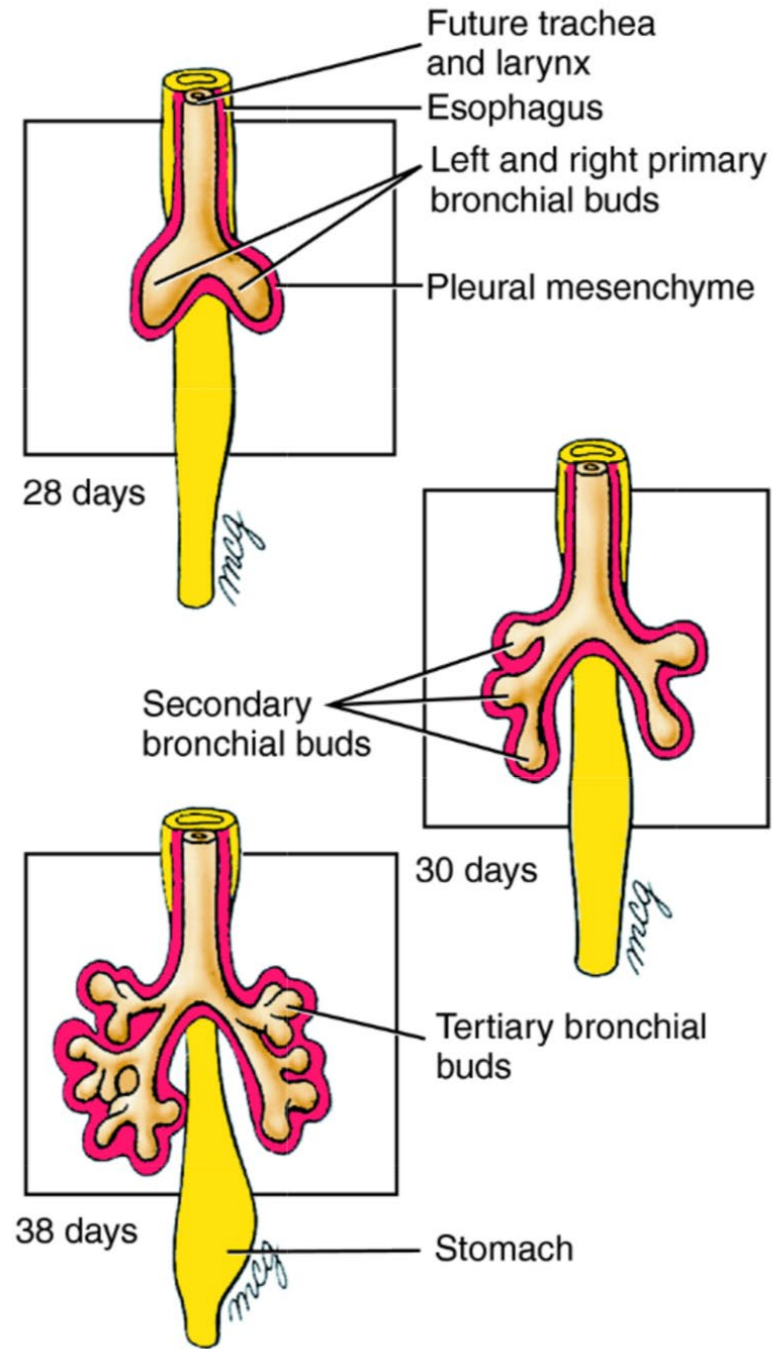
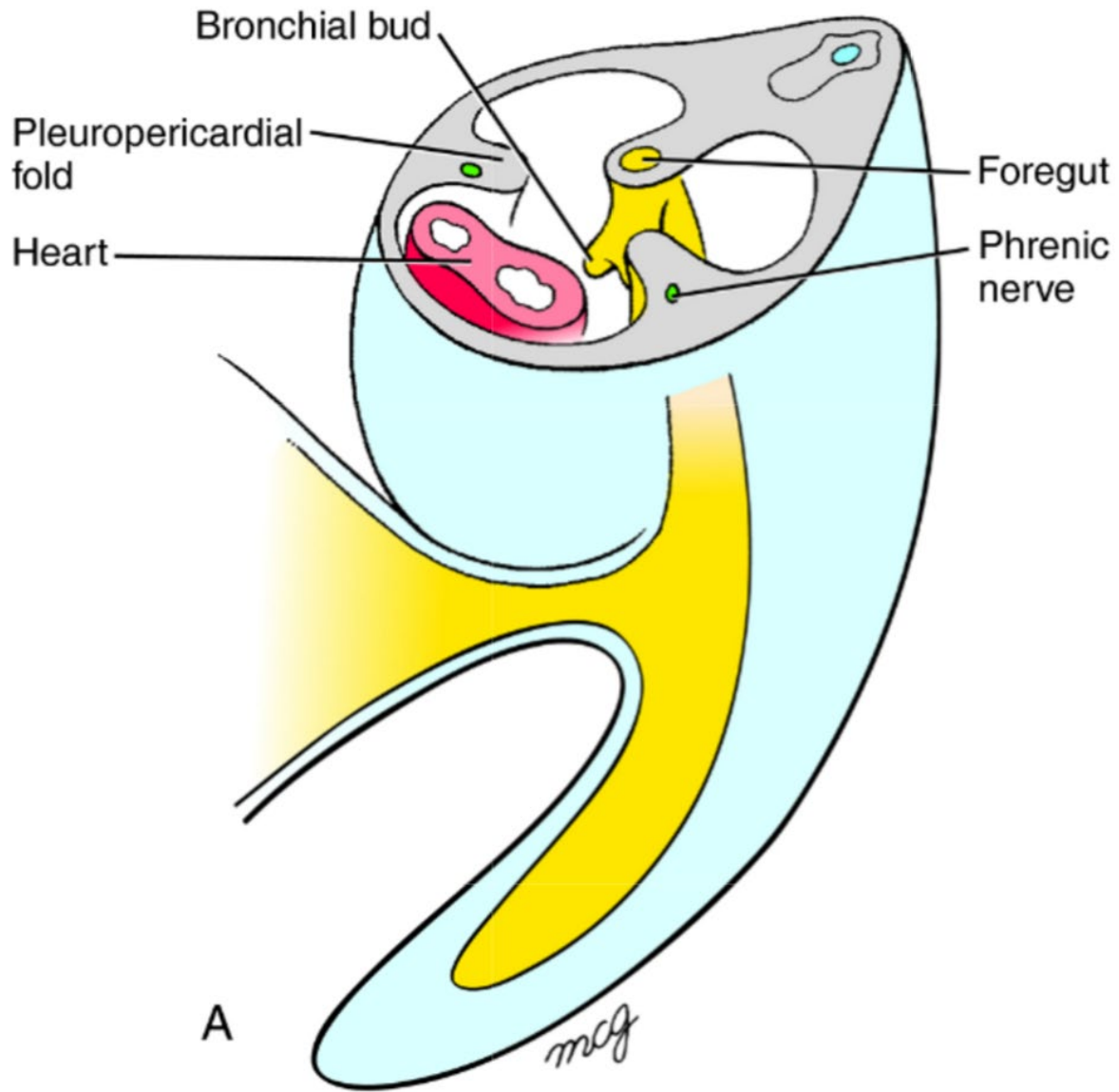


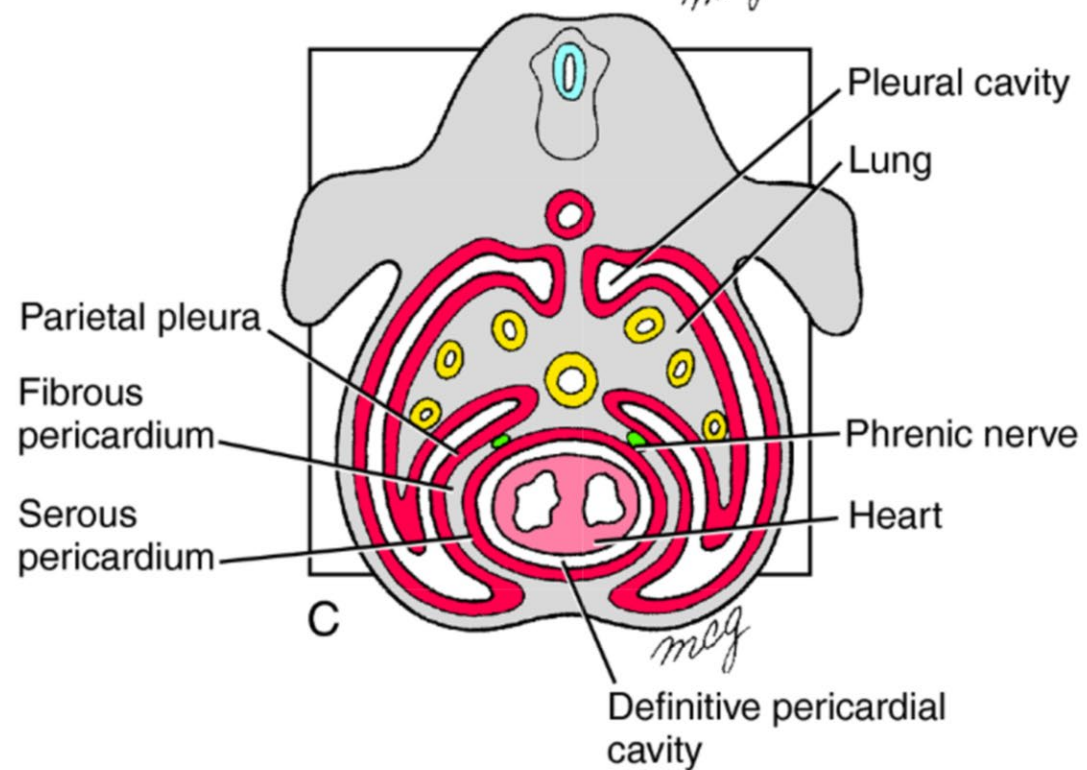
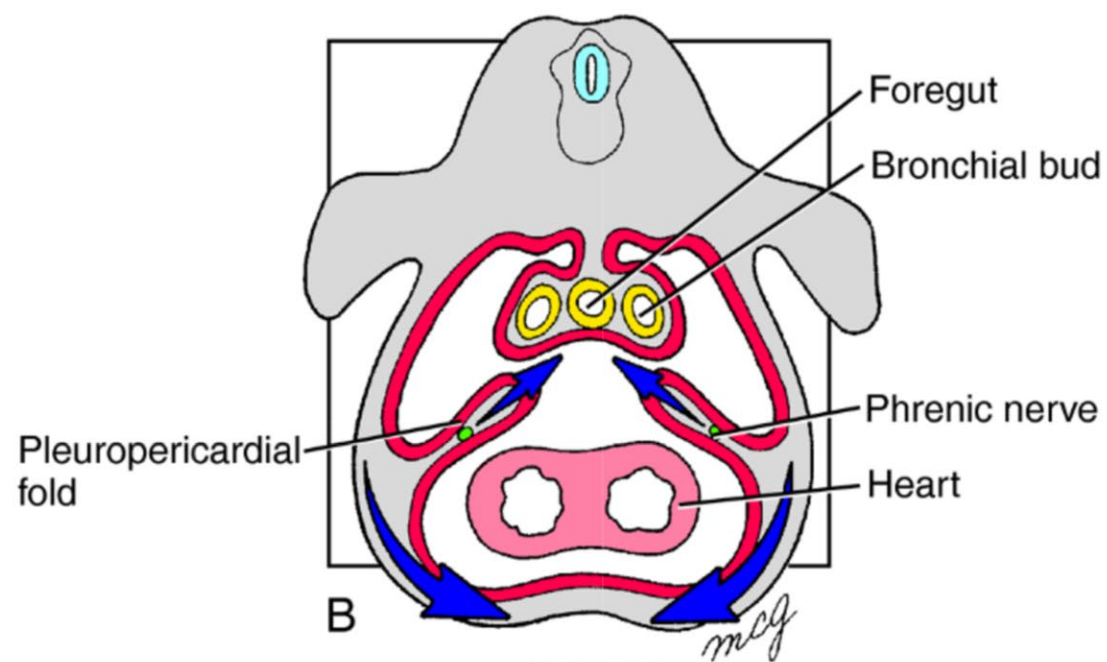
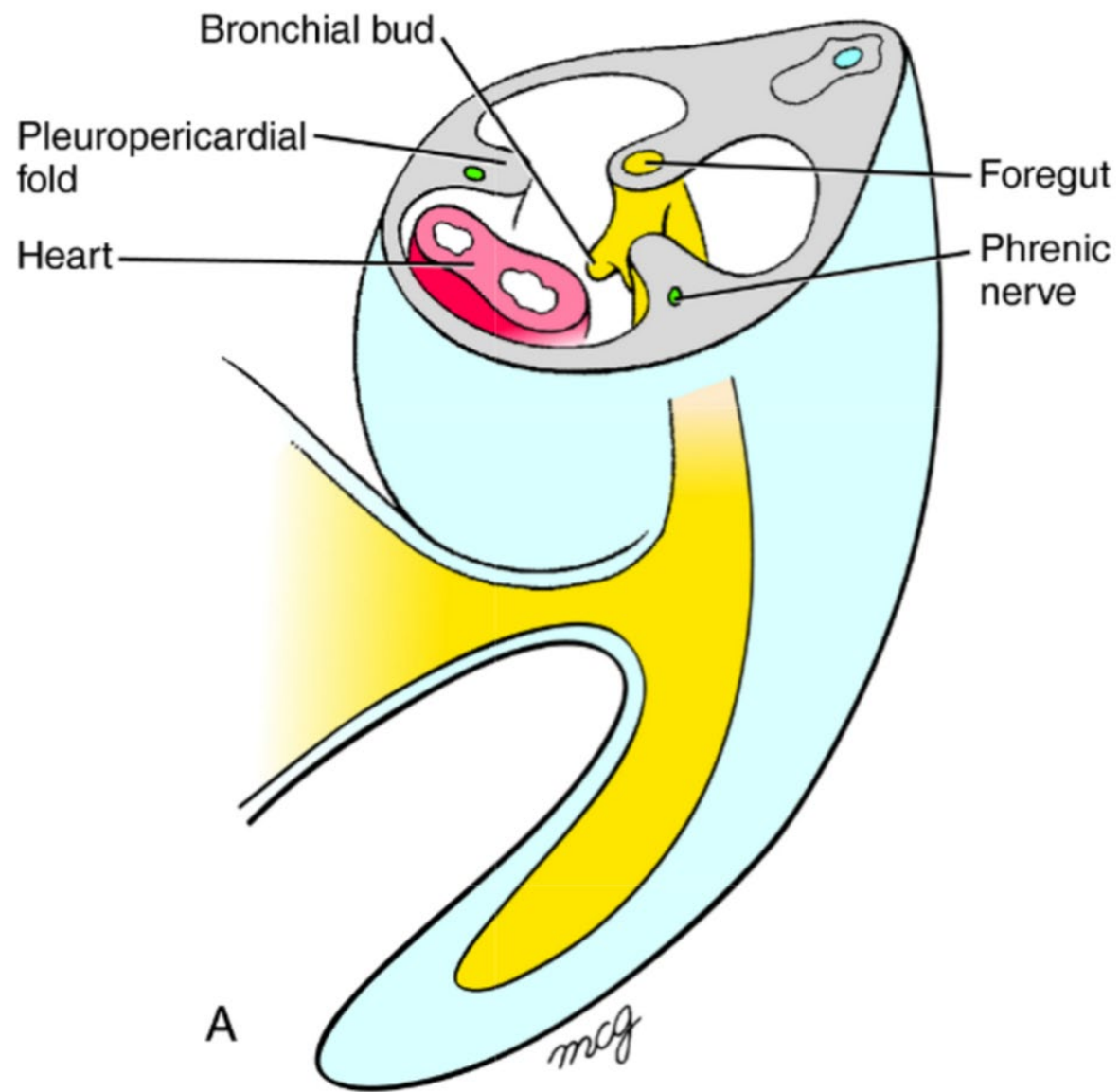
Early 5th week



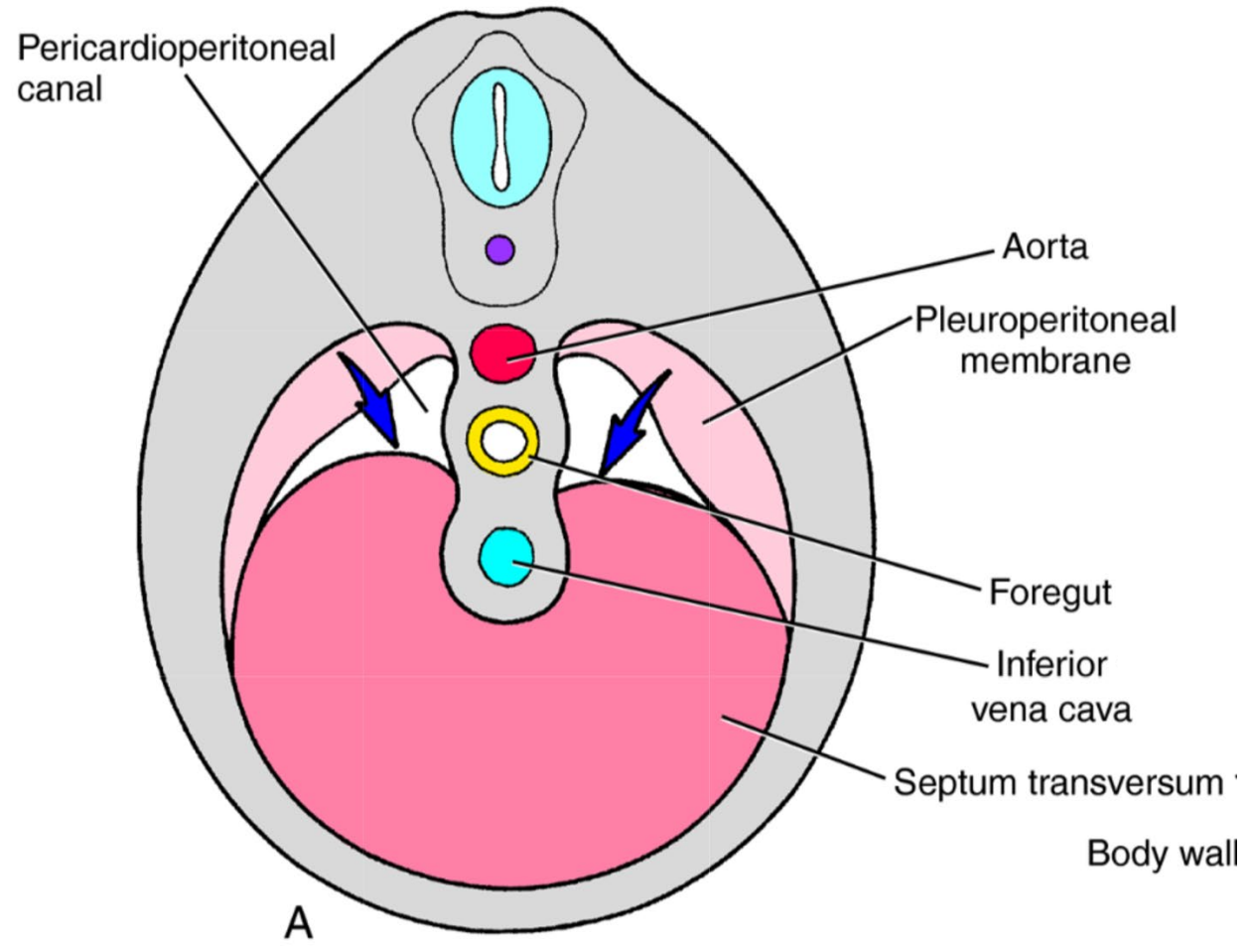
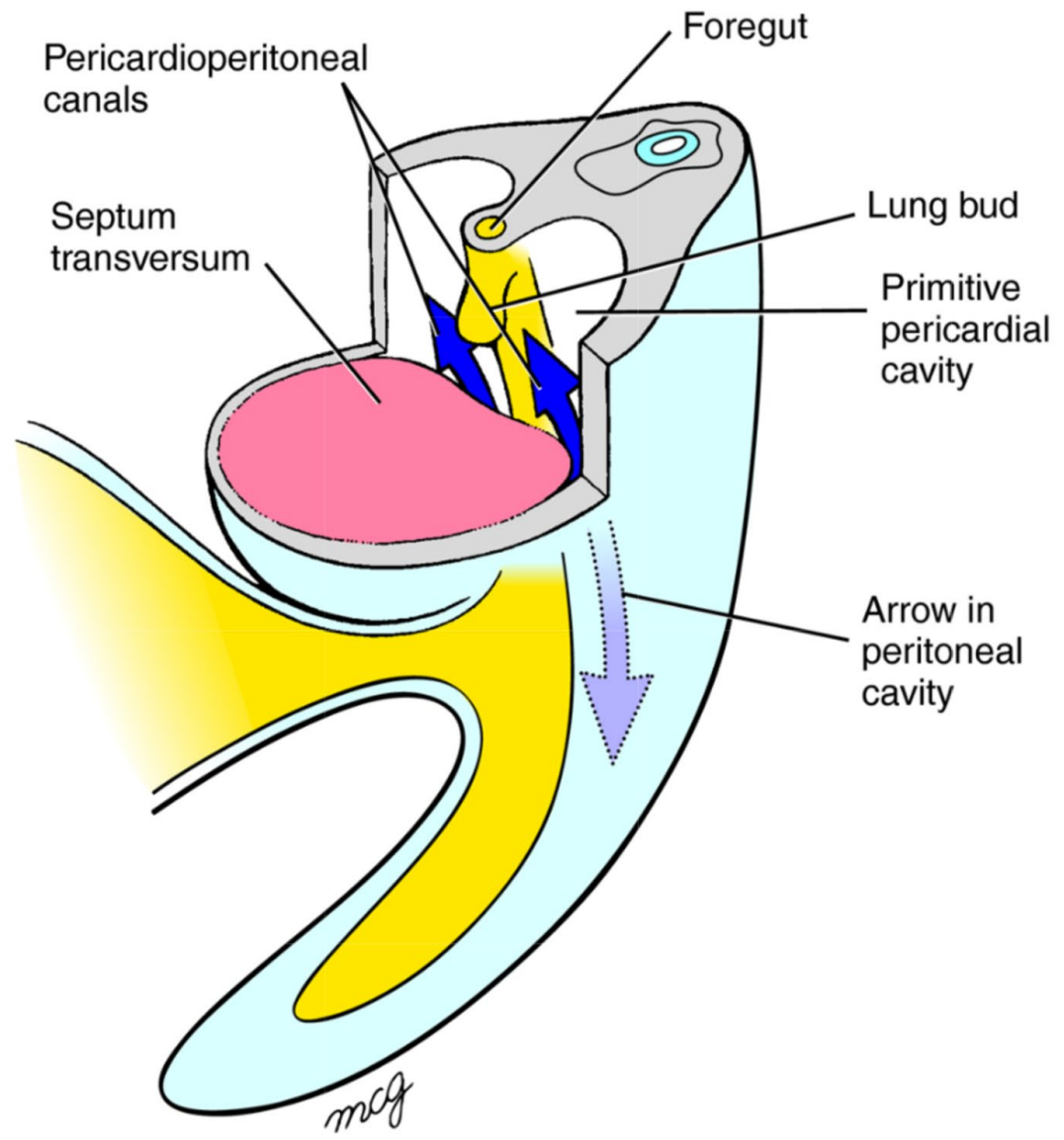
7th week



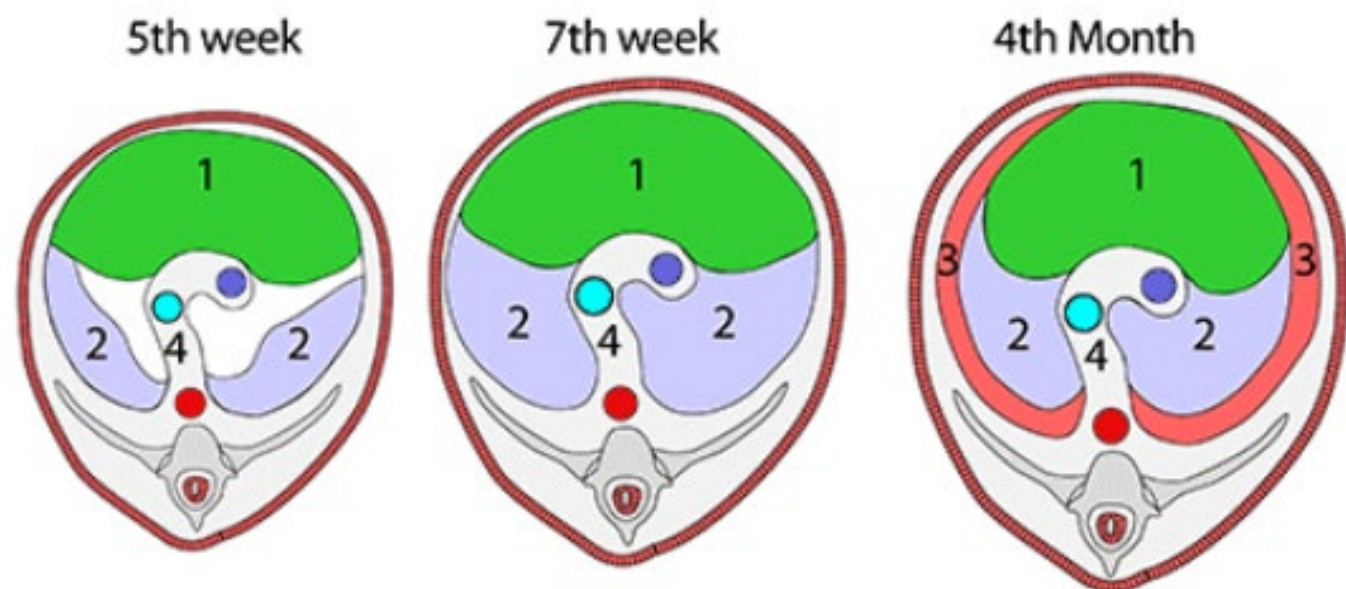








## FORMATION OF THE DIAPHRAGM



Forms from:

1. **Septum transversum**

2. **2 pleuroperitoneal membranes**

3. **Peripheral body wall muscle**

4. **Mesentery of oesophagus**

→ Tendinous part of diaphragm

→ Muscular part of diaphragm

→ Crura of diaphragm

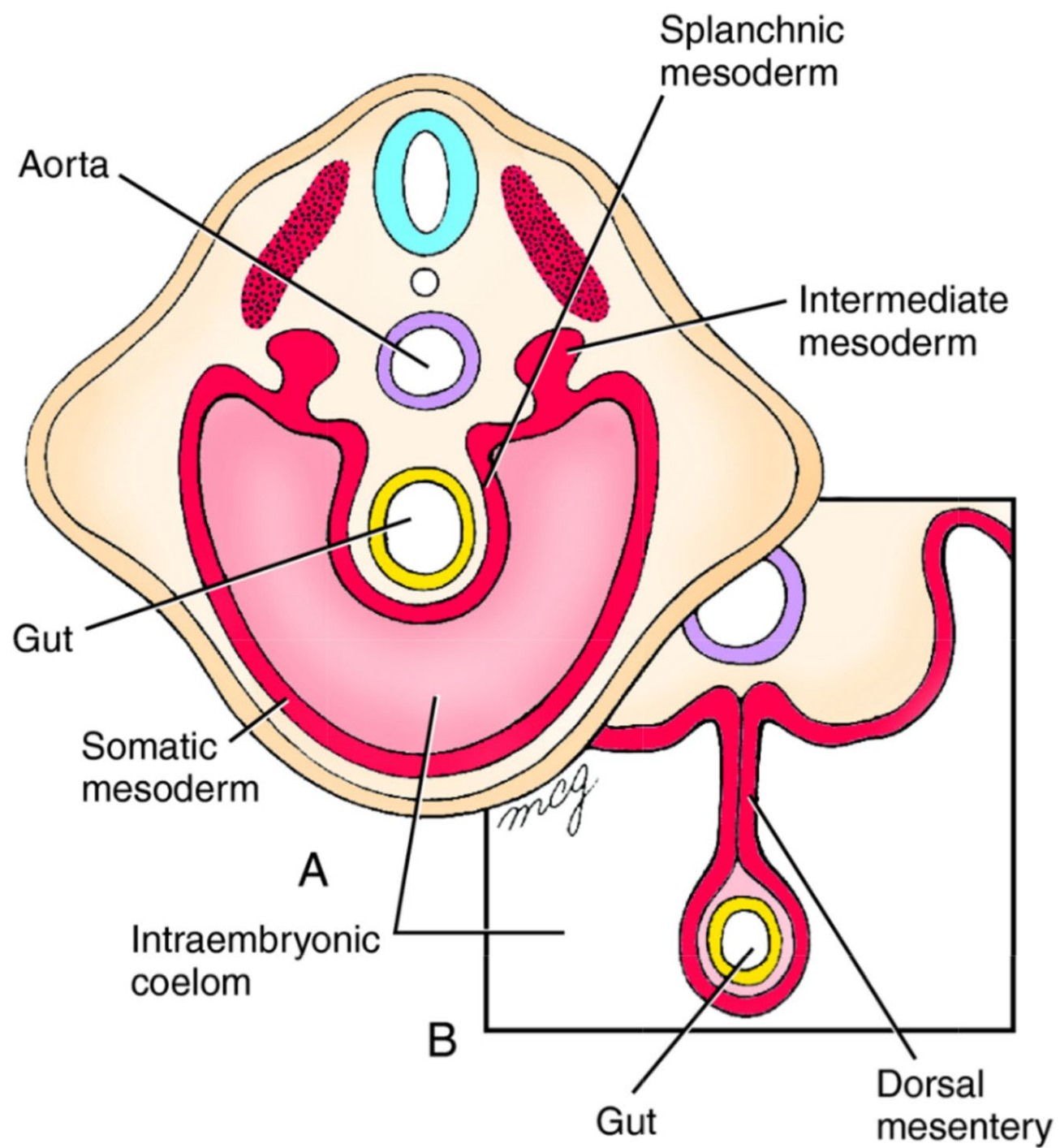
### SEPTUM TRANSVERSUM

Separates pericardial development from developing gut by moving to lie caudal to pericardial cavity. It descends from neck.

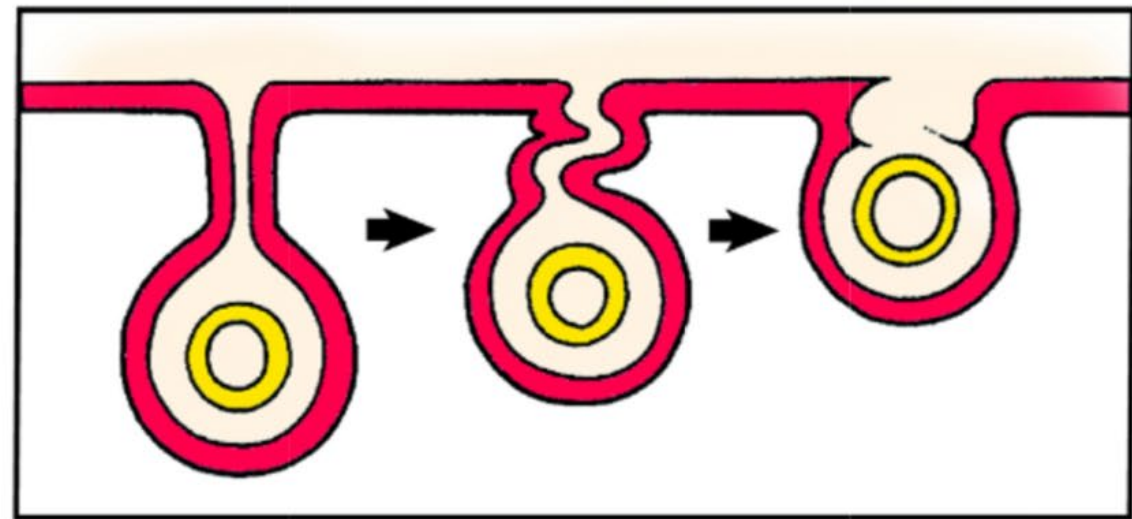
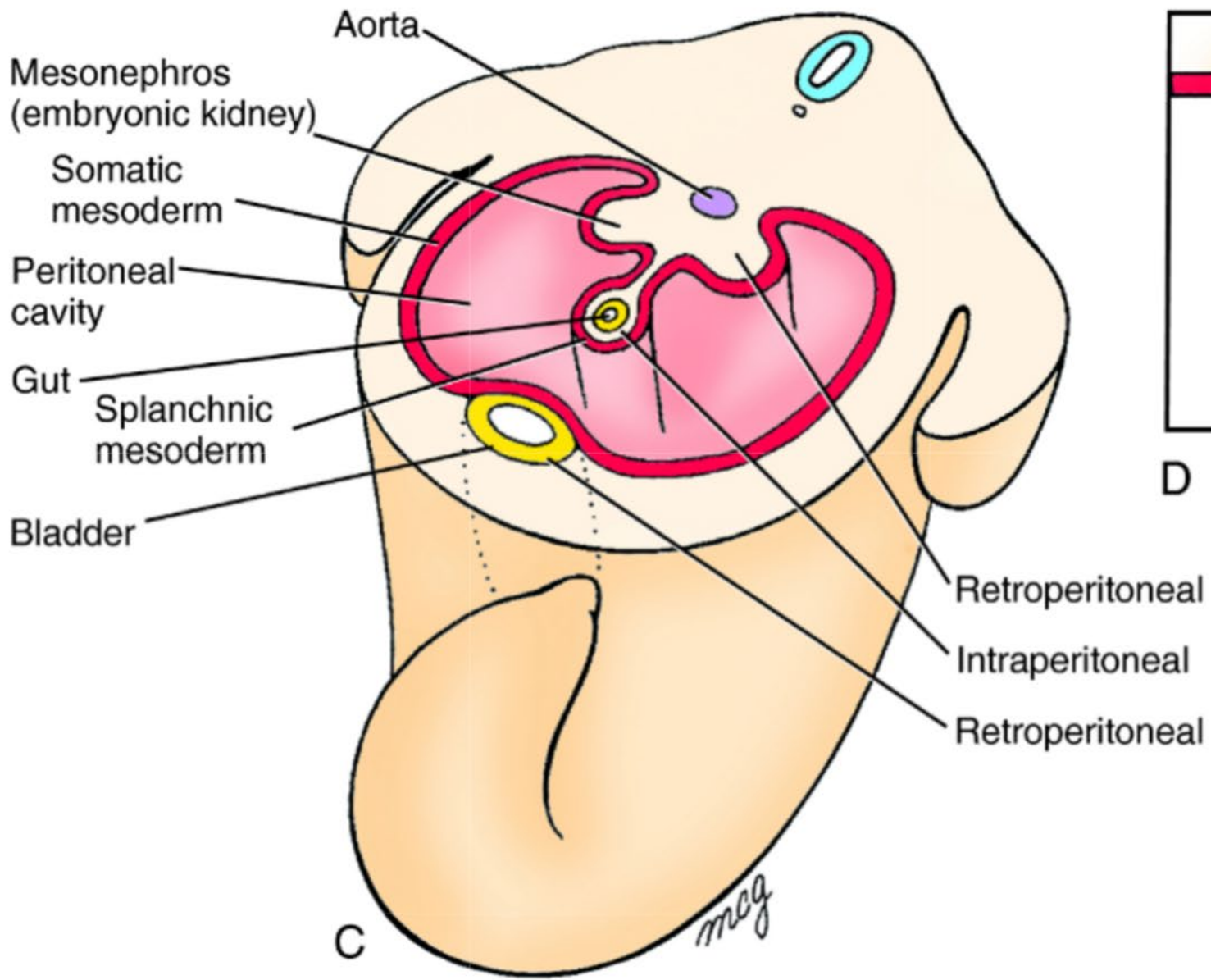
BODY WALL and PLEUROPERITONEAL MEMBRANES. Both grow in to fuse with septum transversum

DORSAL MESENTERY OF OESOPHAGUS

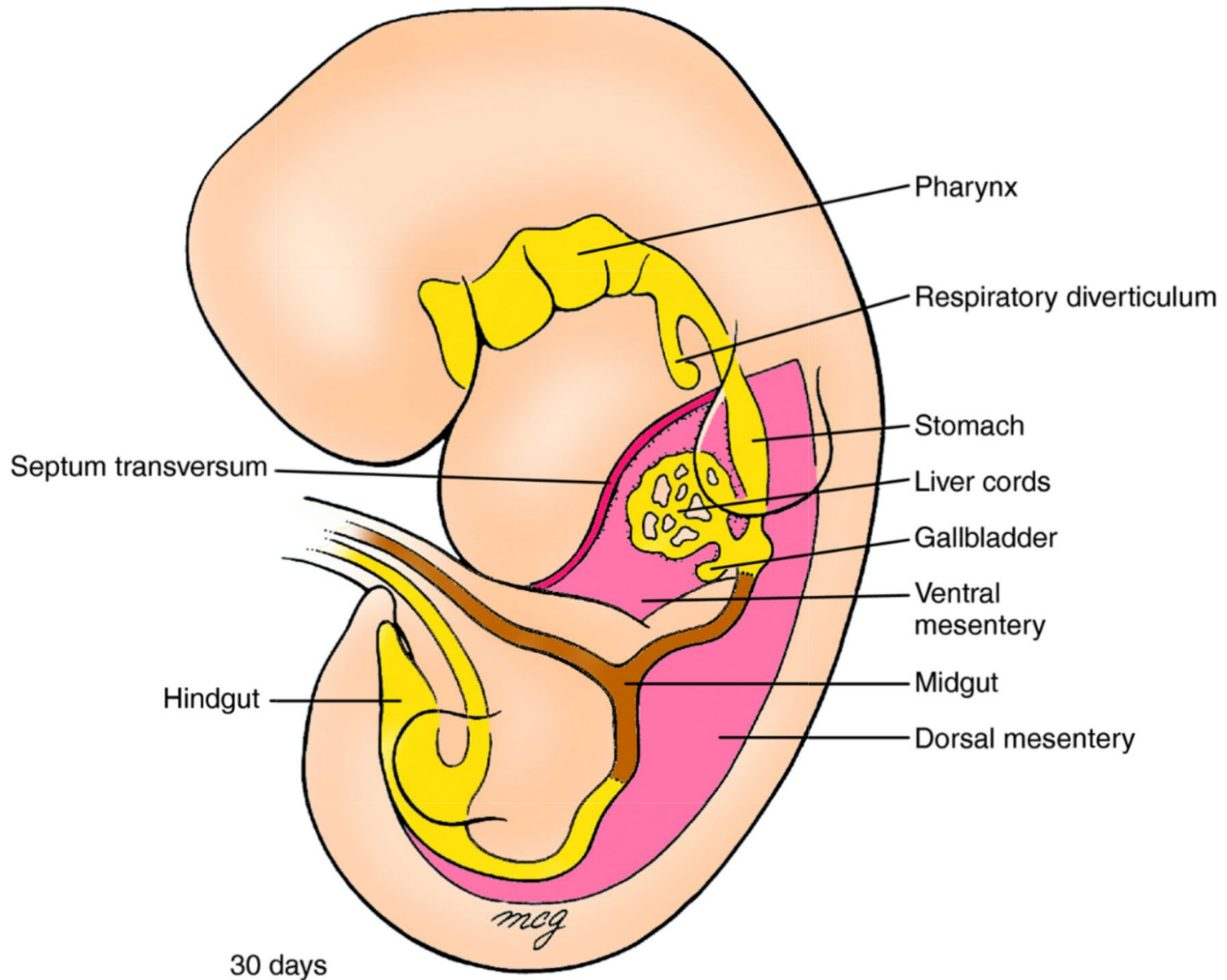
Completes the diaphragm posteriorly









D



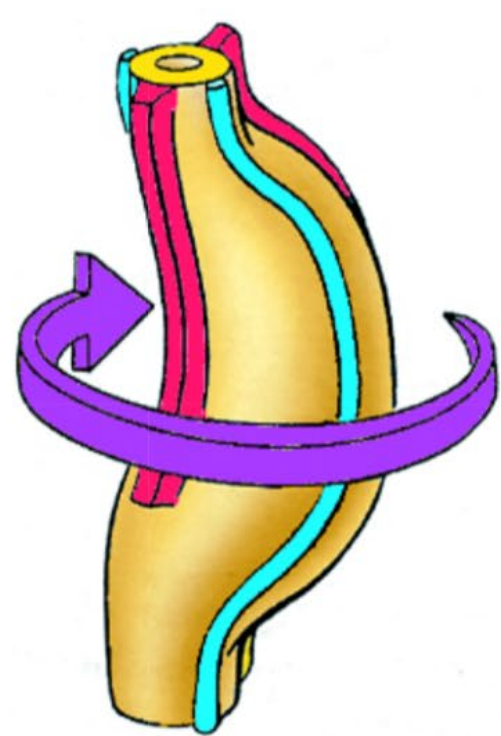
Representative left and right vagal branches  
Dorsal mesentery  
Ventral mesentery



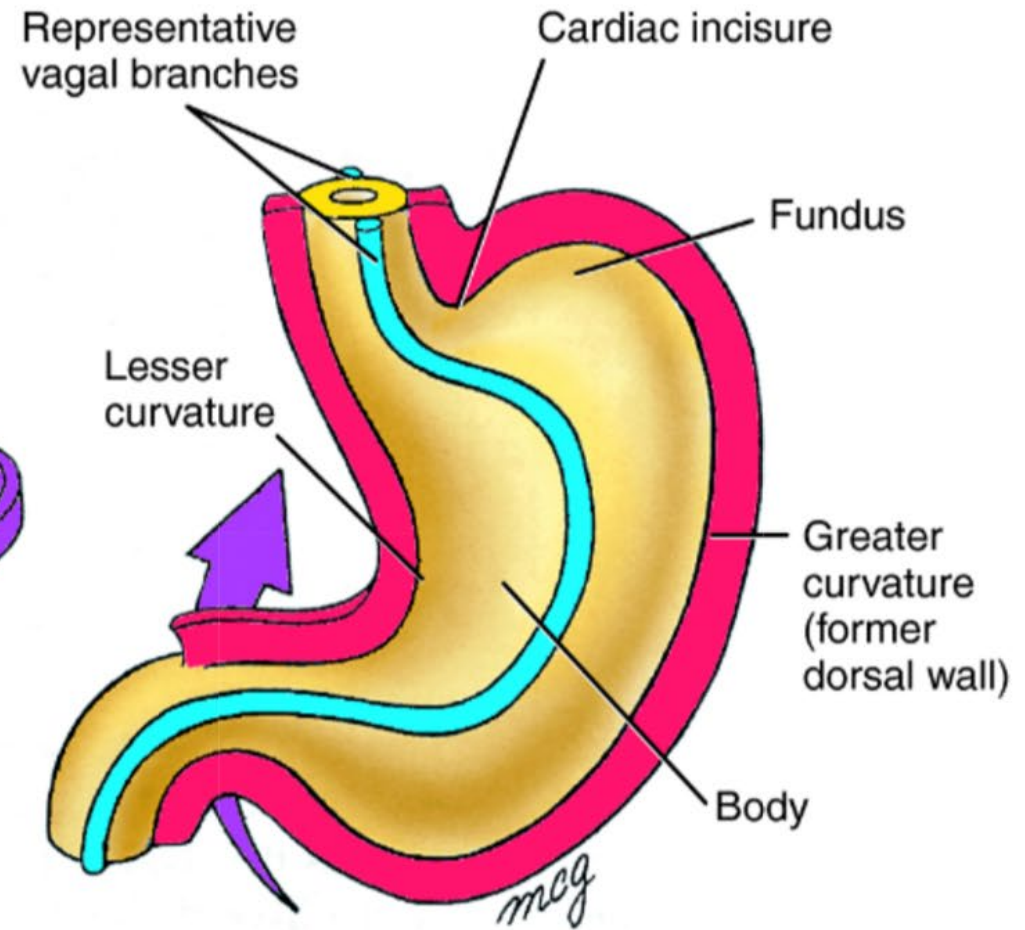
A 27 days



B 28 days

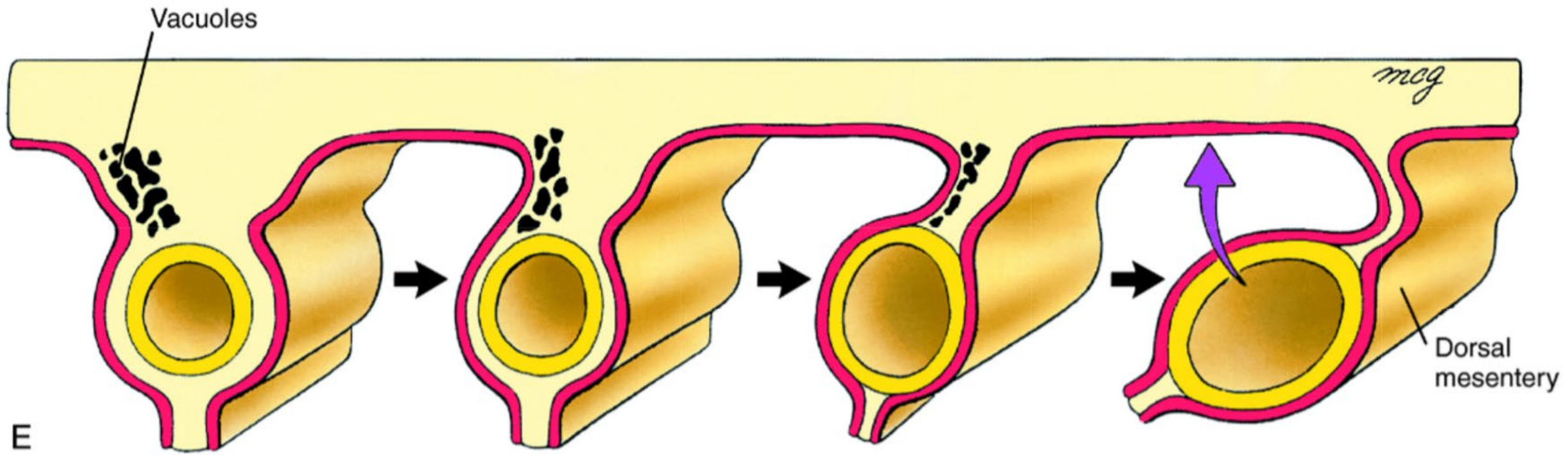


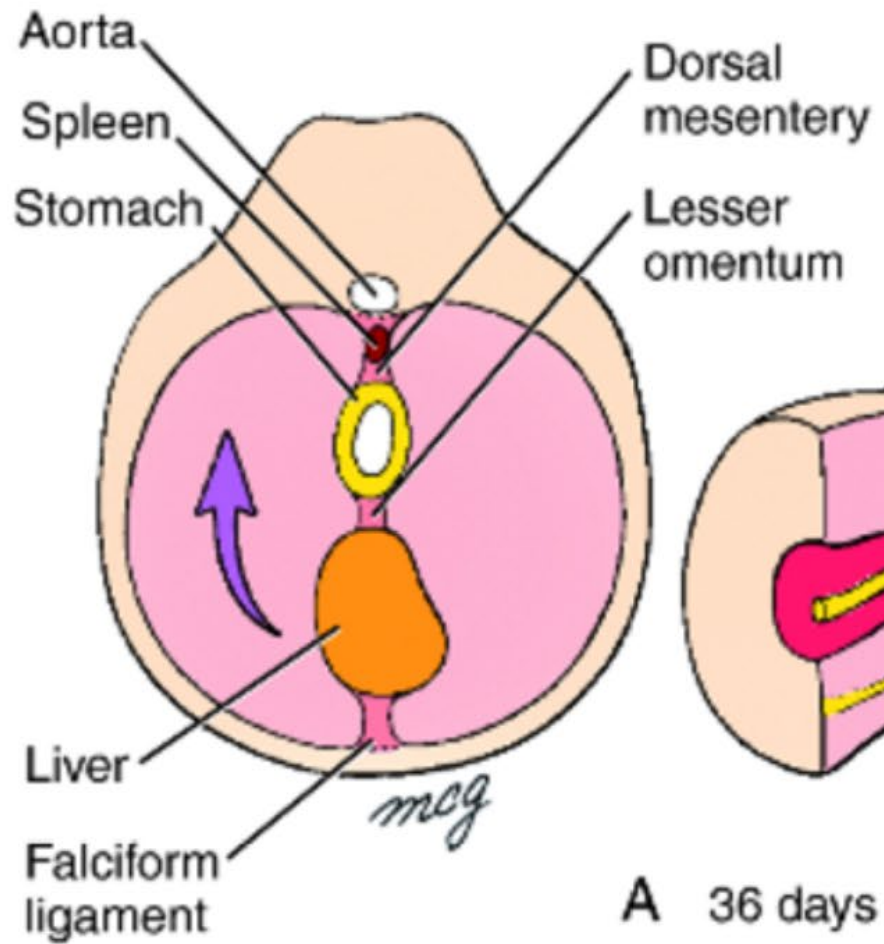
C 35 days



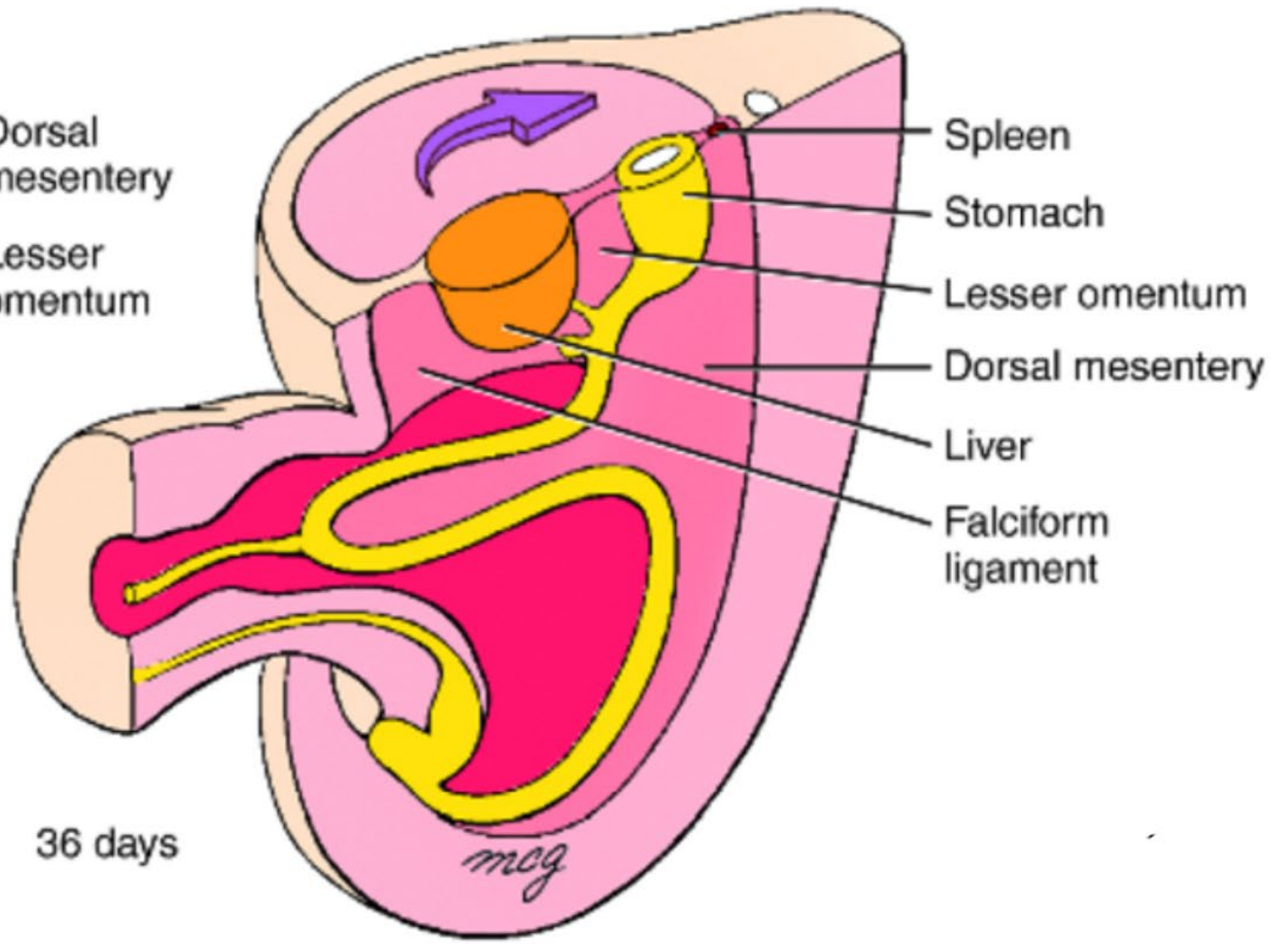
D 56 days

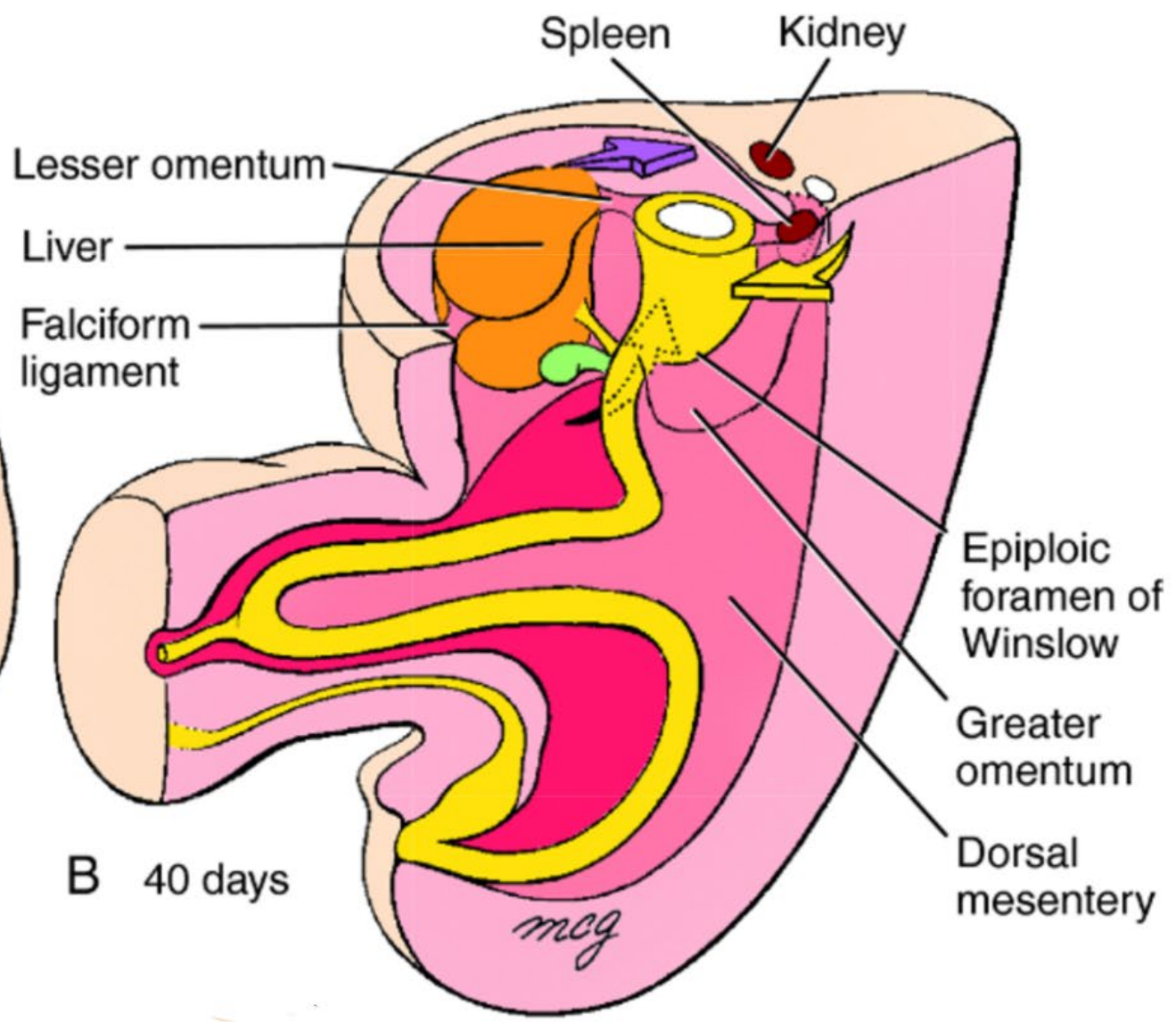
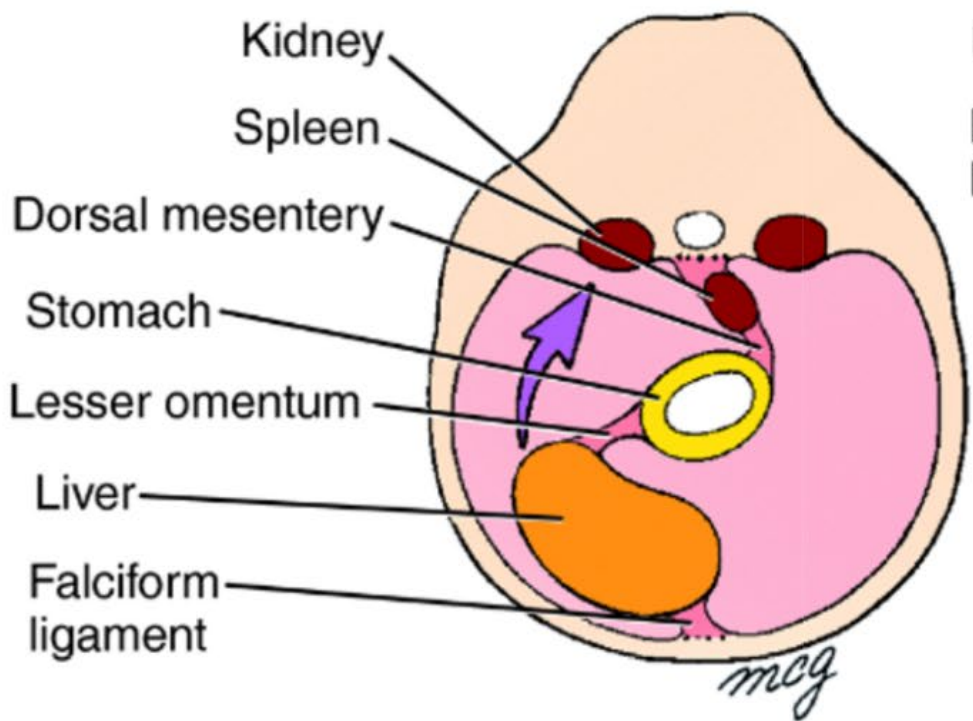




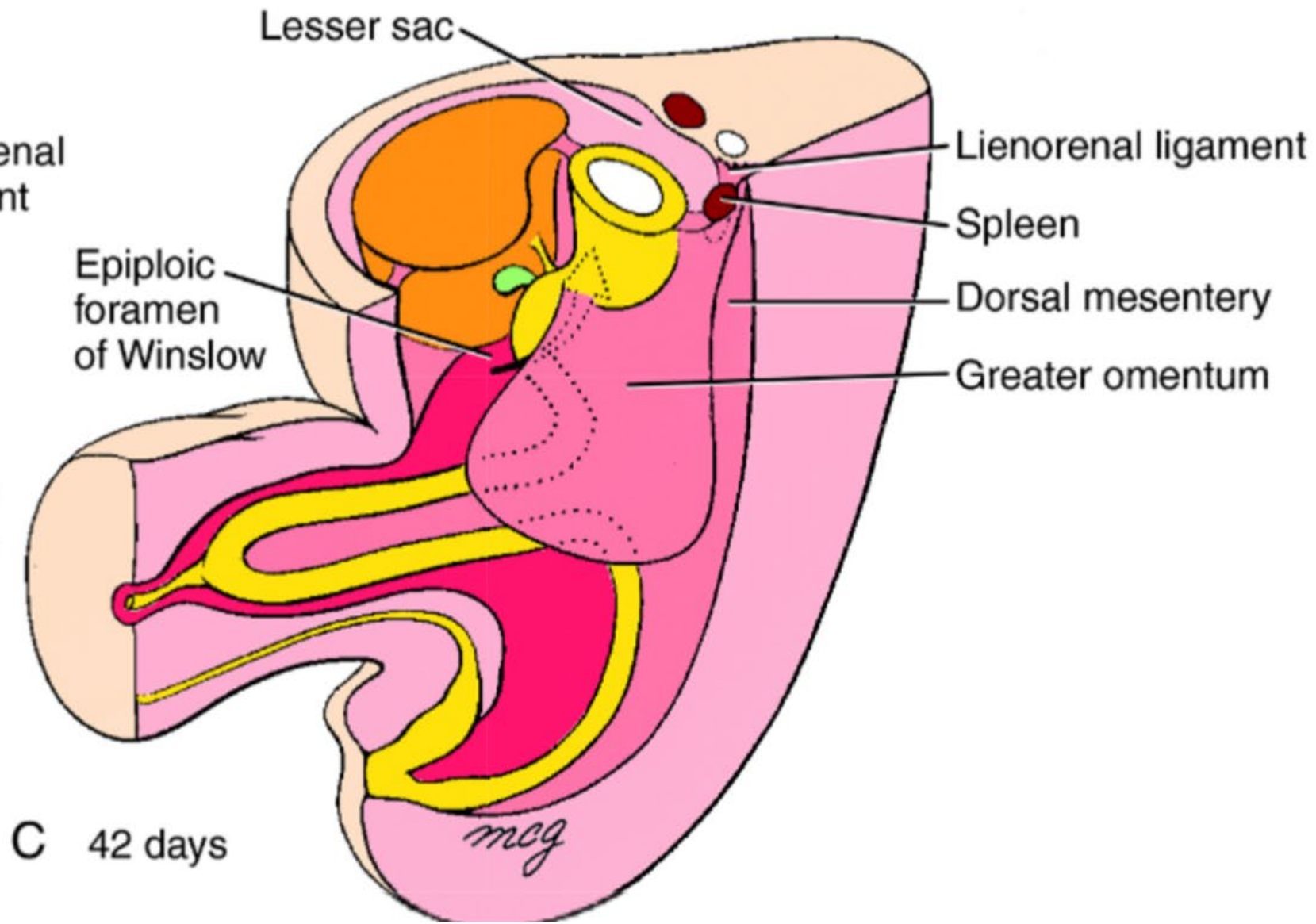
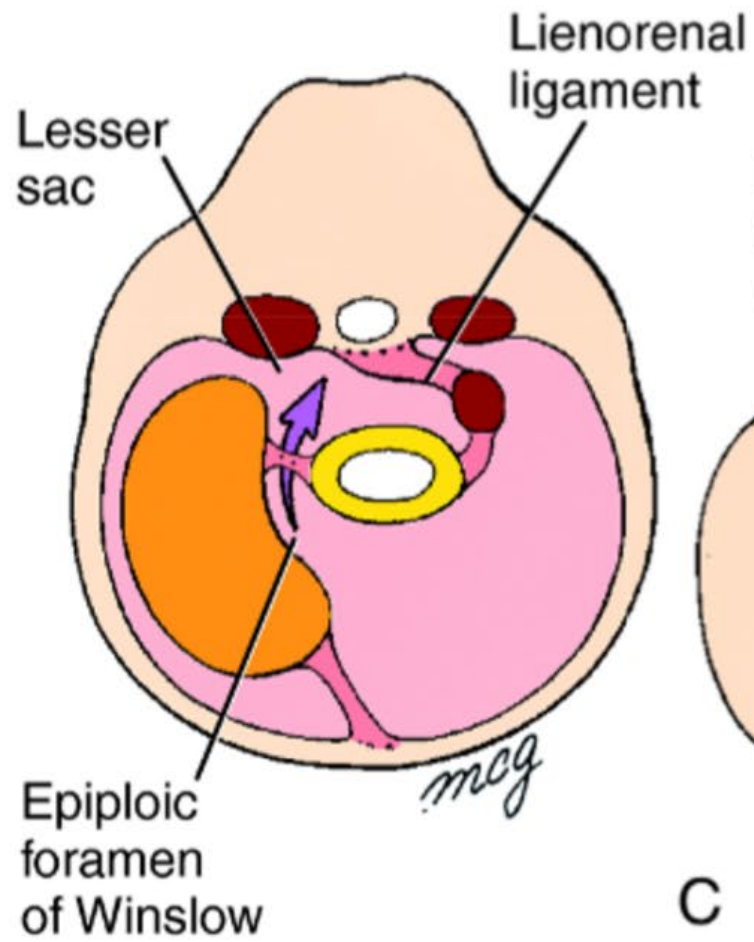


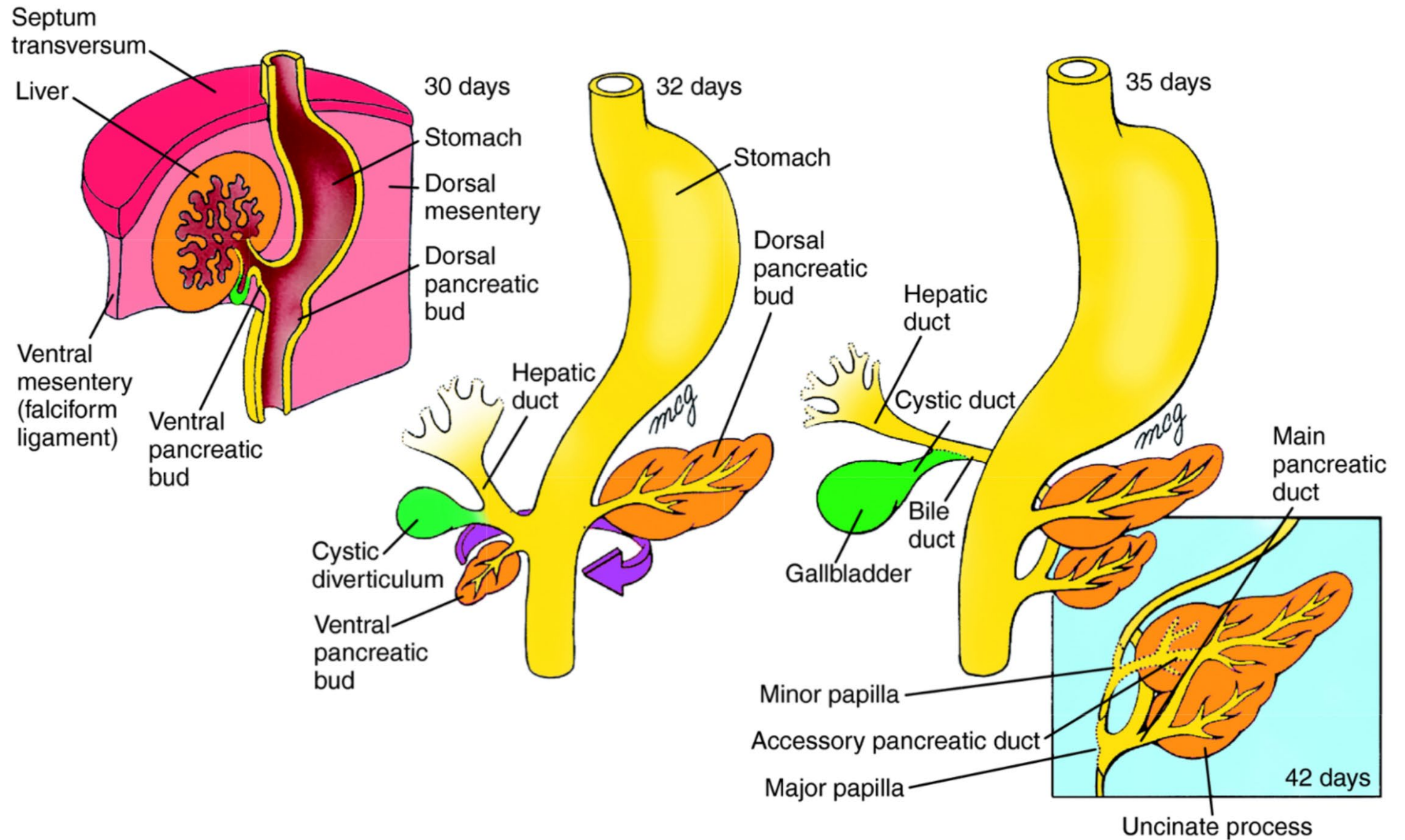
A 36 days



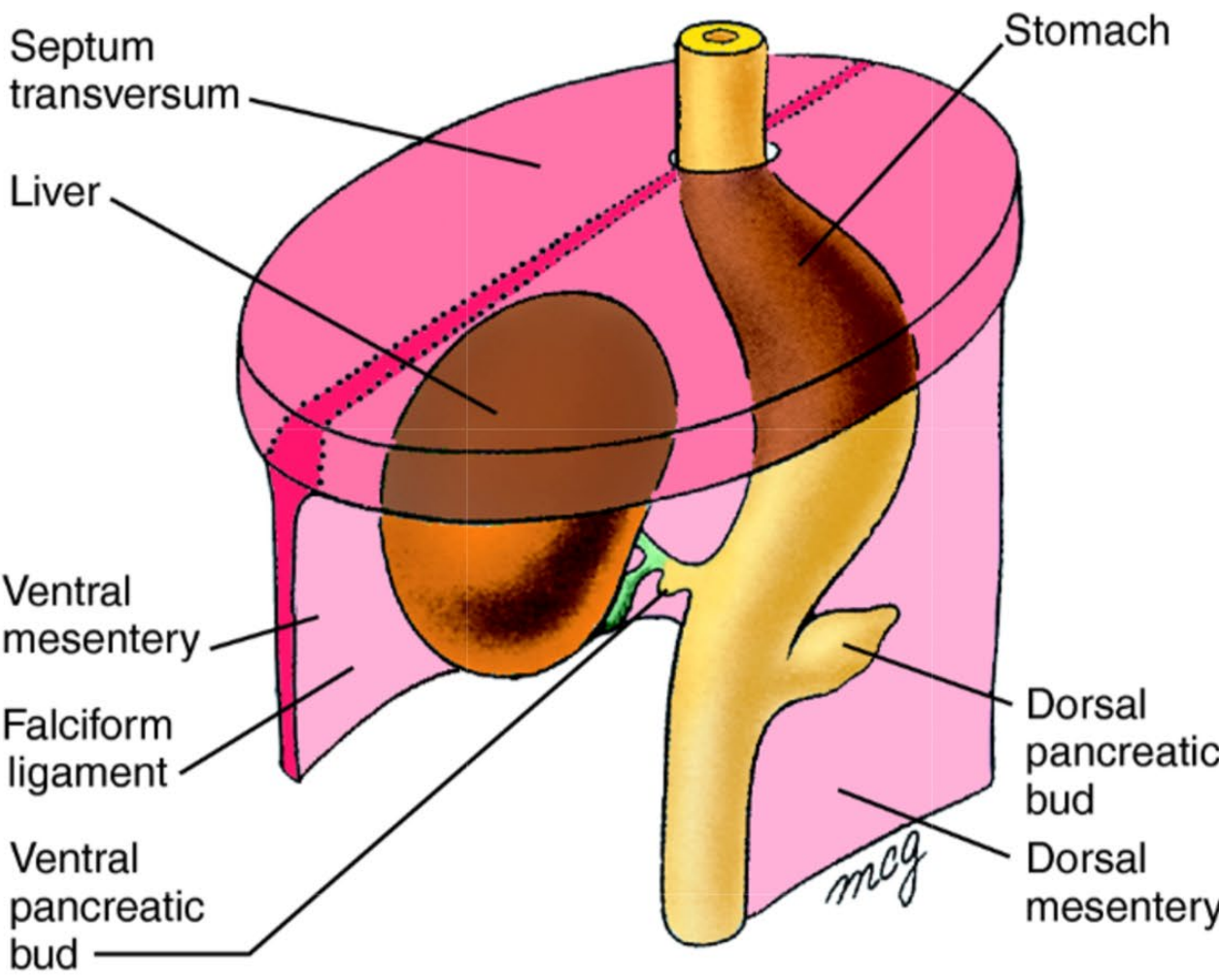




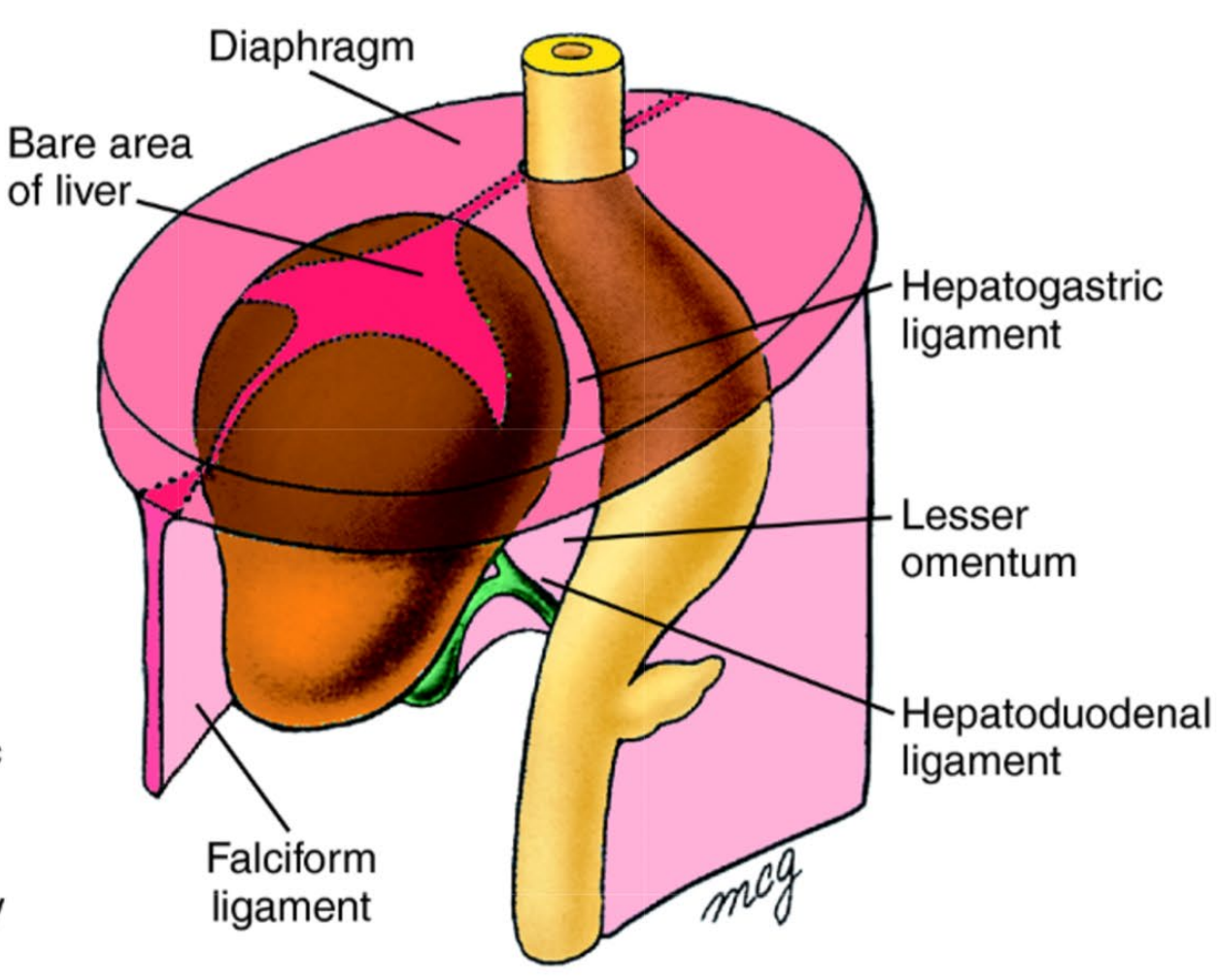






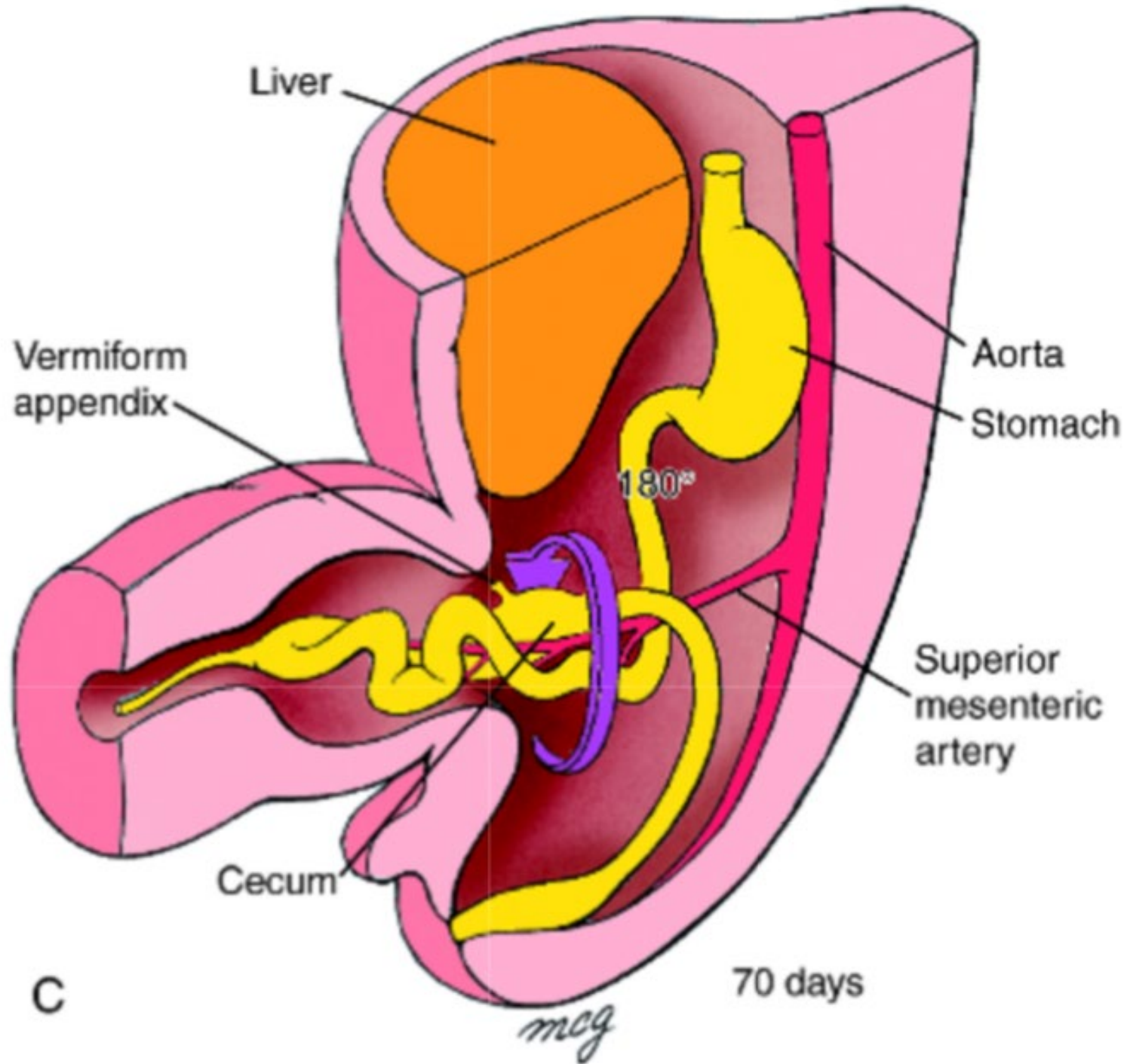


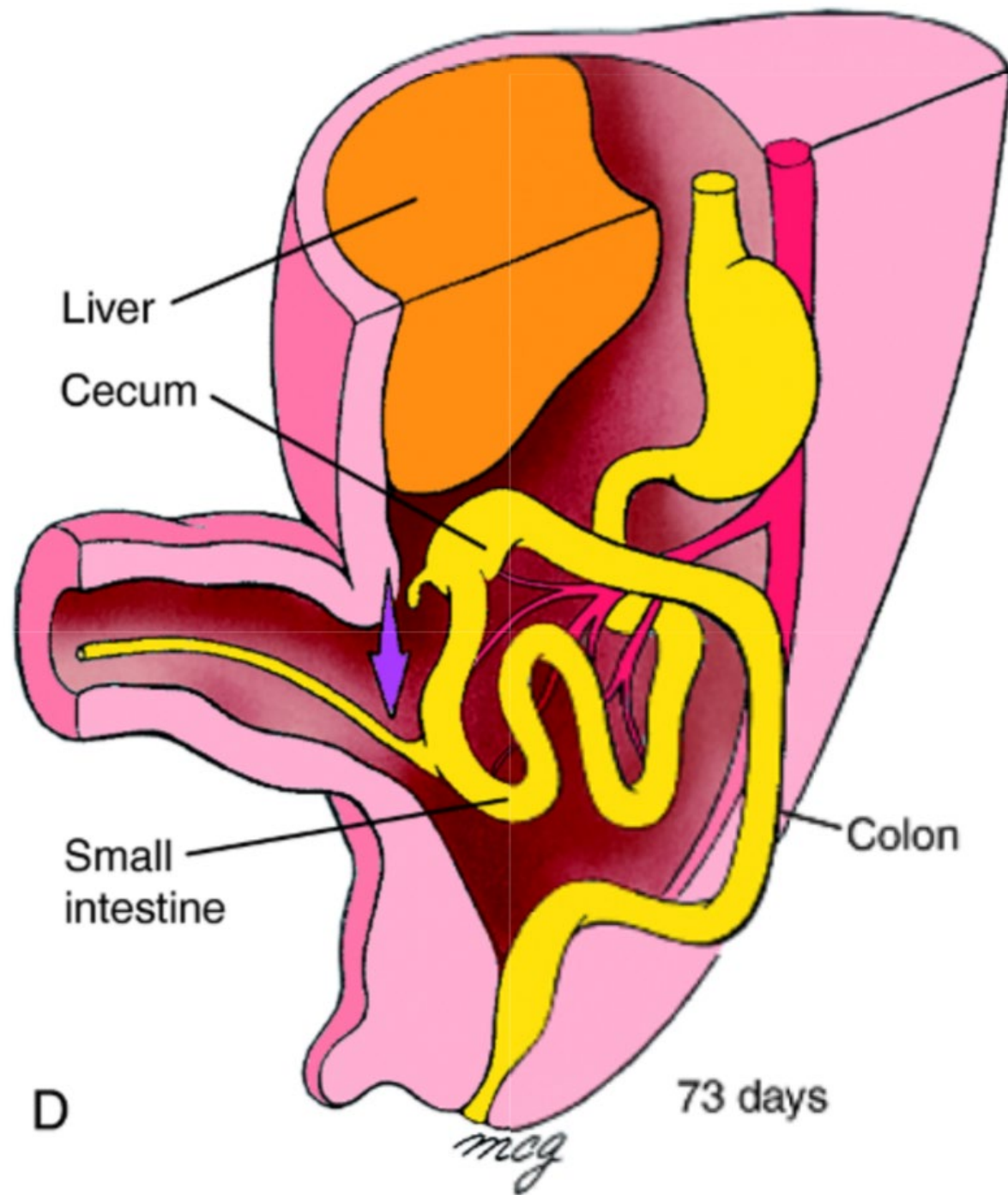
Mid 5th week



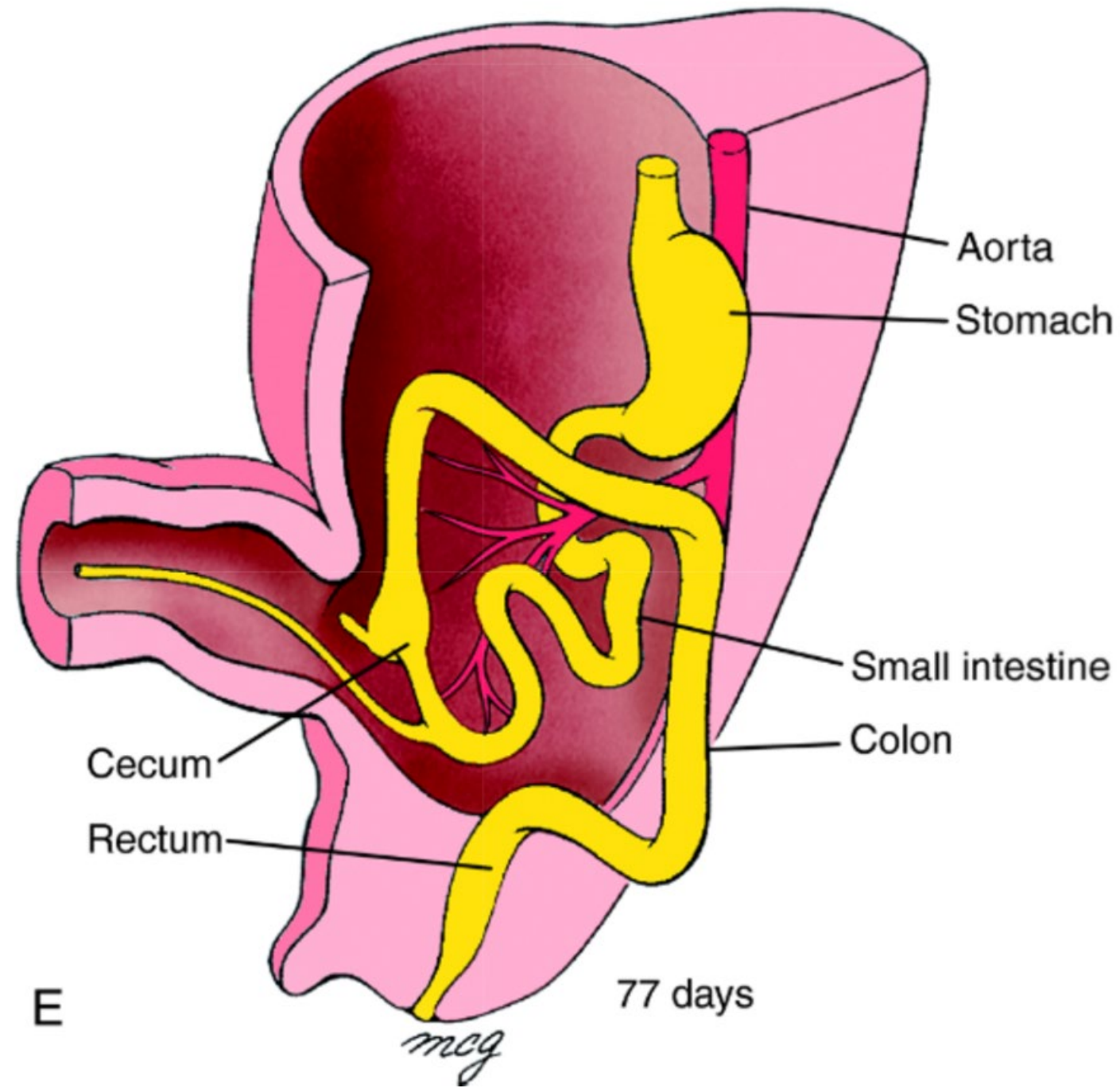
Mid 6th week



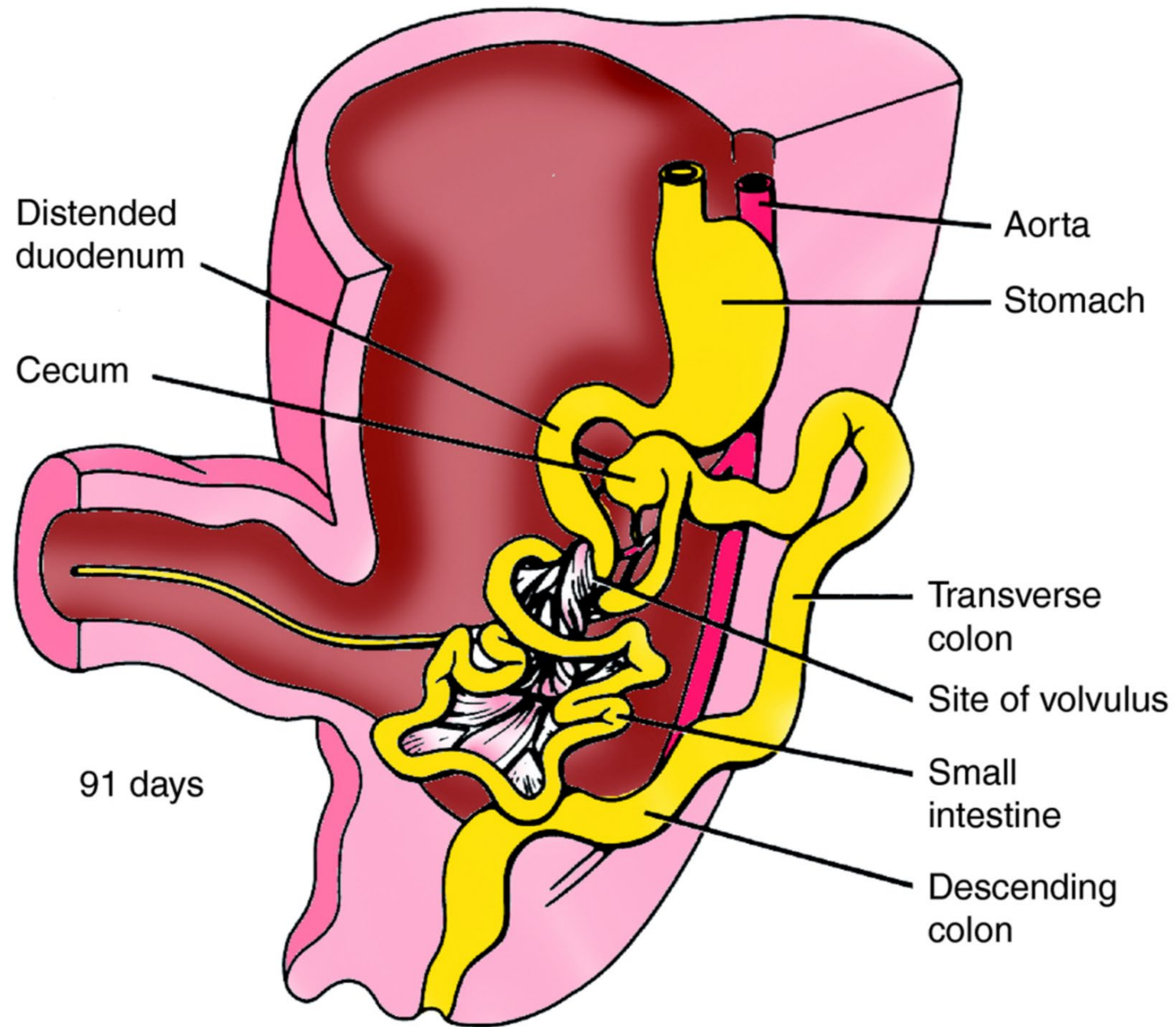


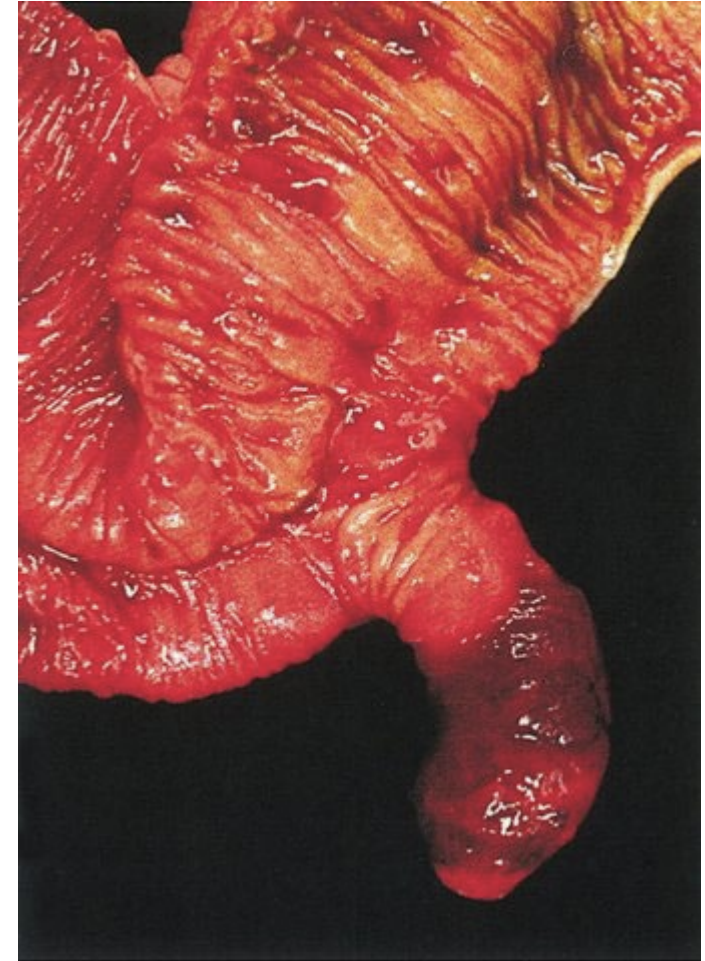
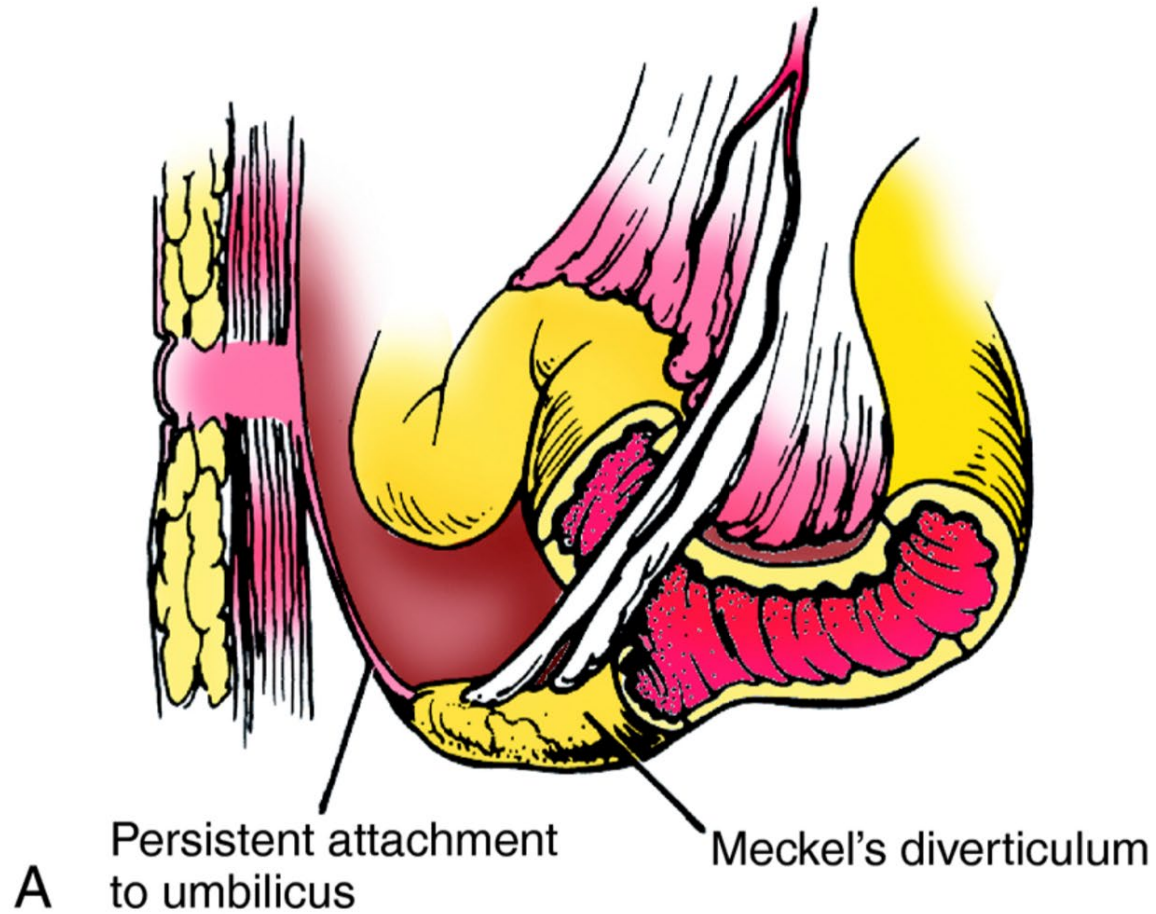


D

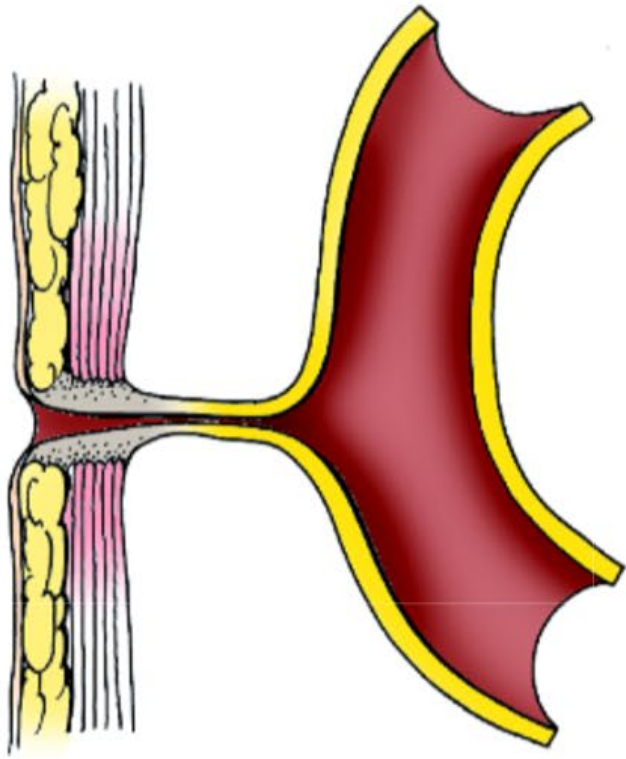




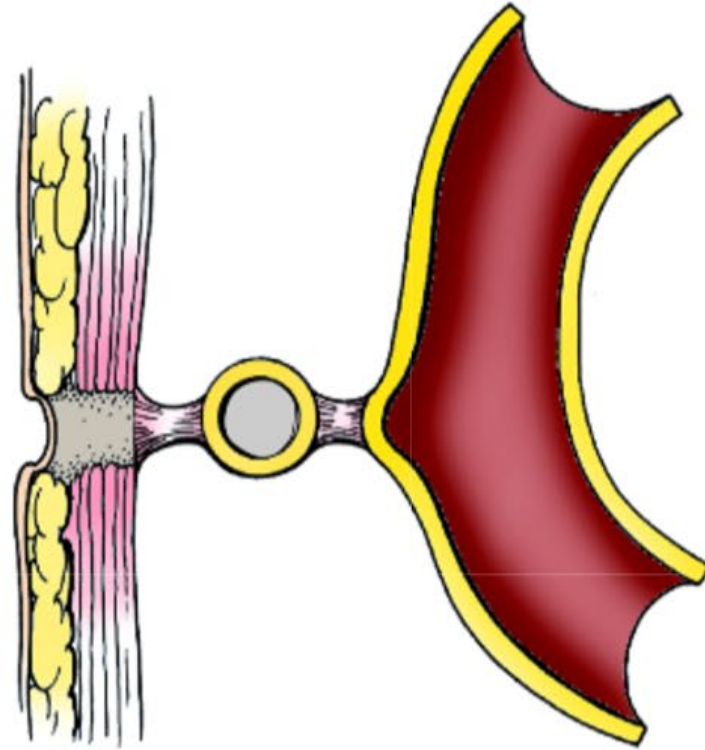




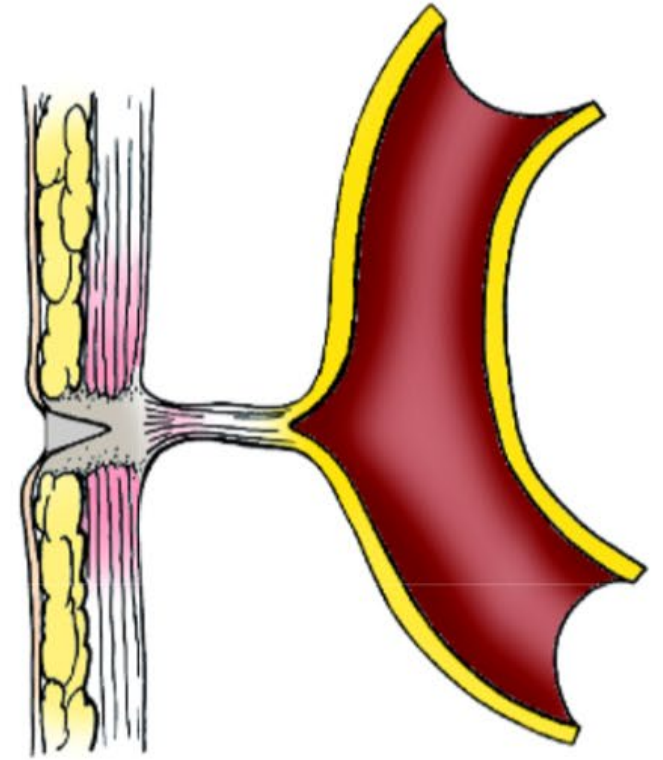
Rule of 2's: 2% of the population, 2 inches long, 2 feet from caecum, 2% symptomatic



B Omphalomesenteric fistula

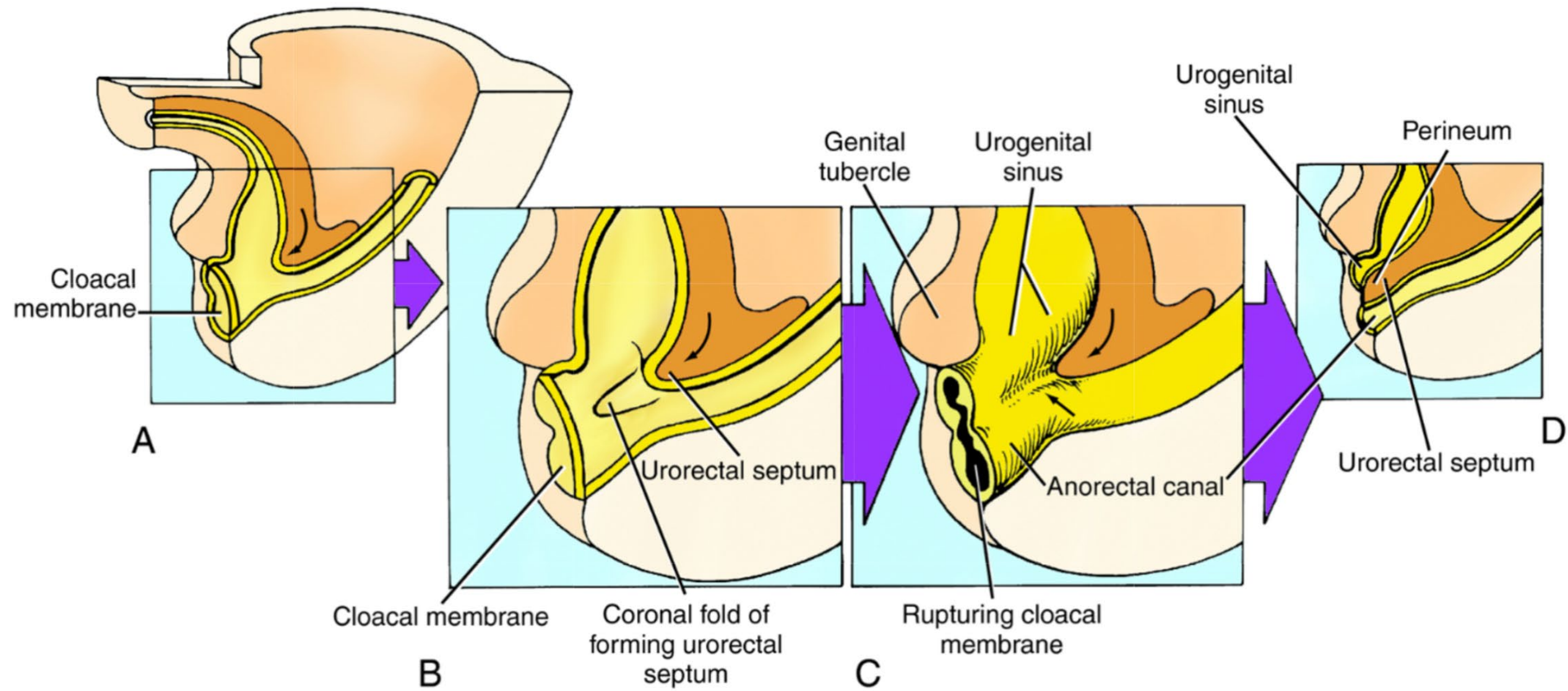


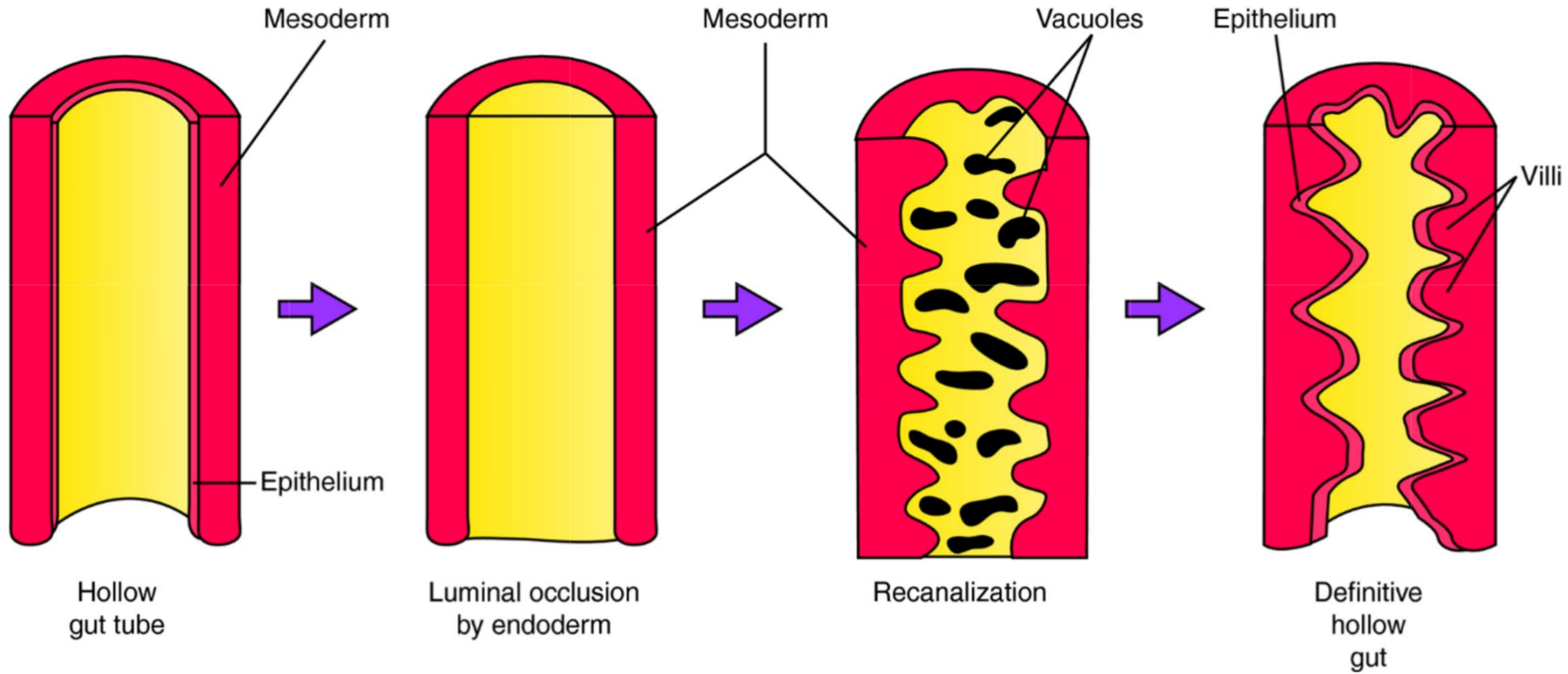
C Omphalomesenteric cyst



D Omphalomesenteric ligament (fibrous band)



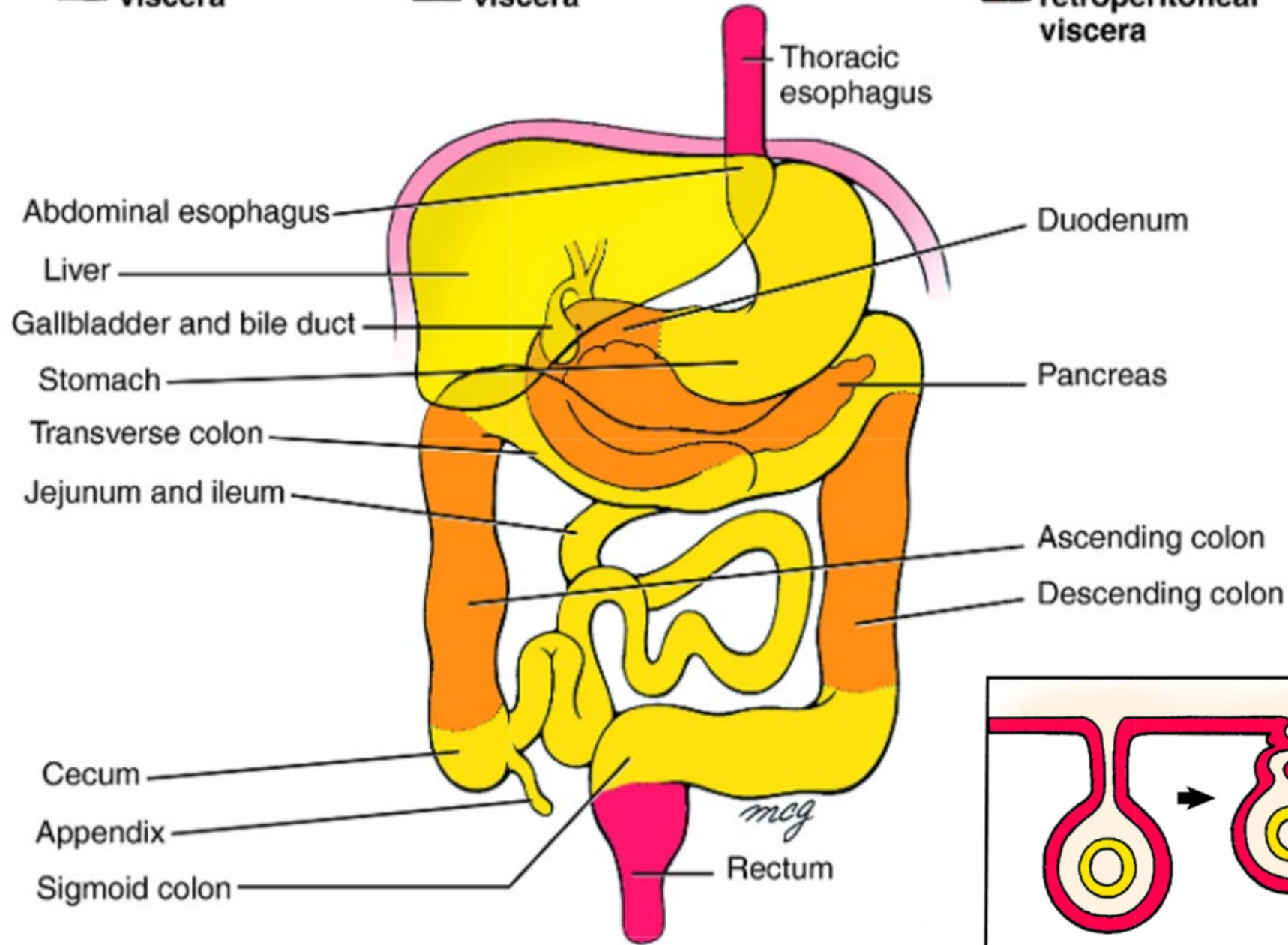




**Intraperitoneal  
viscera**

**Retroperitoneal  
viscera**

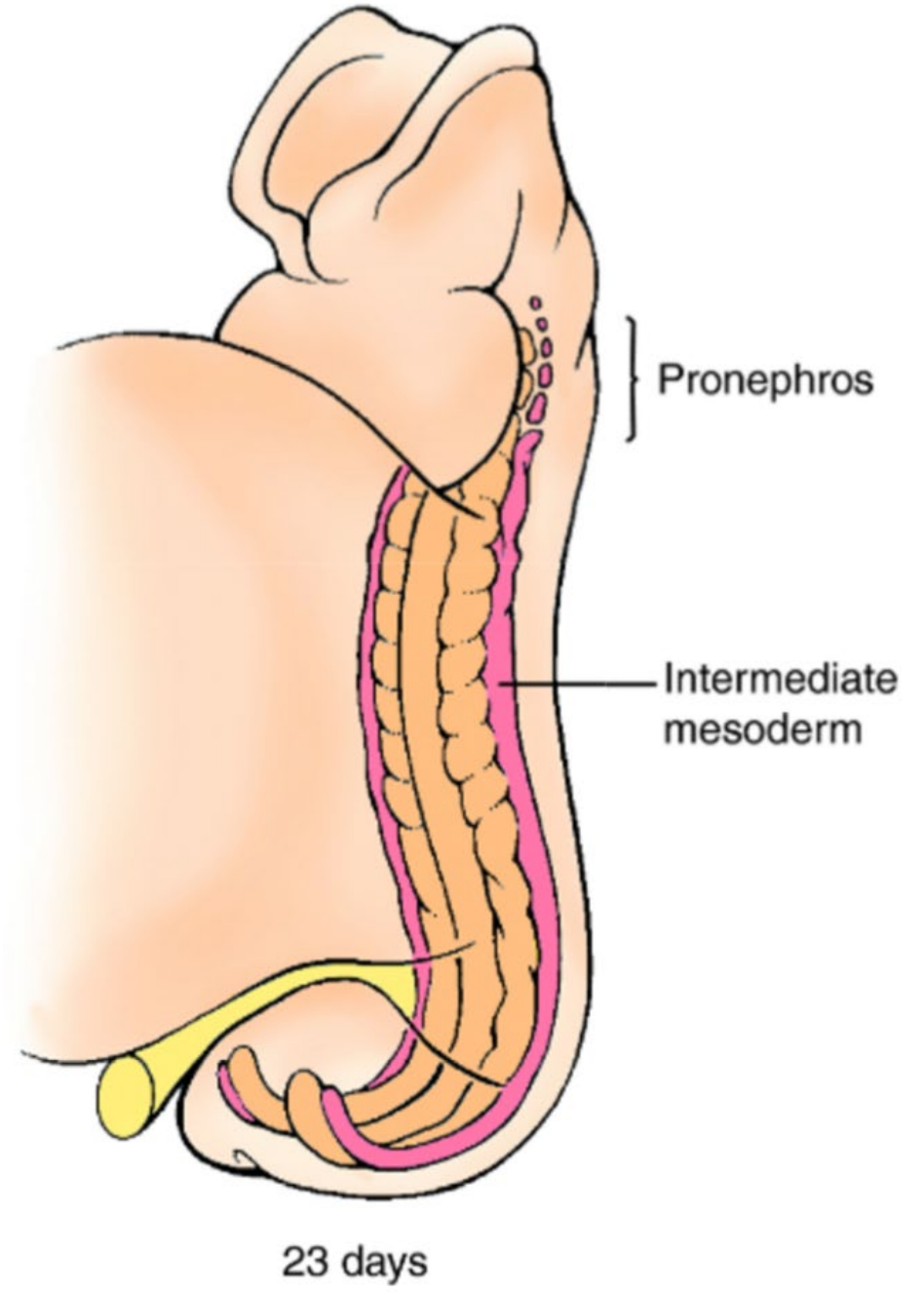
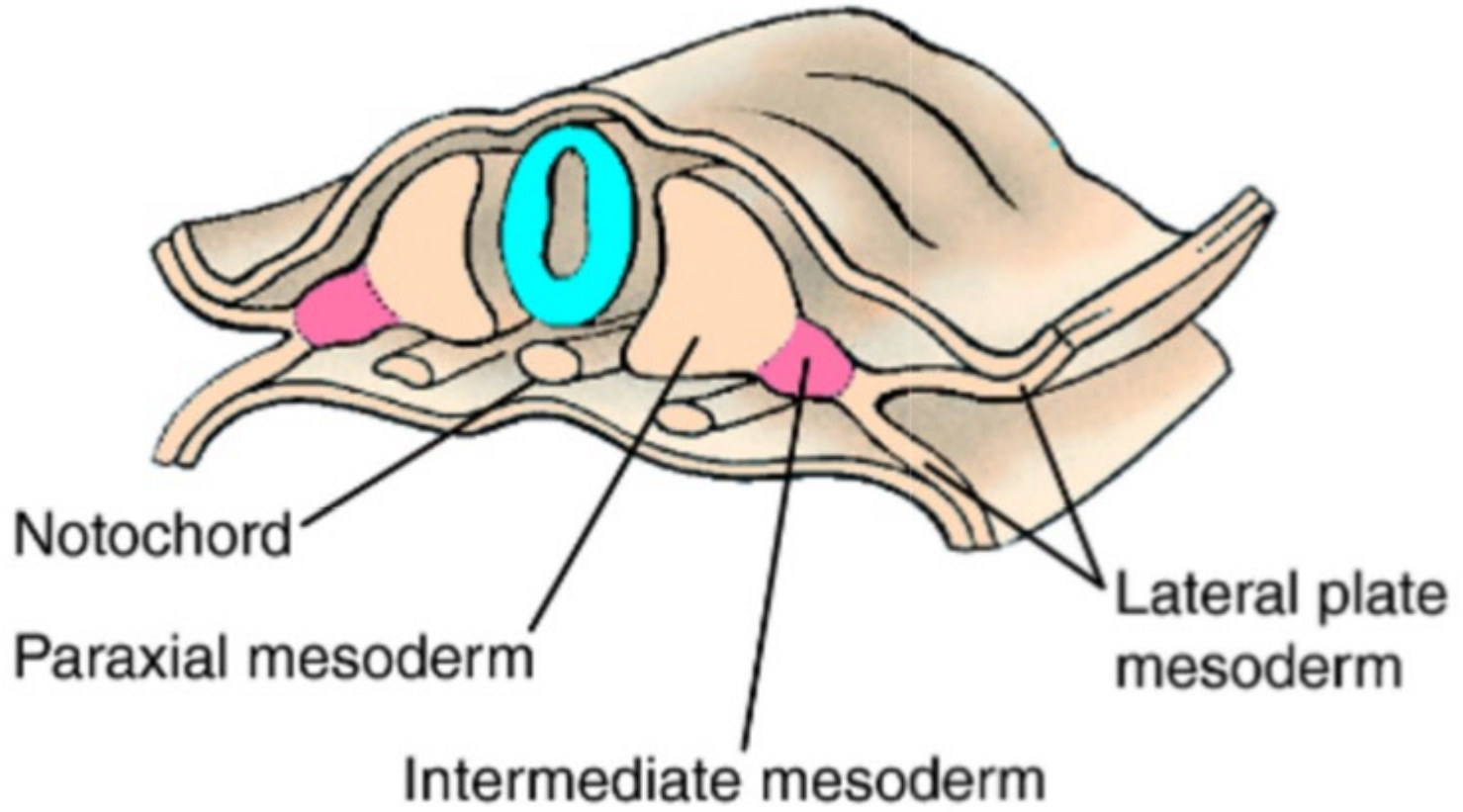
**Secondarily  
retroperitoneal  
viscera**

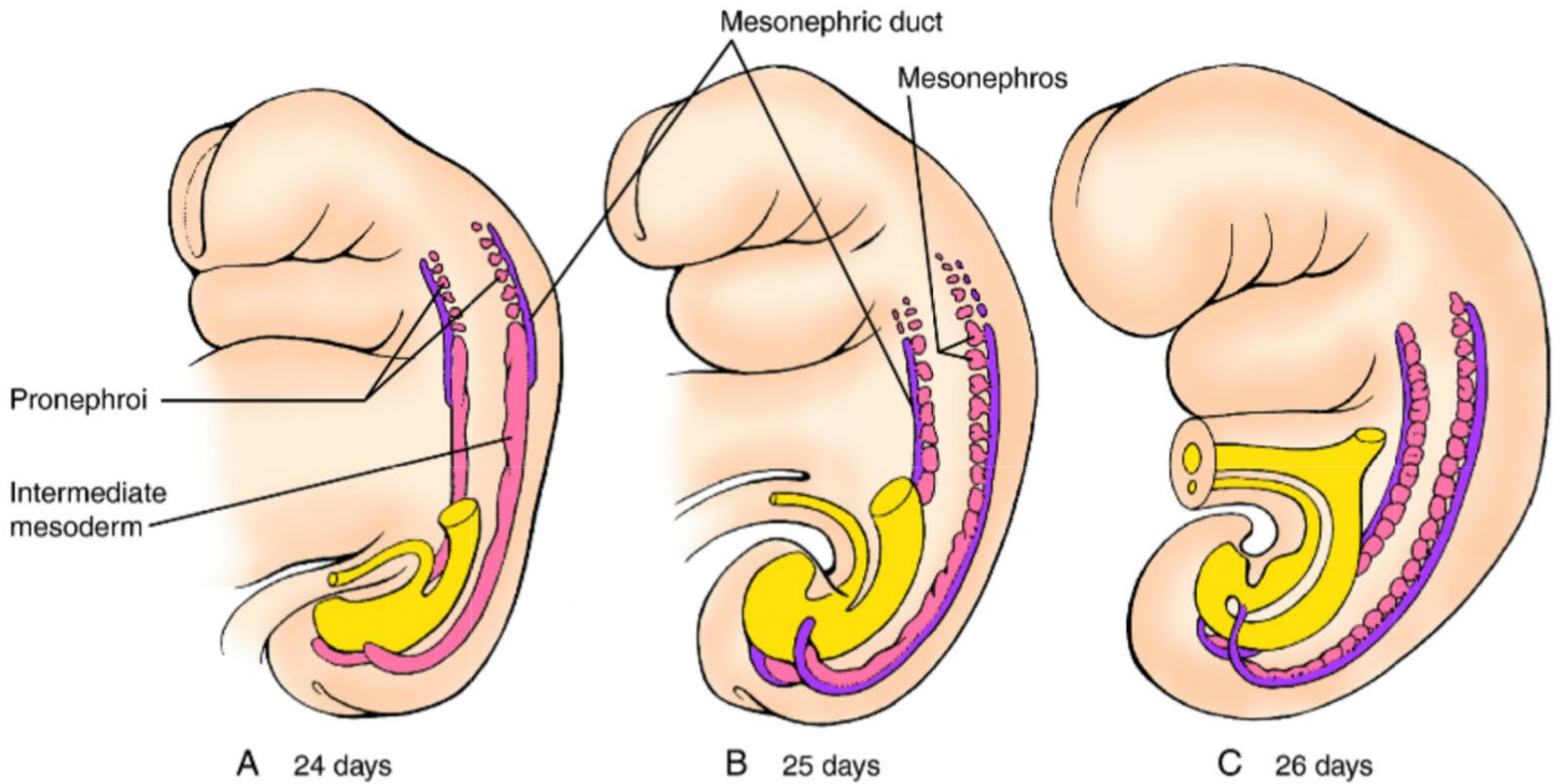




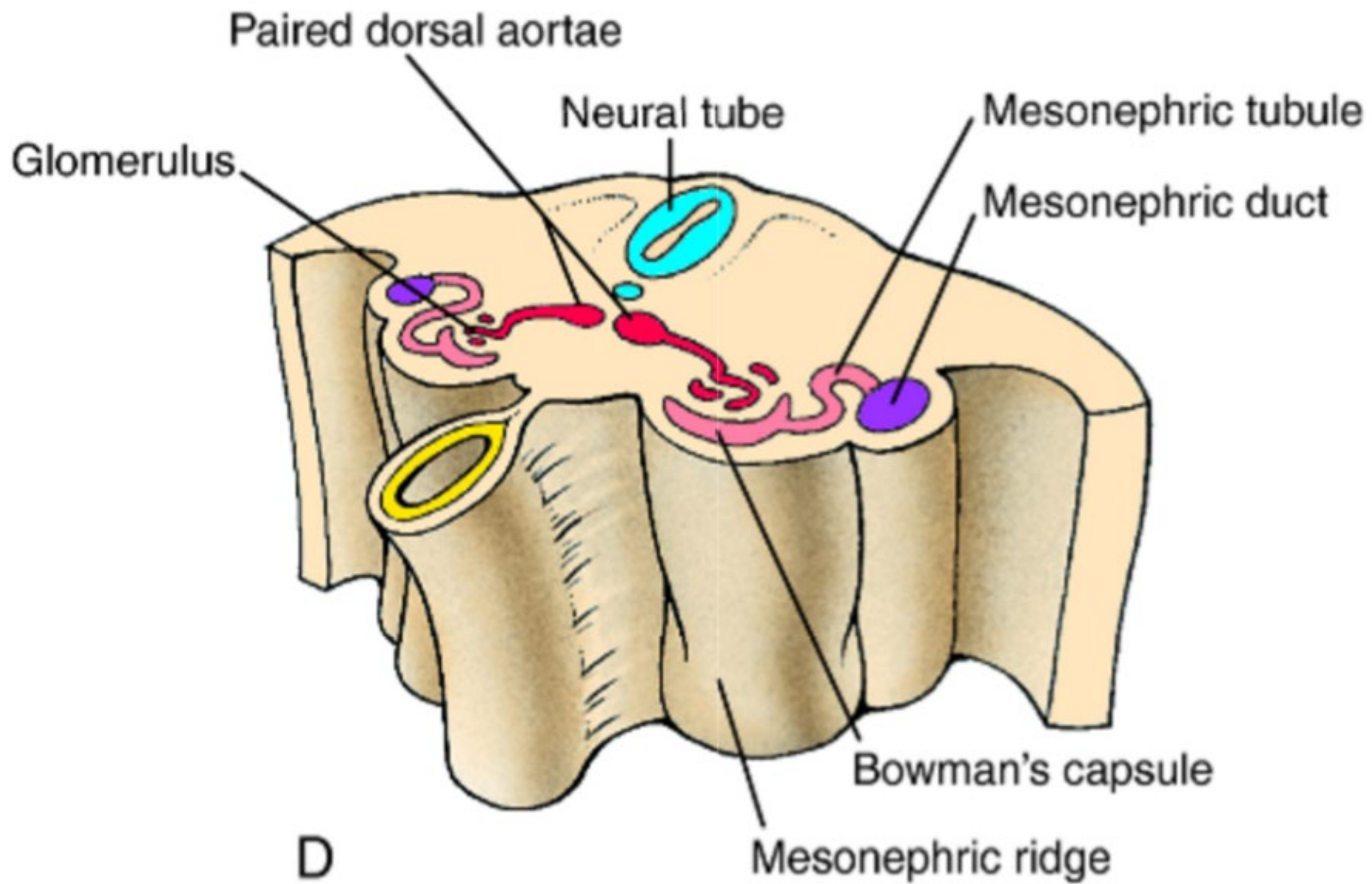
# Overview

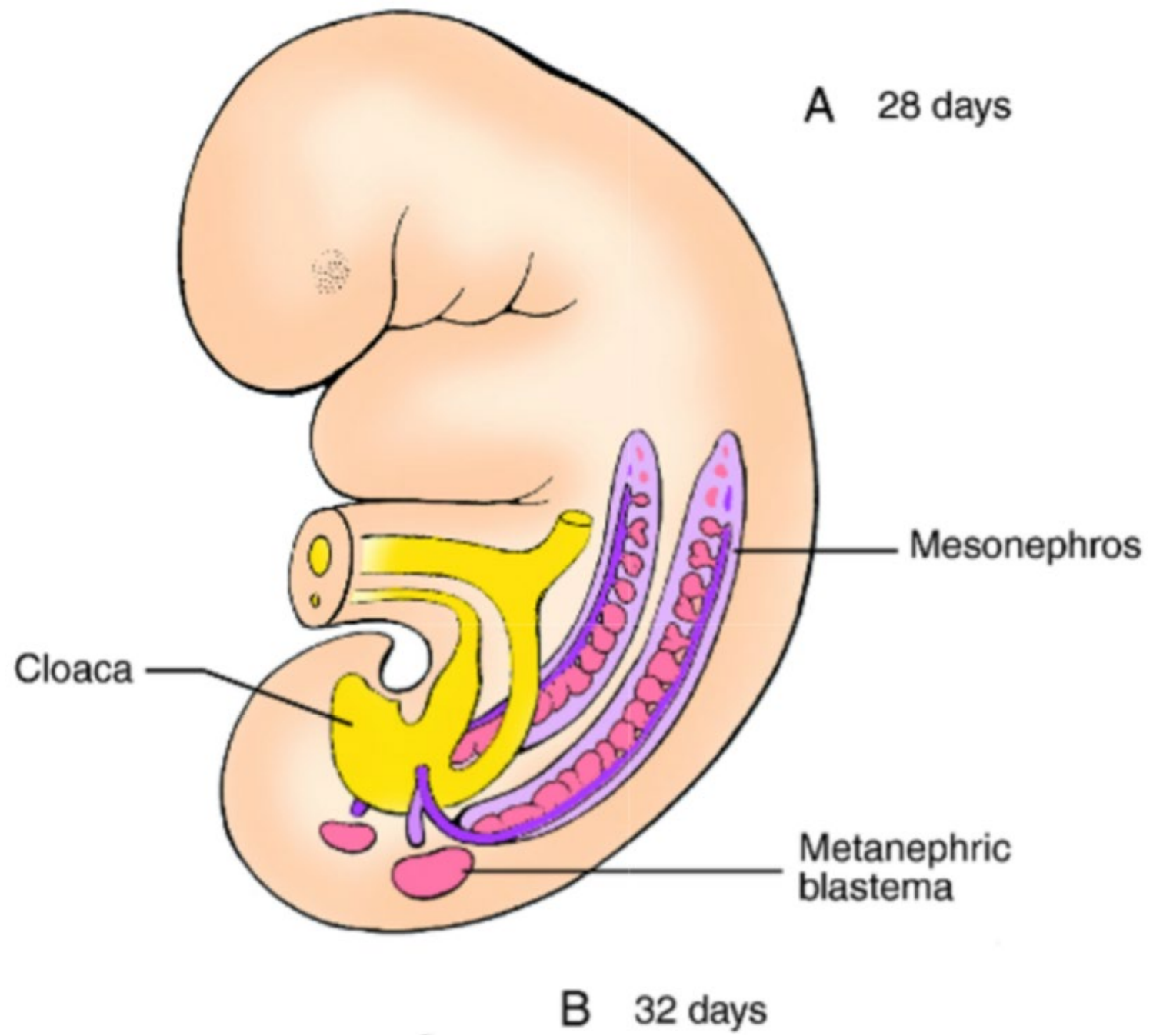
1. Early embryonic development
2. Central nervous system development
3. Endodermal tube formation and derivatives
4. **Urogenital system development**
5. Branchial cleft derivatives
6. Cardiac and vasculature development

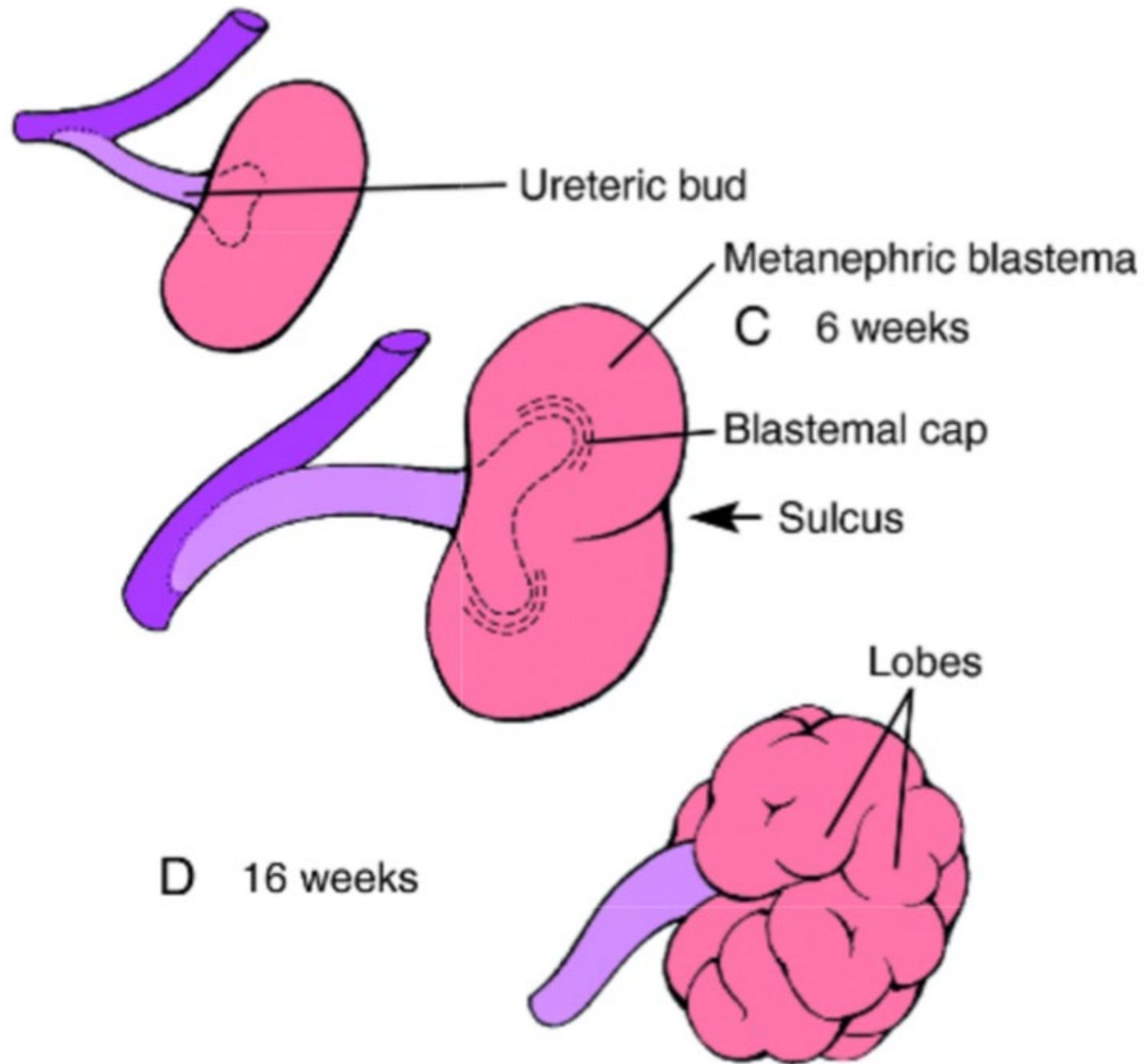




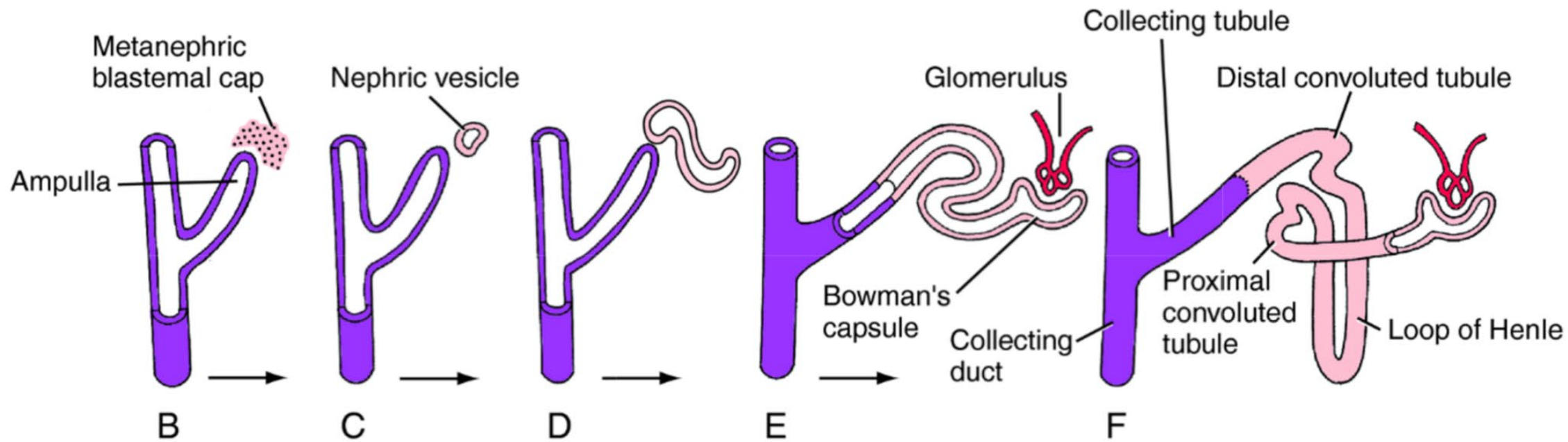
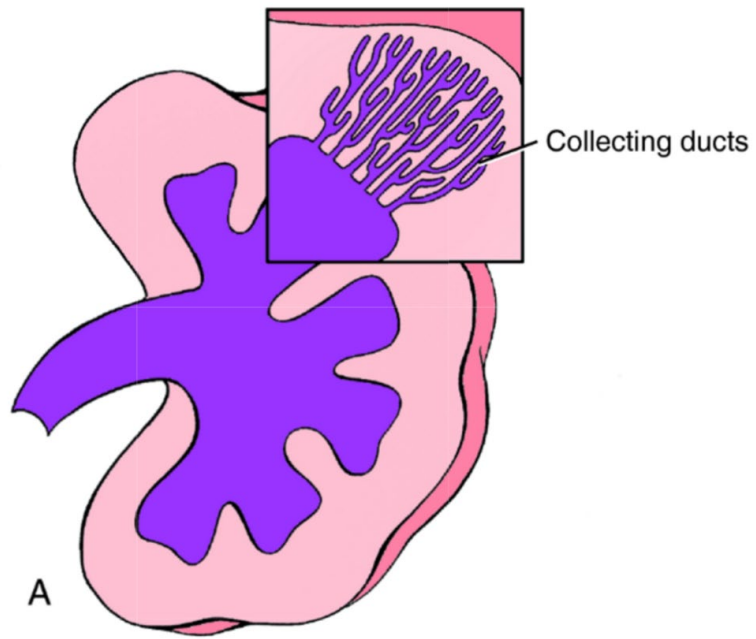


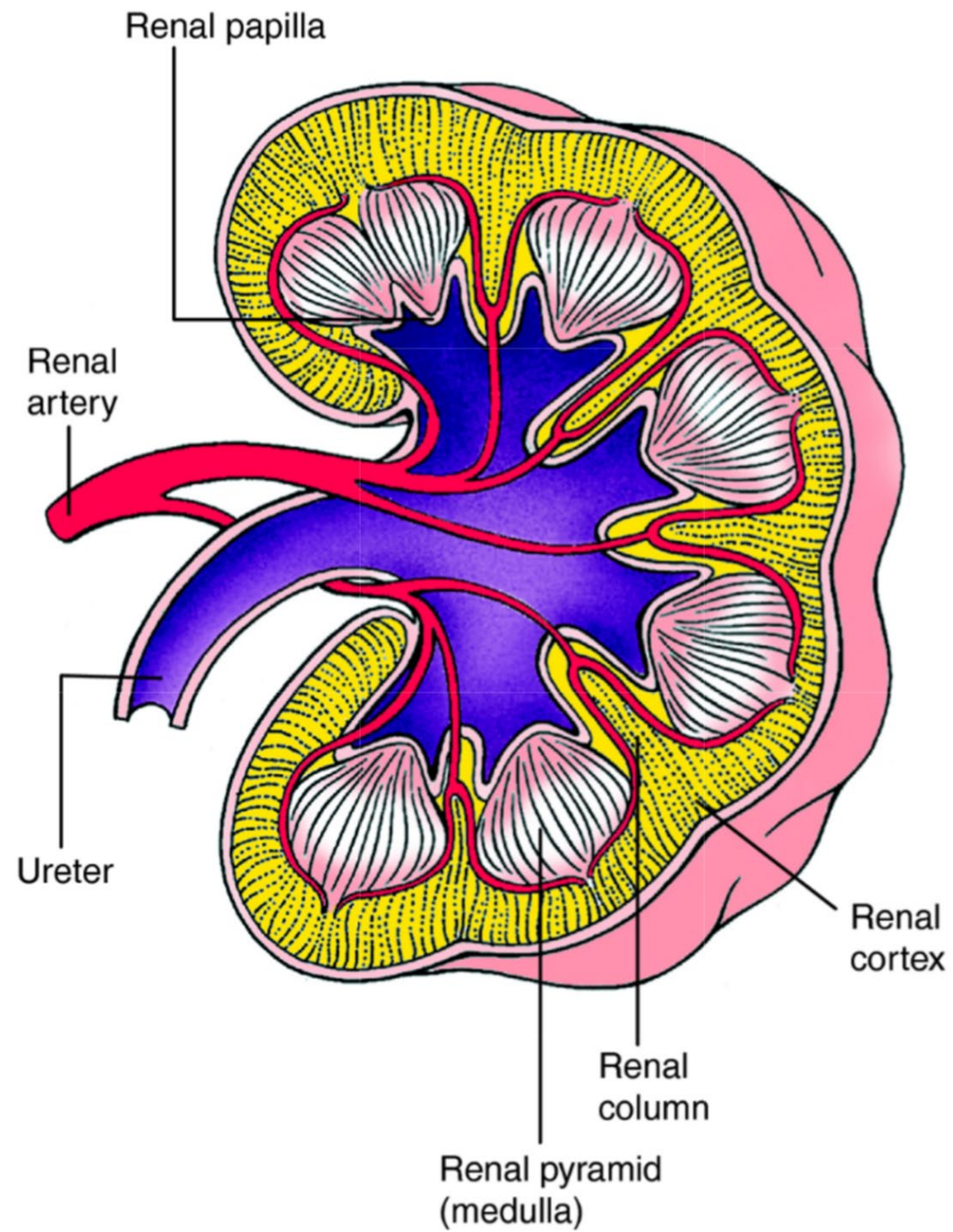


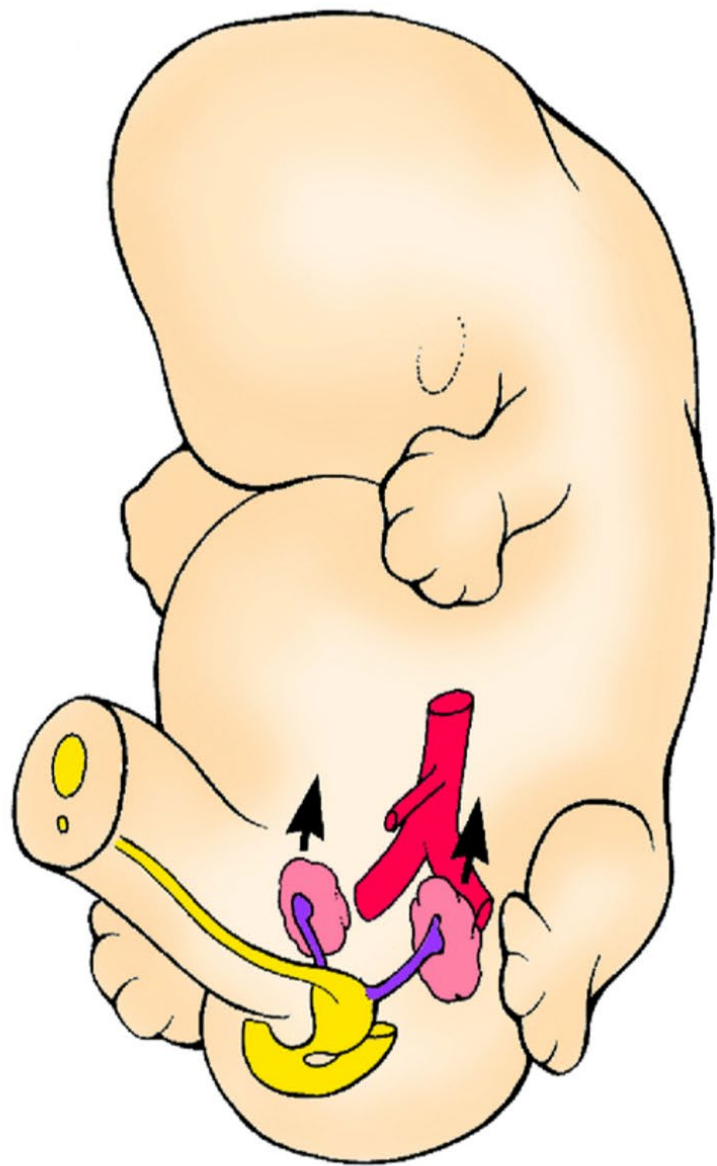




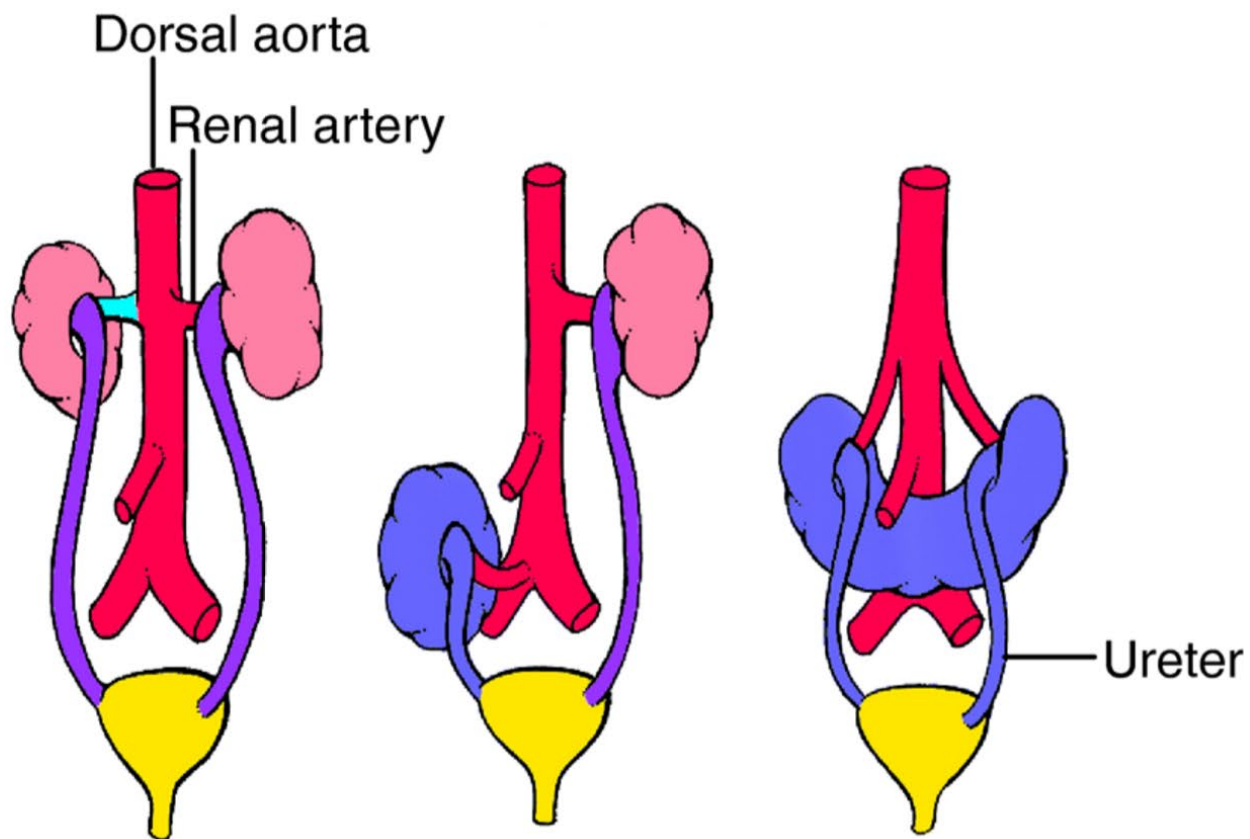








A 6th week

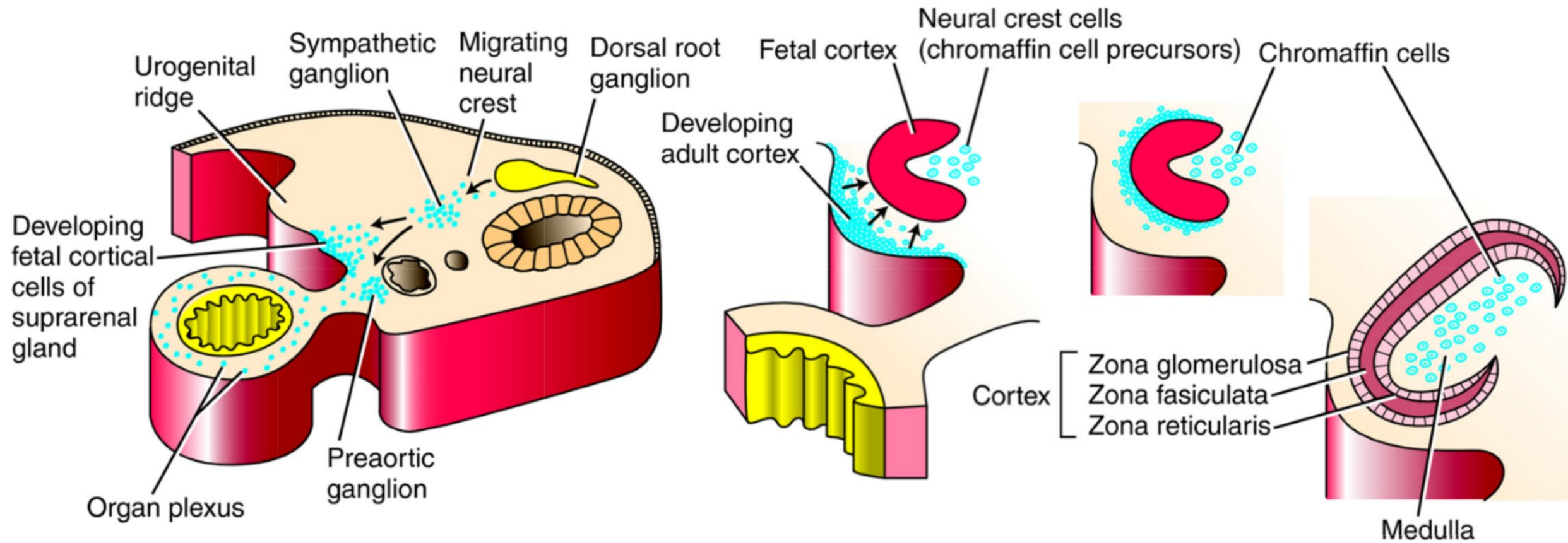


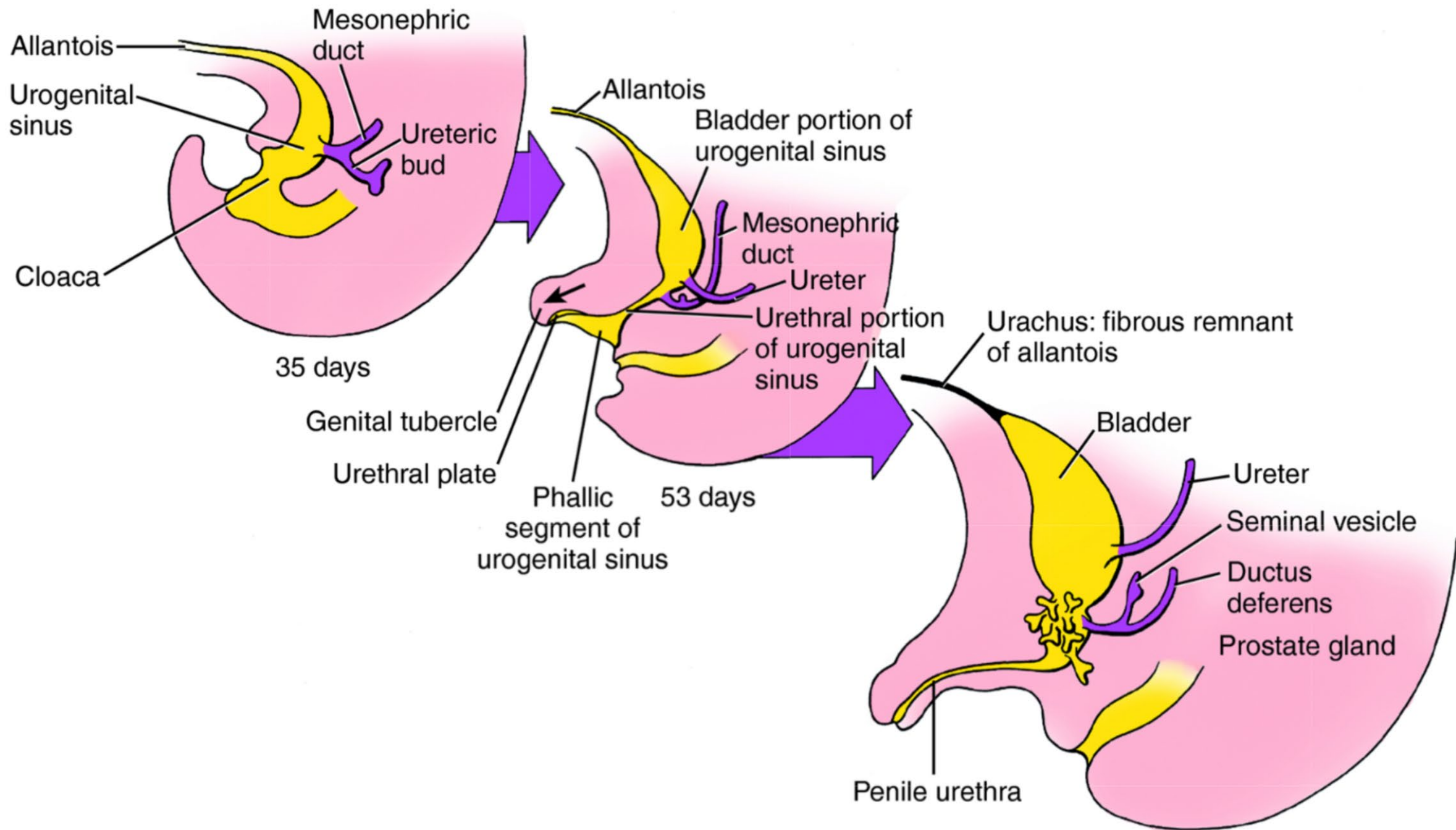
B Normal

C Pelvic kidney

D Horseshoe kidney







Allantois

Mesonephric duct

Urogenital sinus

Ureteric bud

Cloaca

35 days

Allantois

Bladder portion of urogenital sinus

Mesonephric duct

Ureter

Urethral portion of urogenital sinus

Genital tubercle

Urethral plate

Phallic segment of urogenital sinus

53 days

Urachus: fibrous remnant of allantois

Bladder

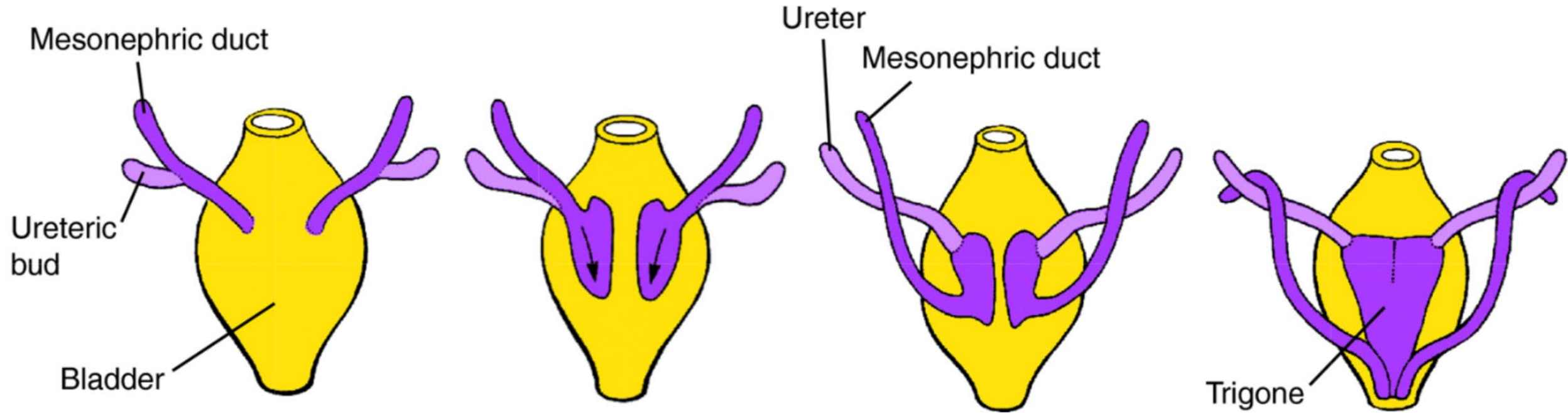
Ureter

Seminal vesicle

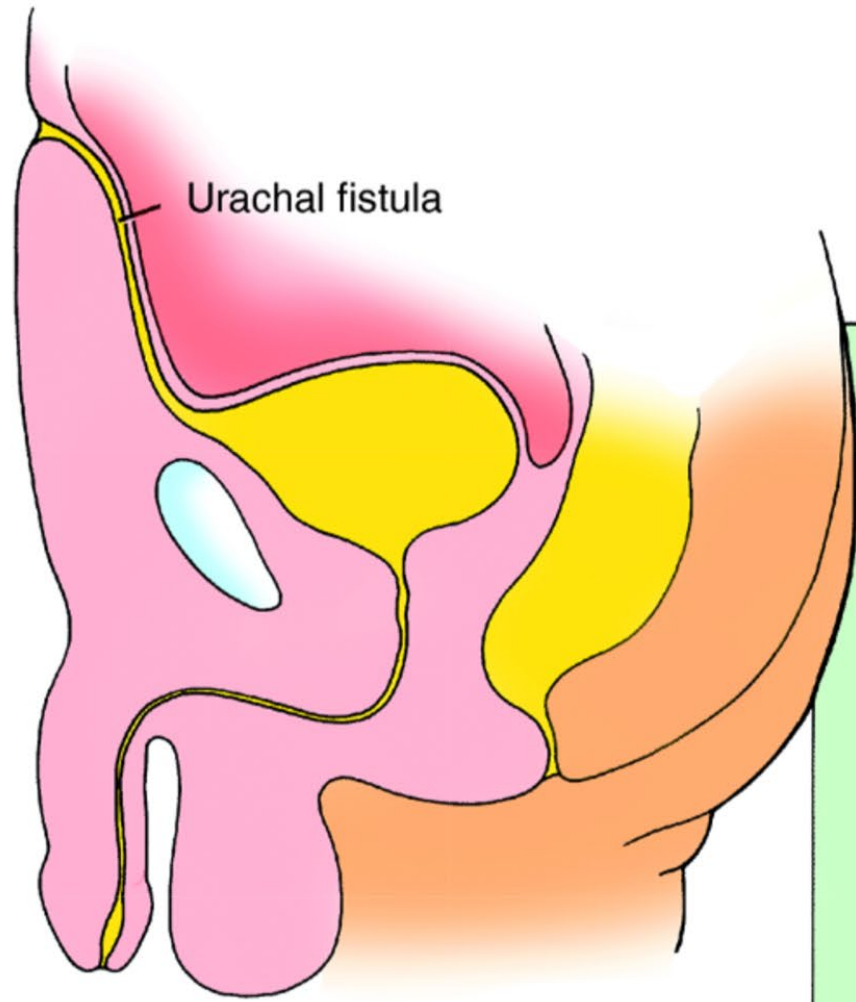
Ductus deferens

Prostate gland

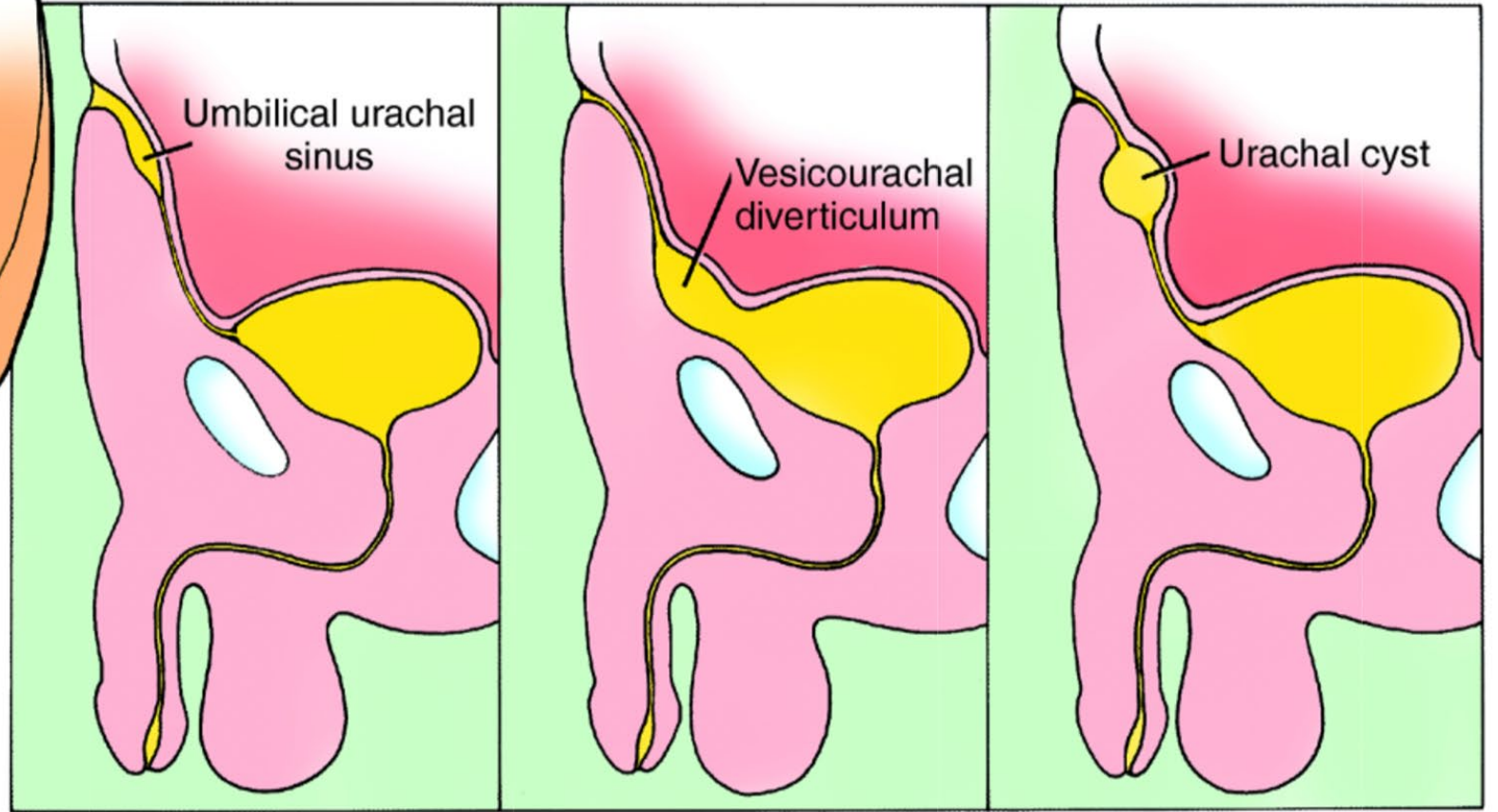
Penile urethra







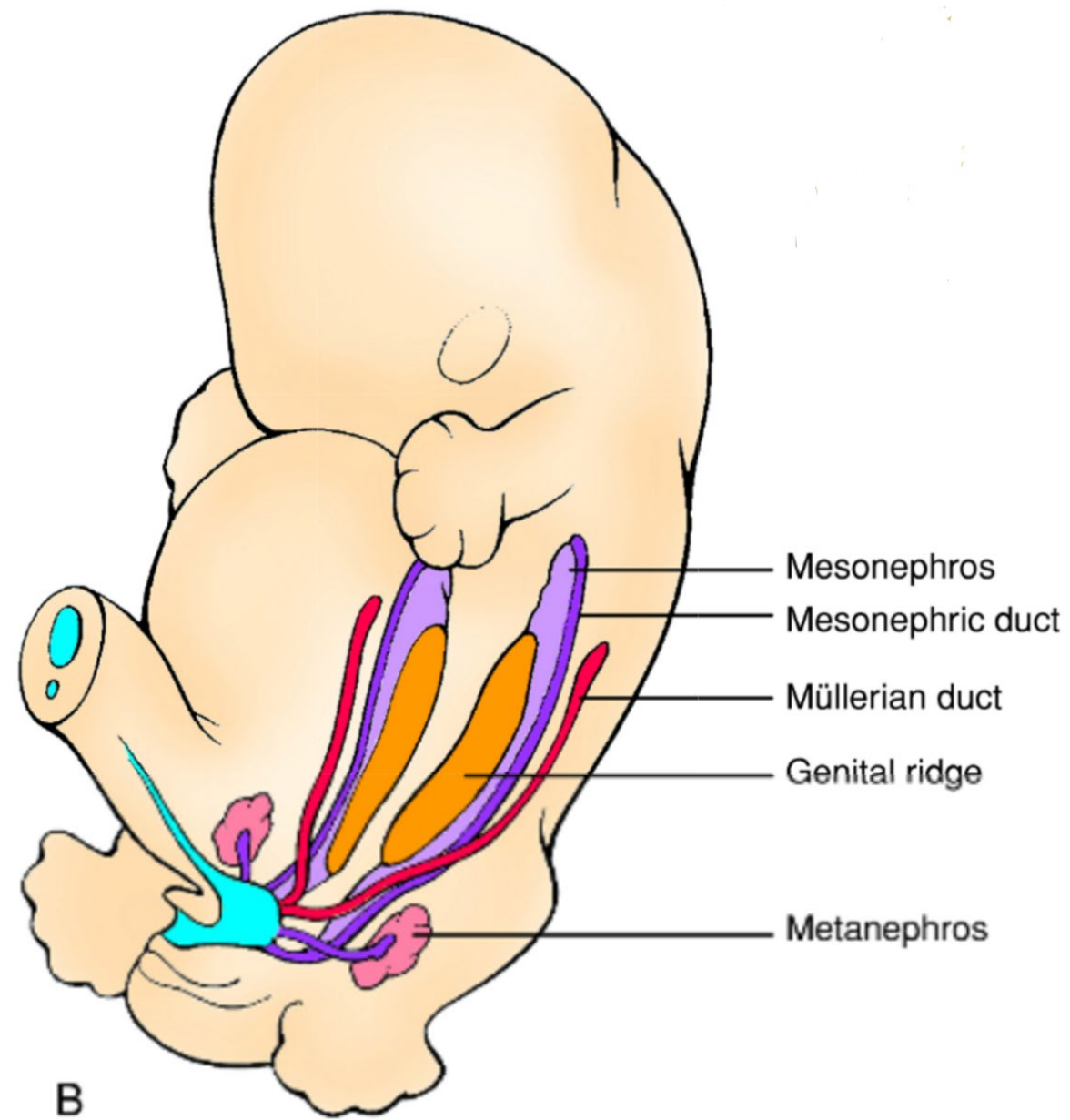
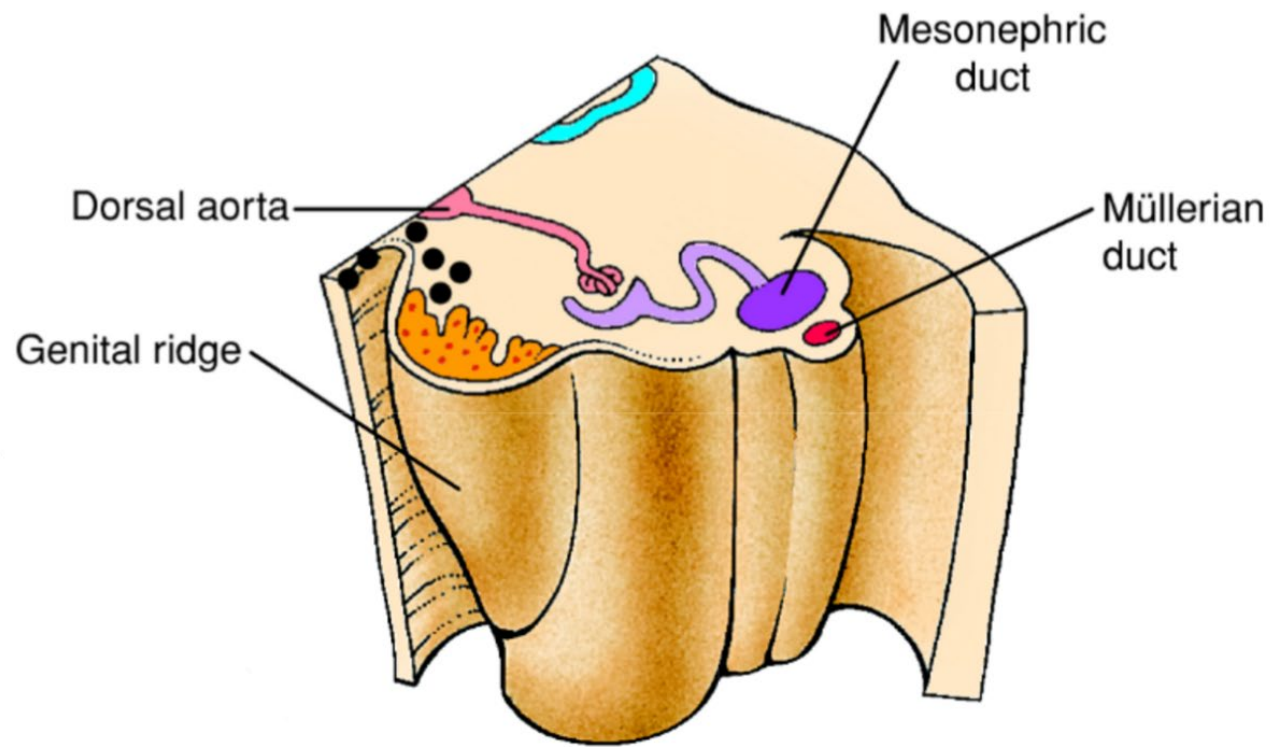
A

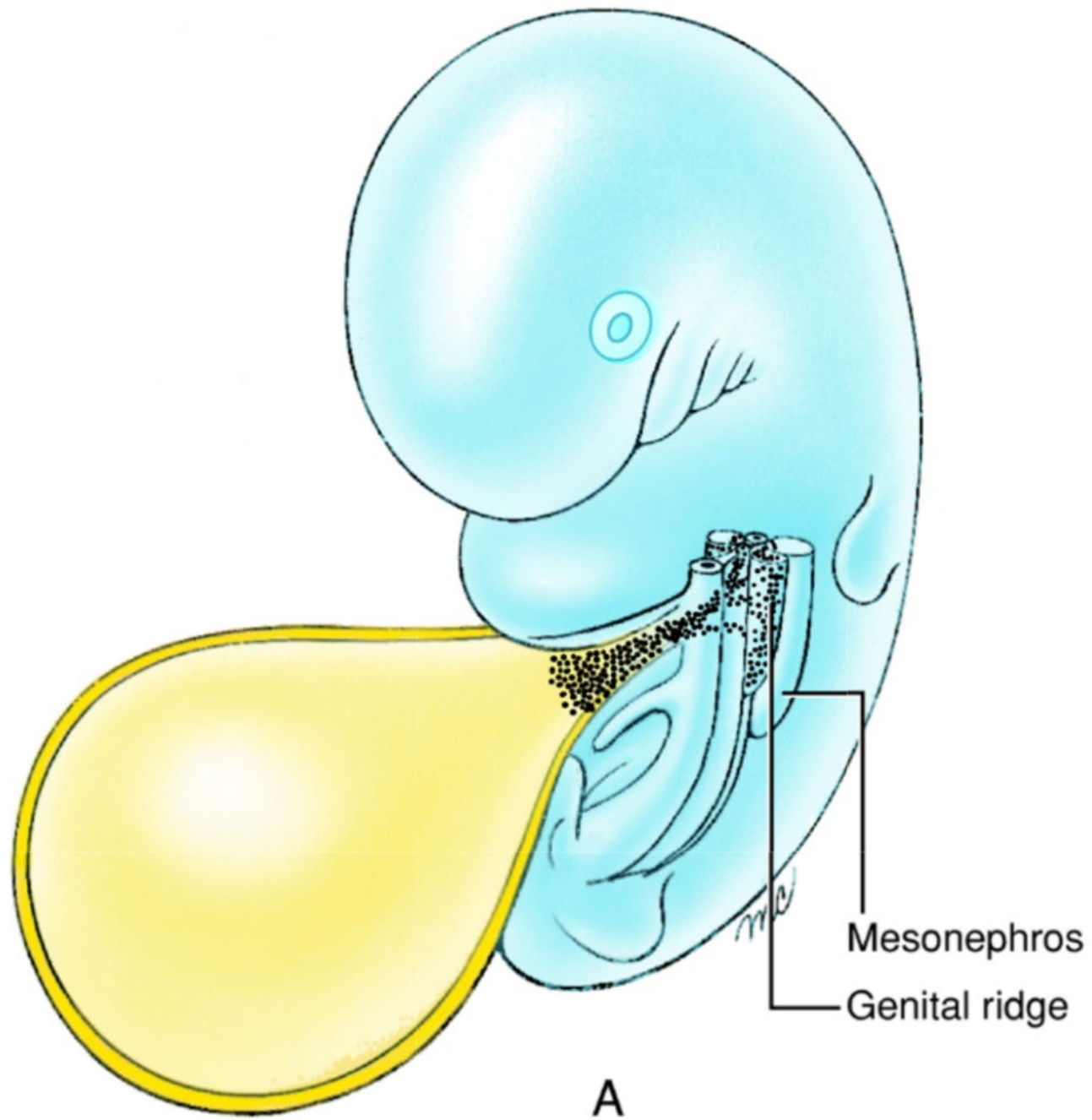


B

C

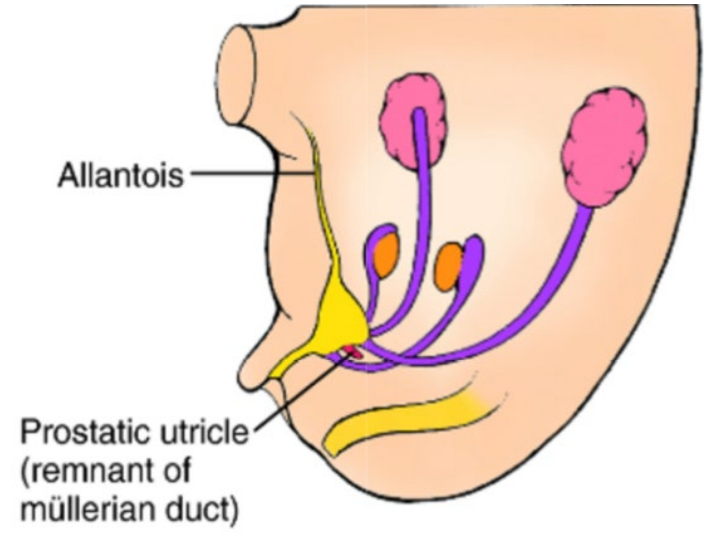
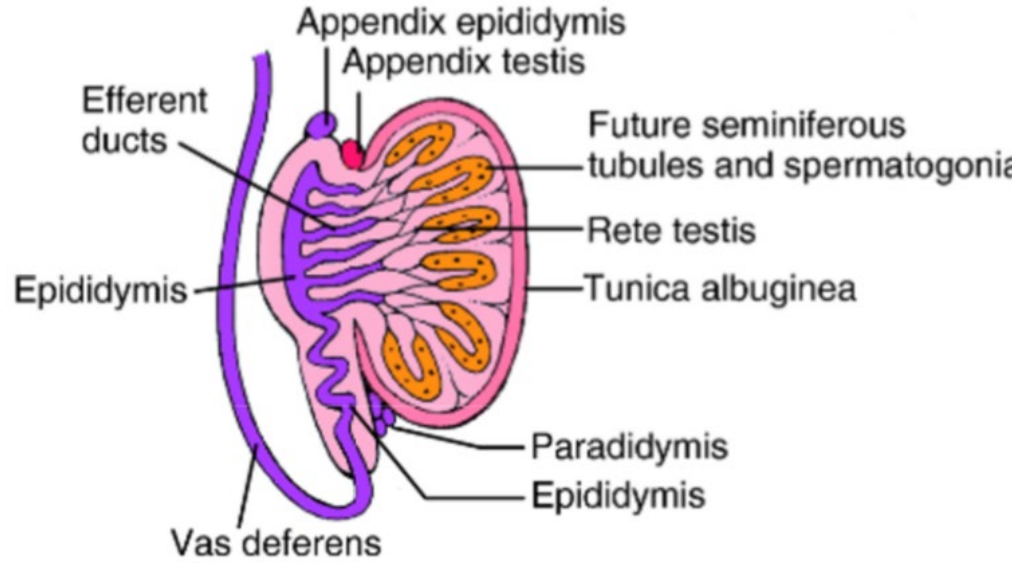
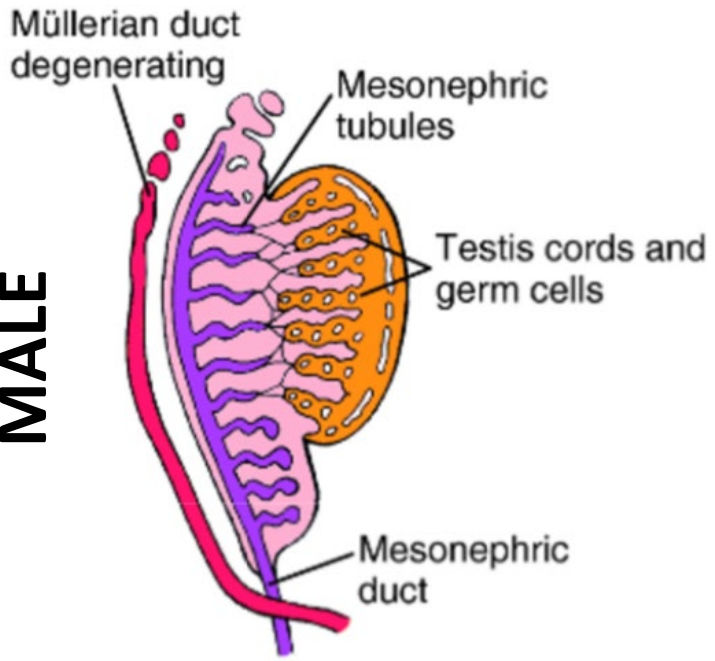
D



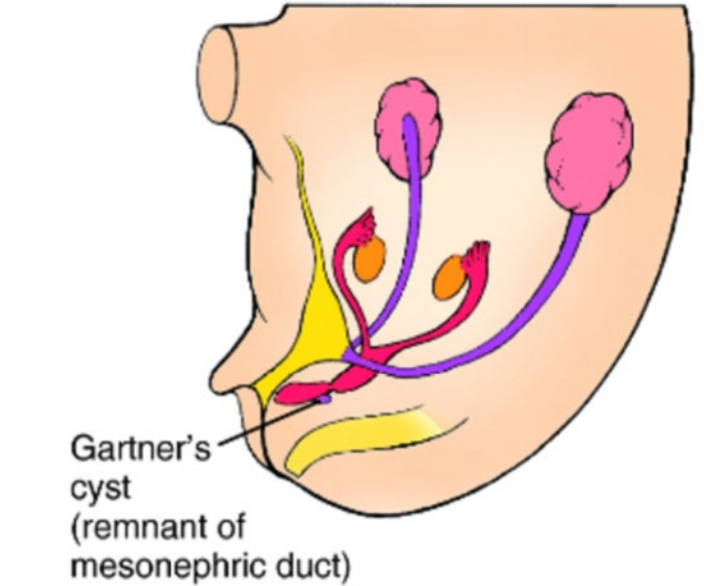
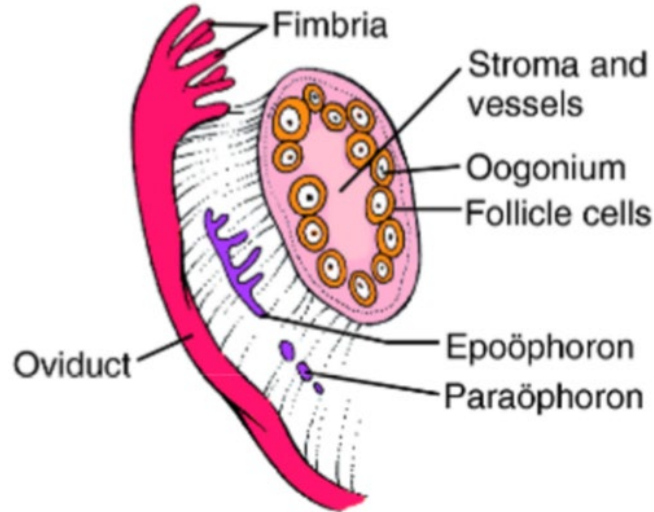
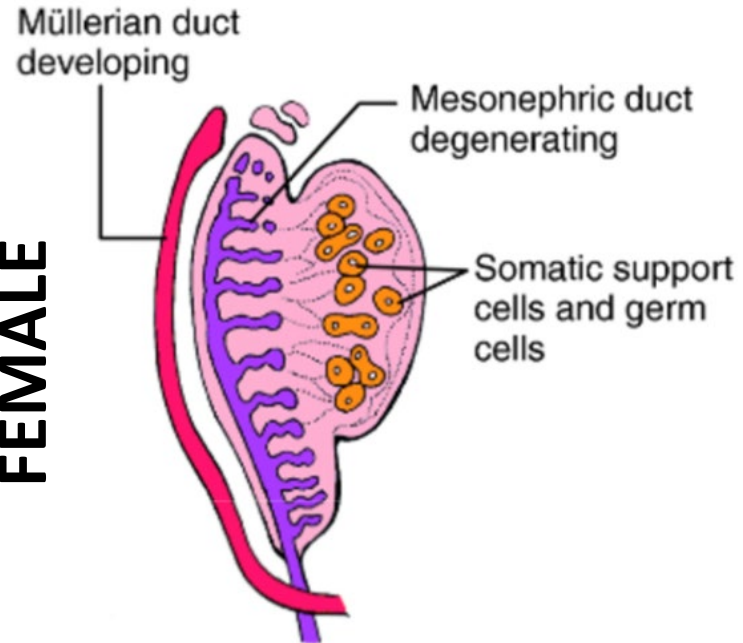


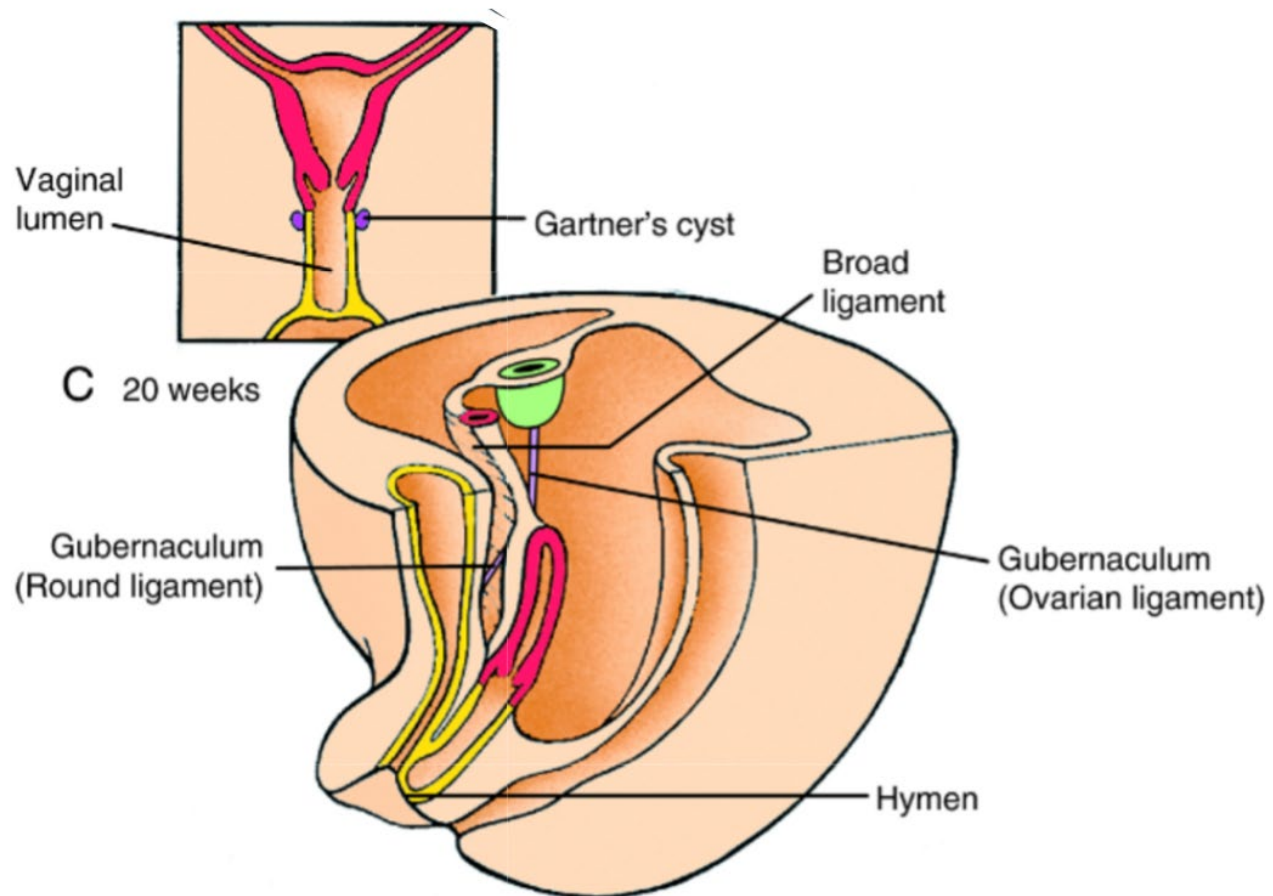
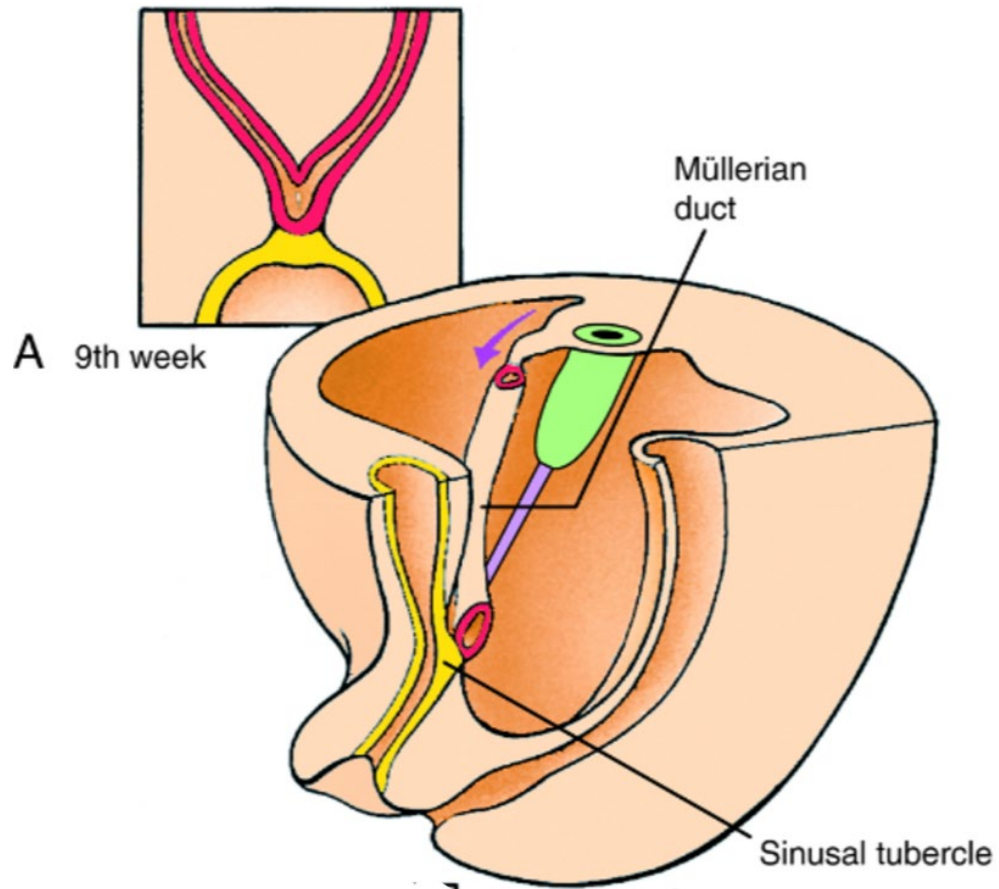


**MALE**

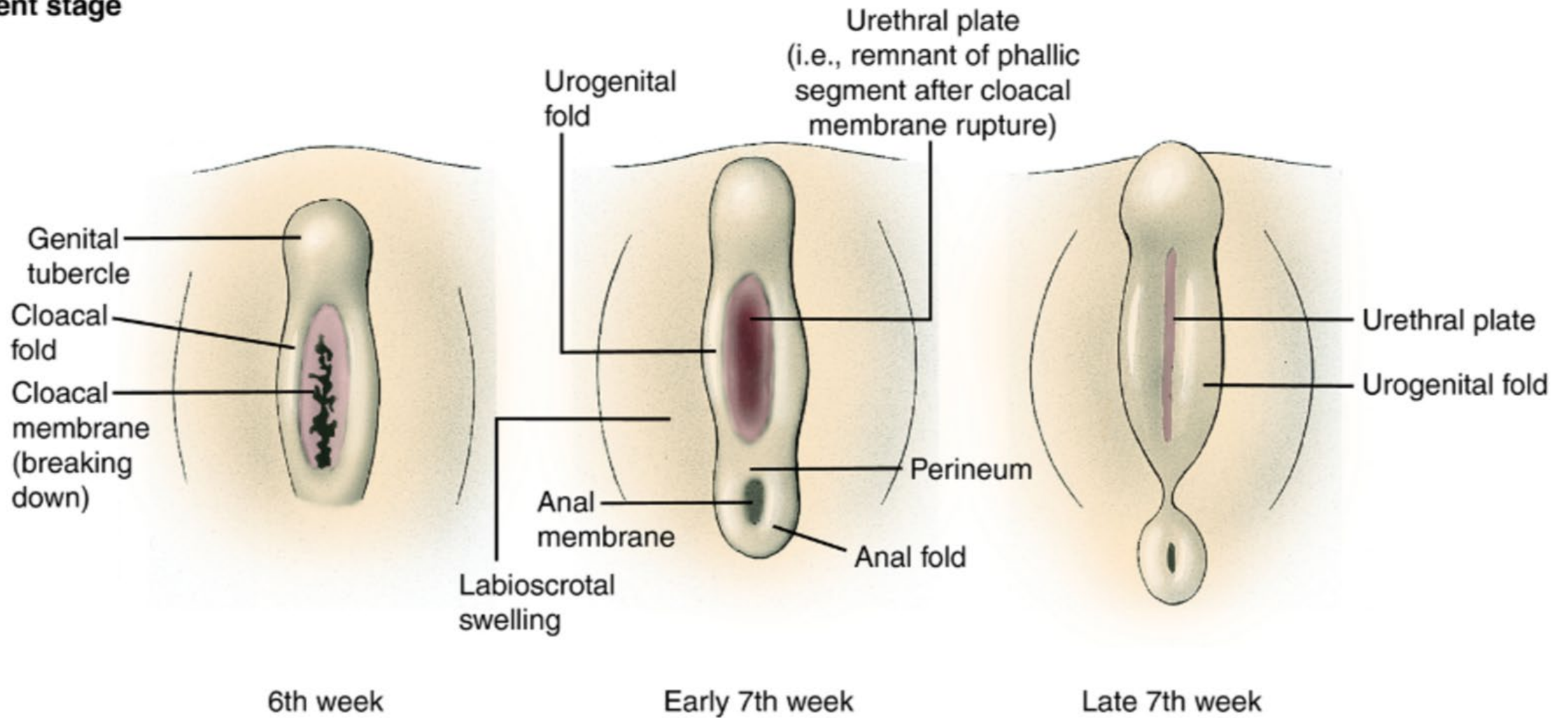


**FEMALE**



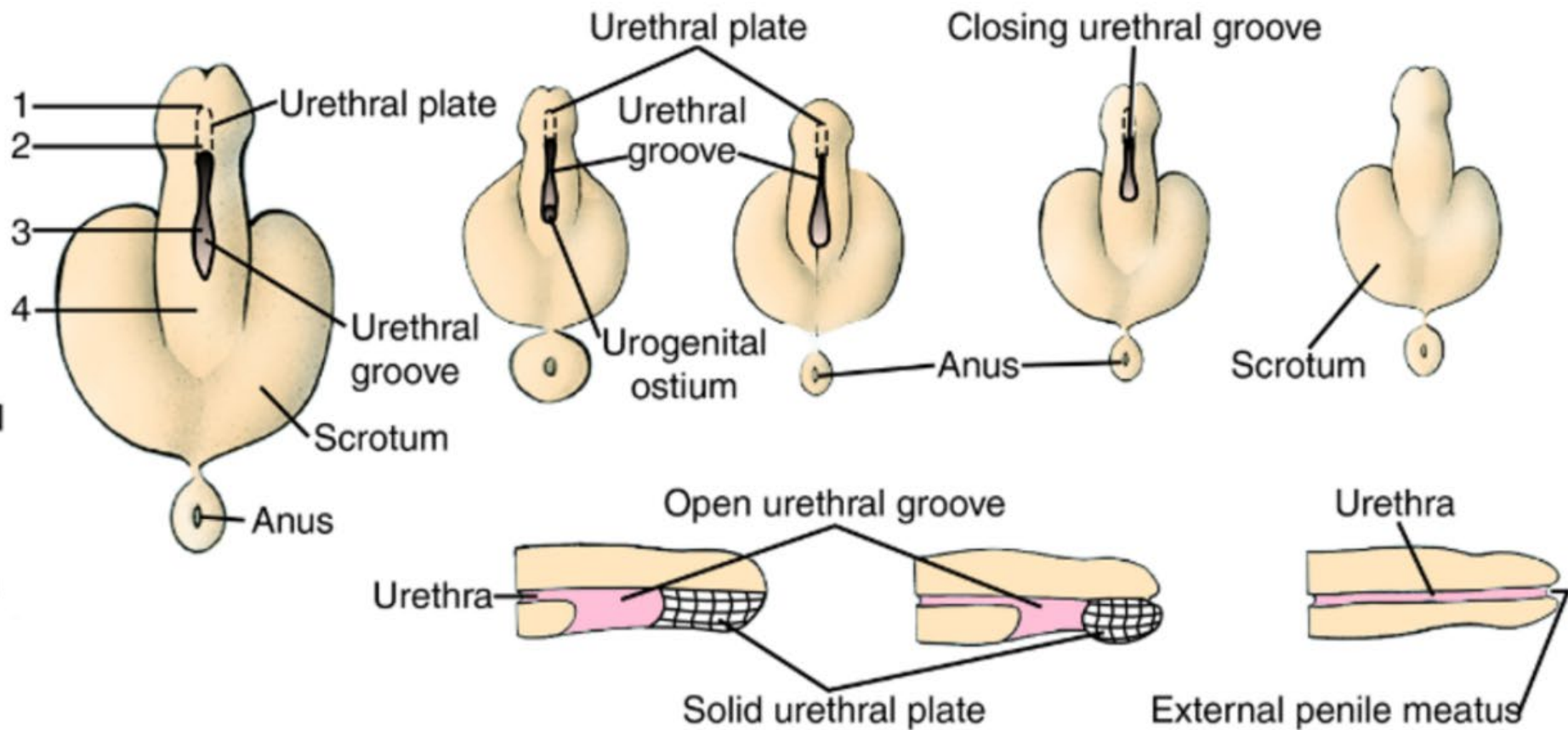
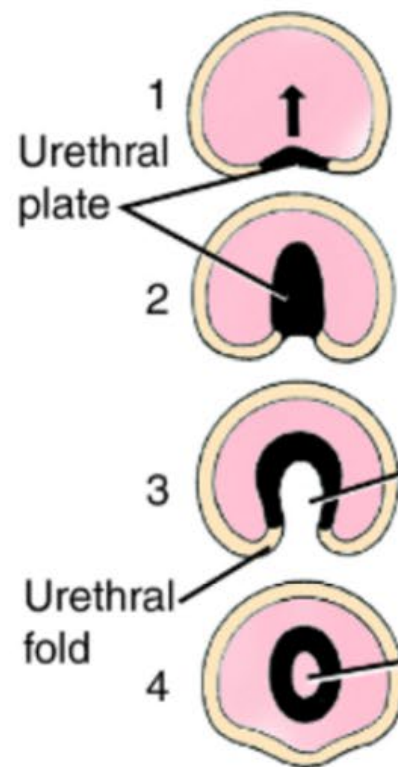


**Indifferent stage**



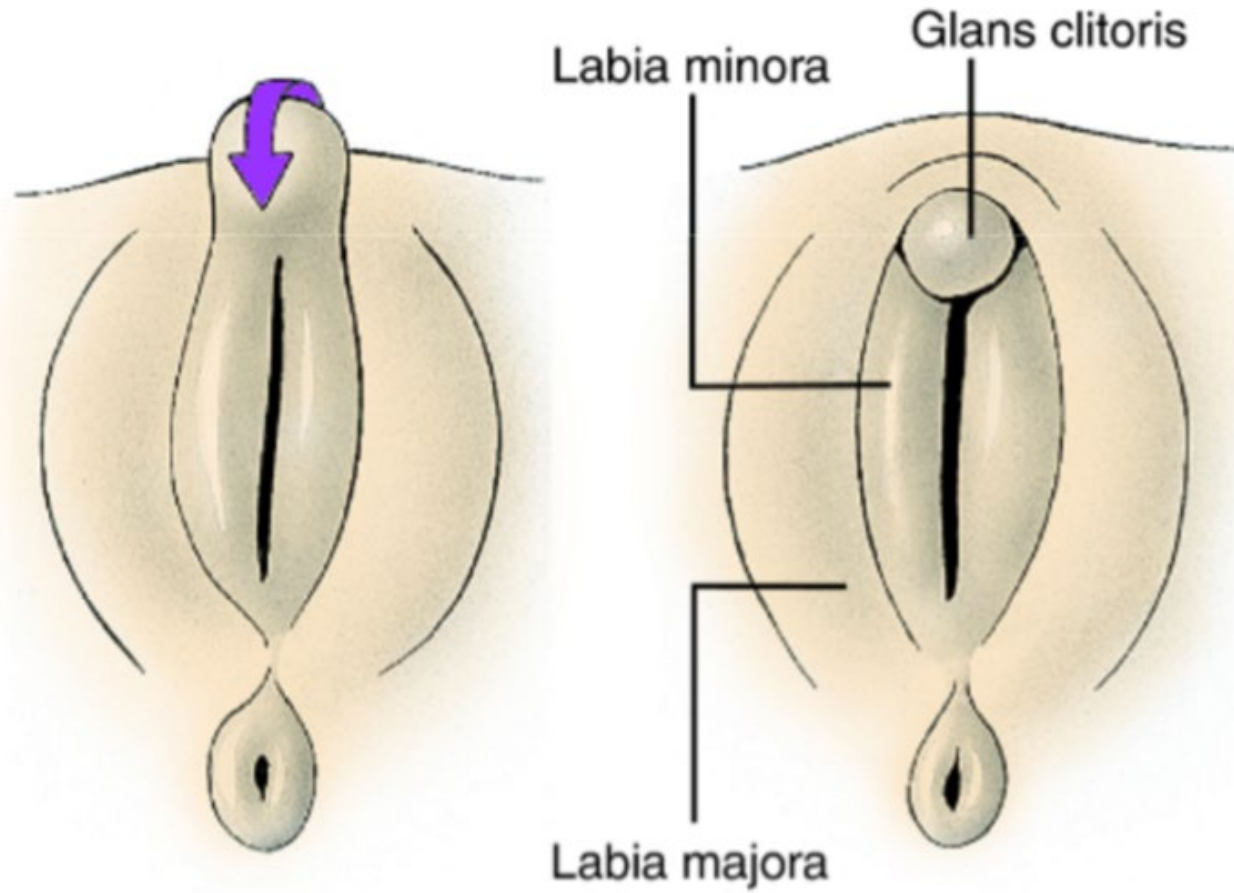


**Male**



**B**

**Female**

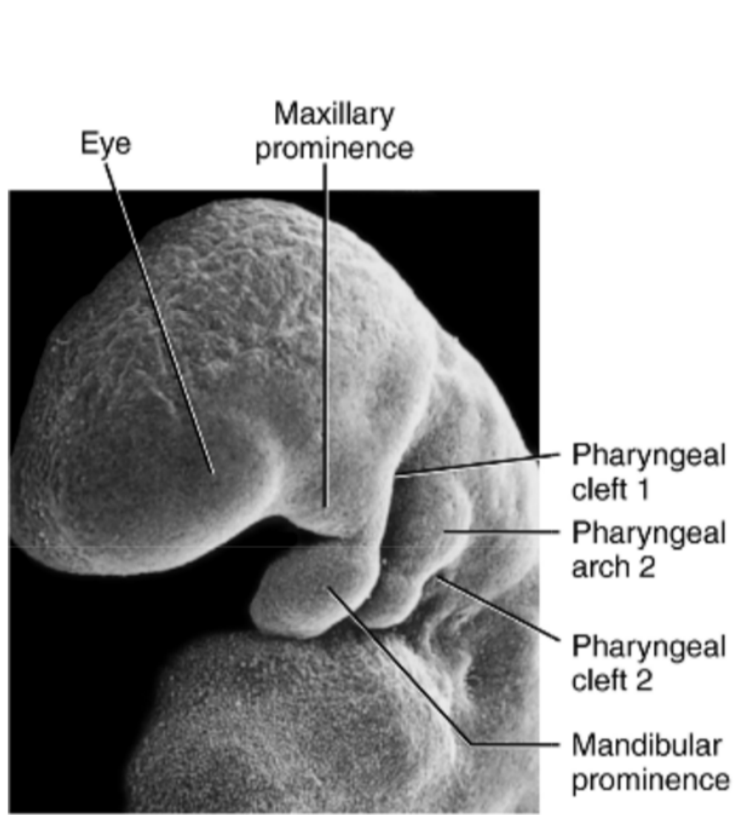


**C**

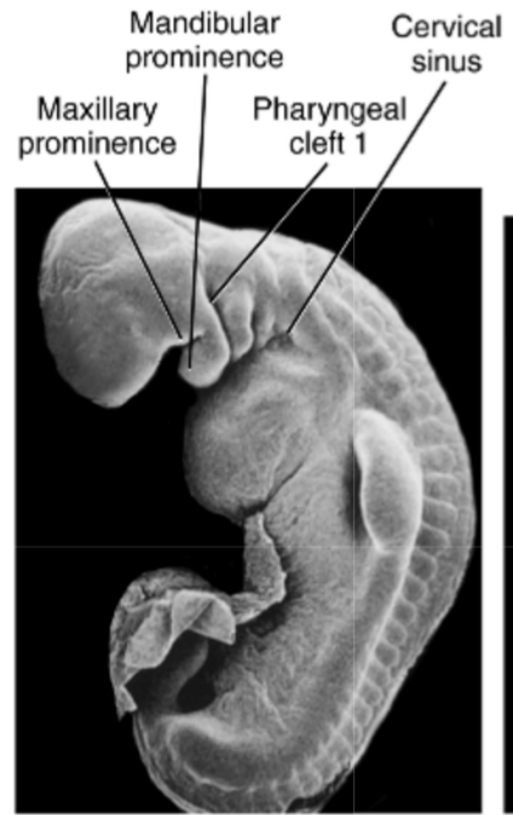
# Overview

1. Early embryonic development
2. Central nervous system development
3. Endodermal tube formation and derivatives
4. Urogenital system development
5. **Branchial cleft derivatives**
6. Cardiac and vasculature development

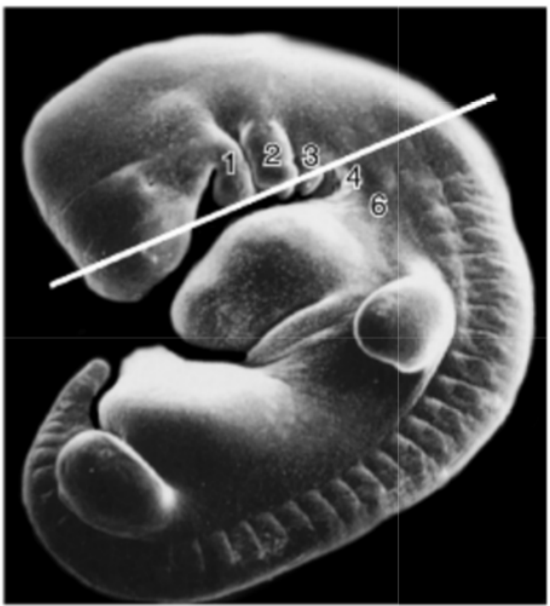




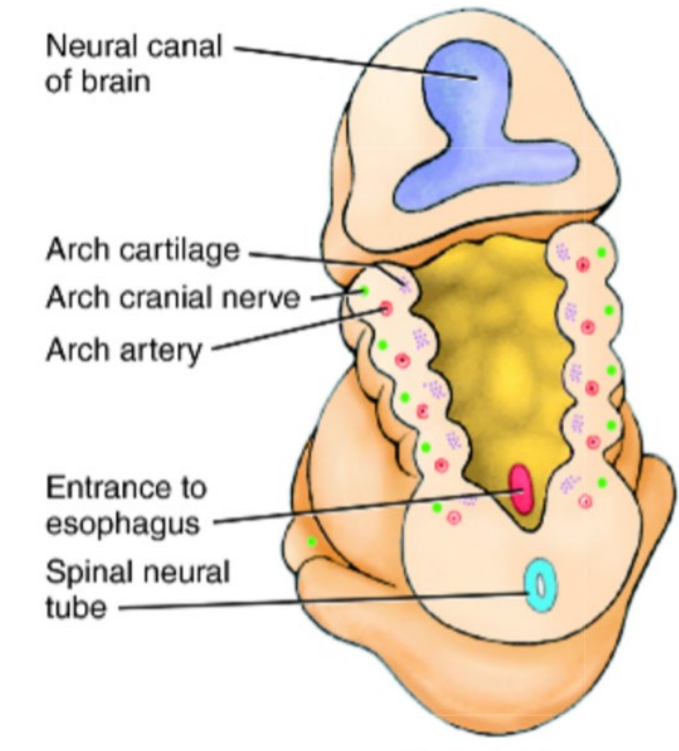
A 24 days



B 27 days

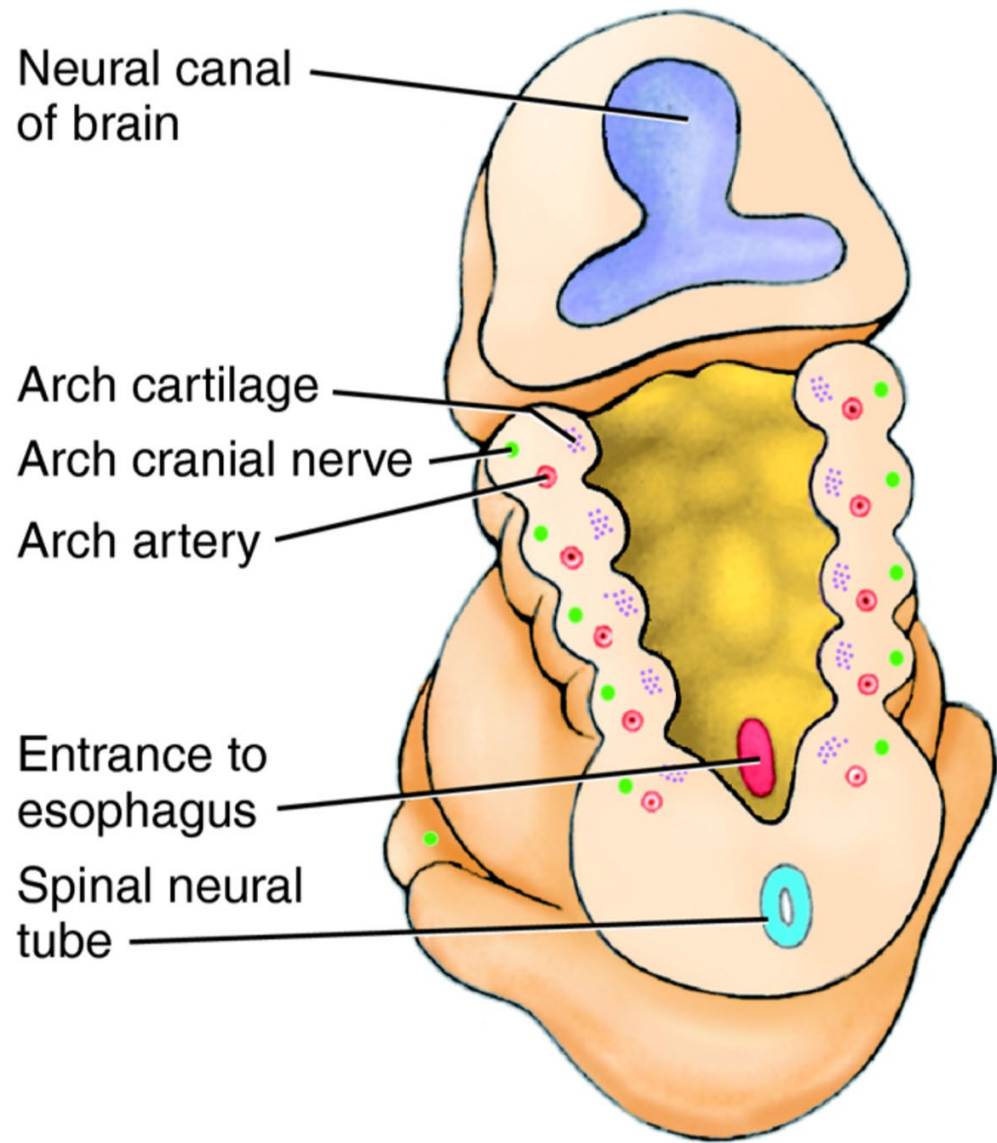


C 31 days



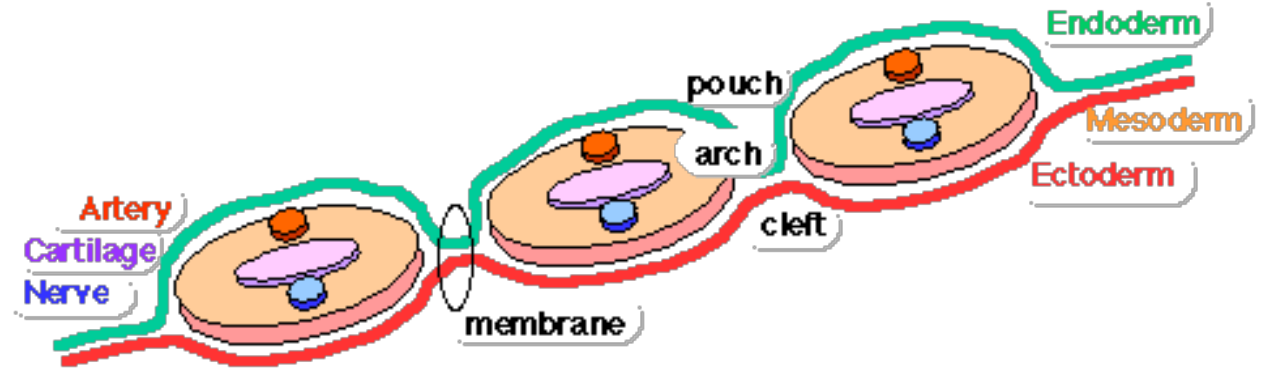
D 29 days

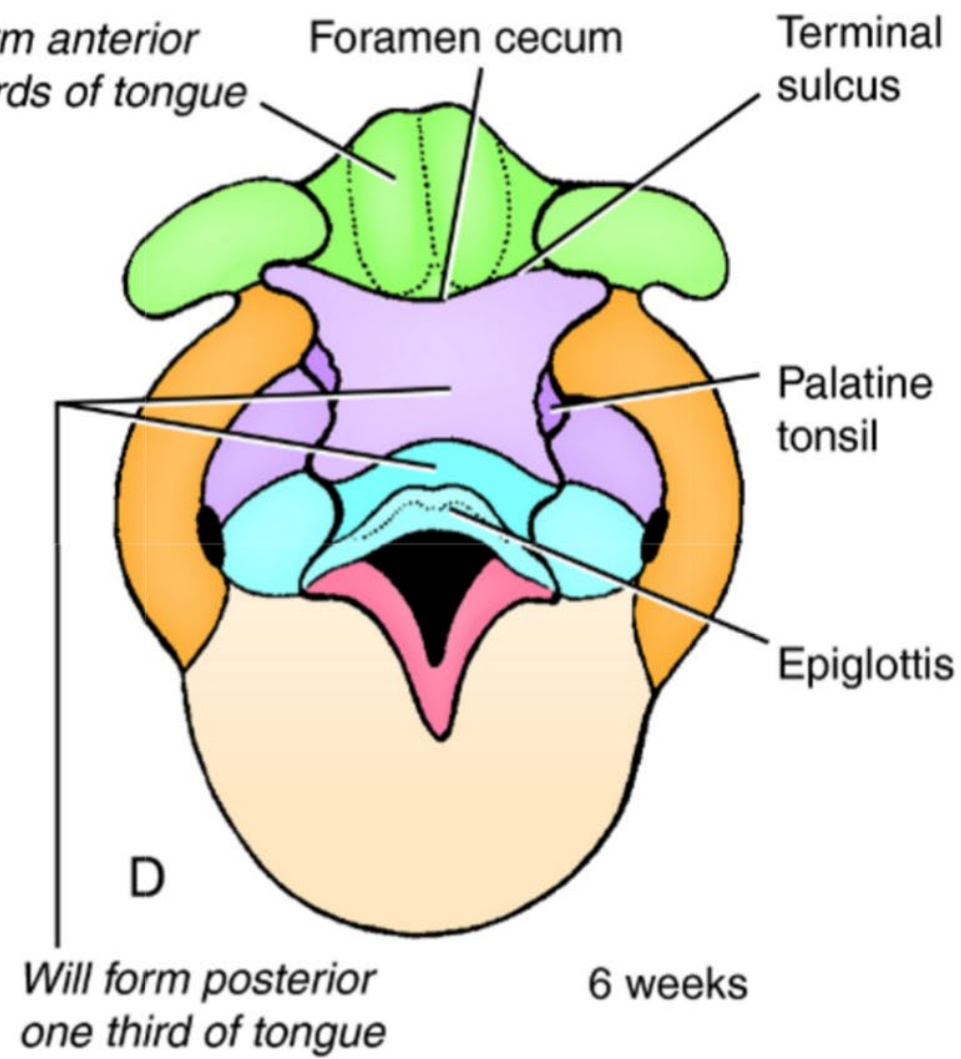
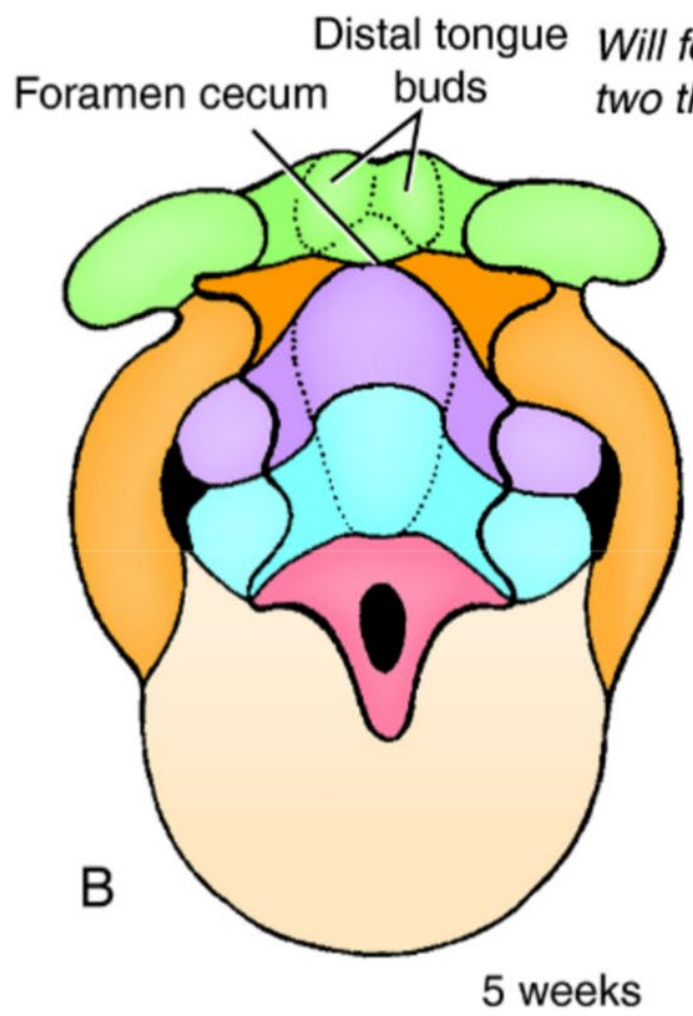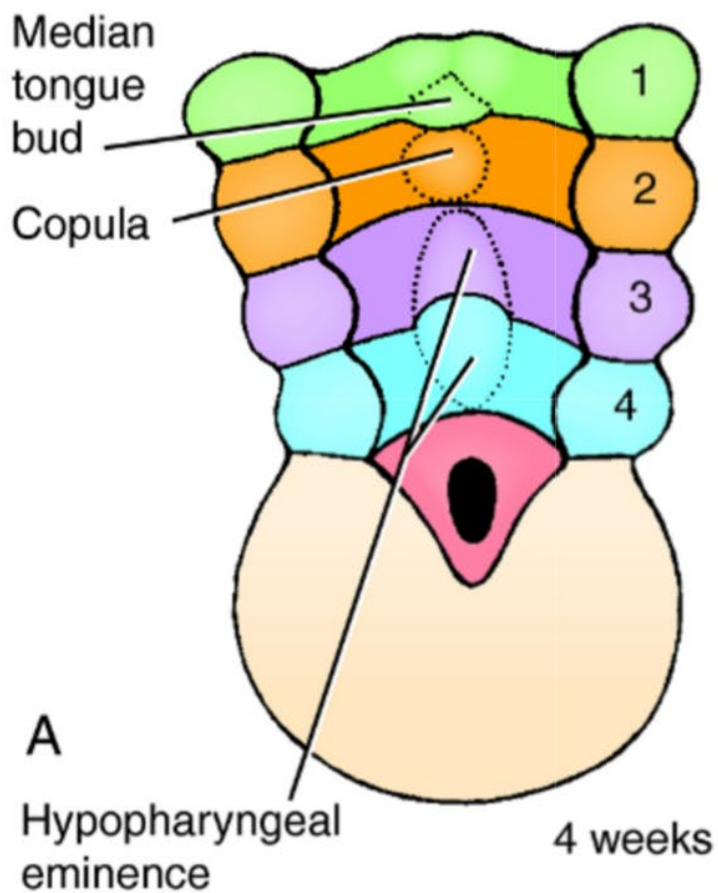
Dorsal side



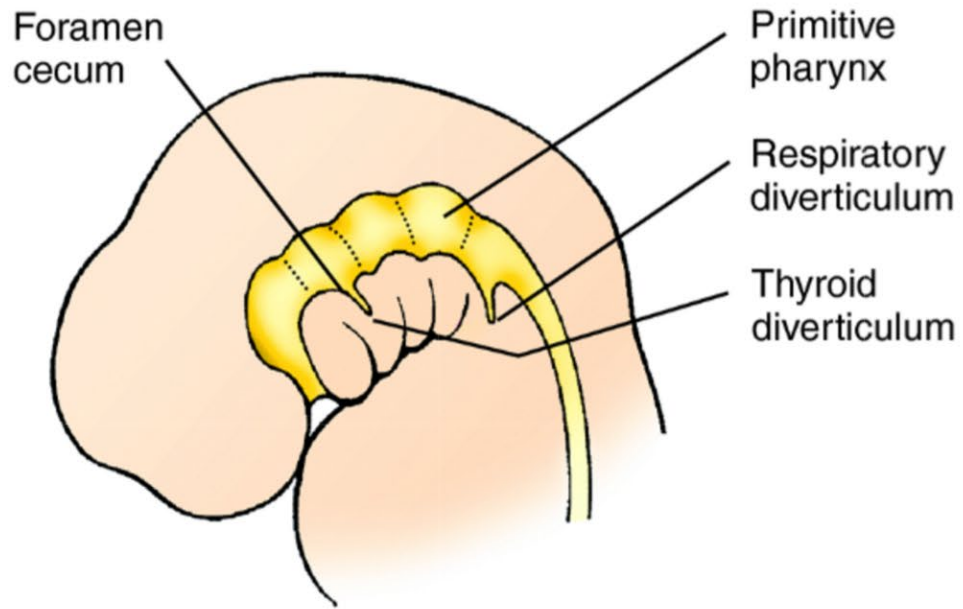
Dorsal side

D 29 days

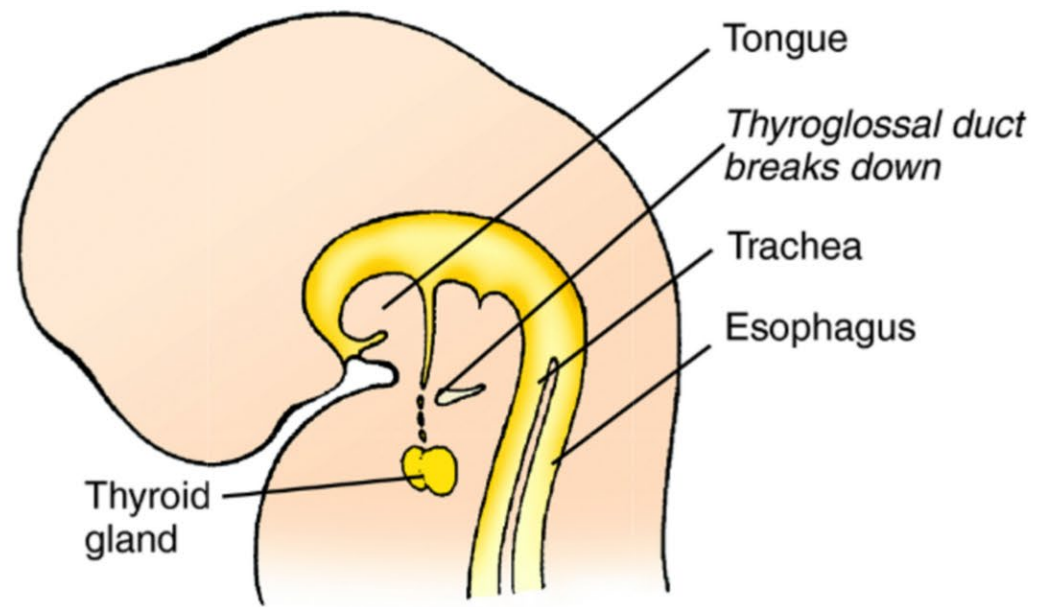




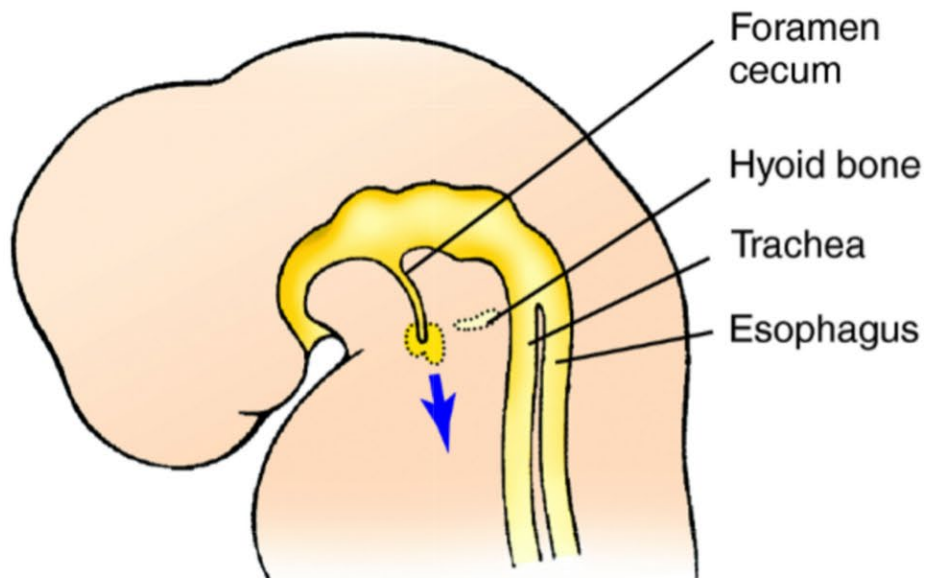




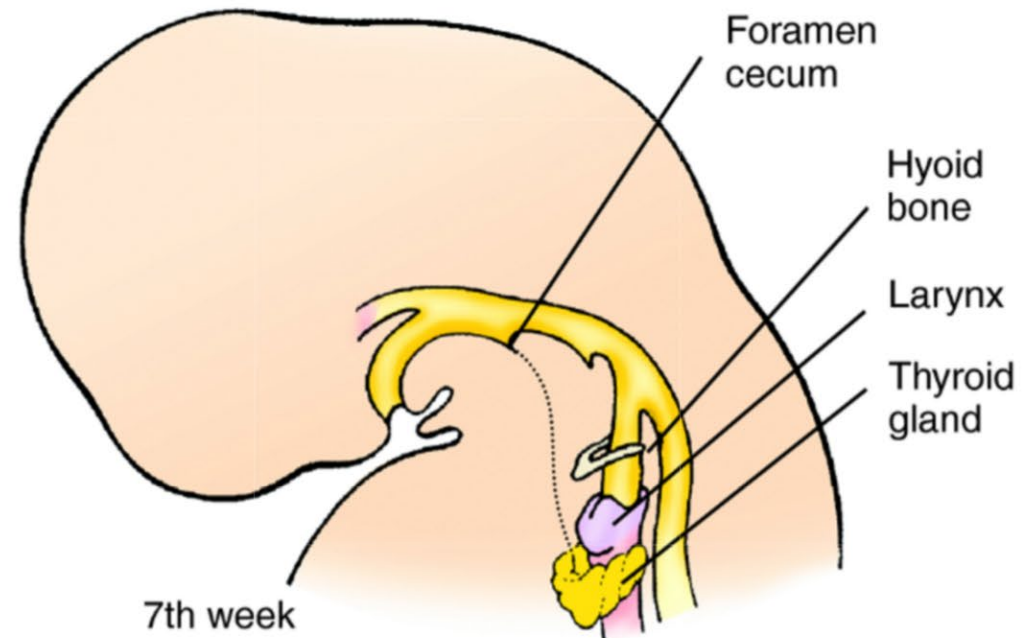
4th week



Late 5th week



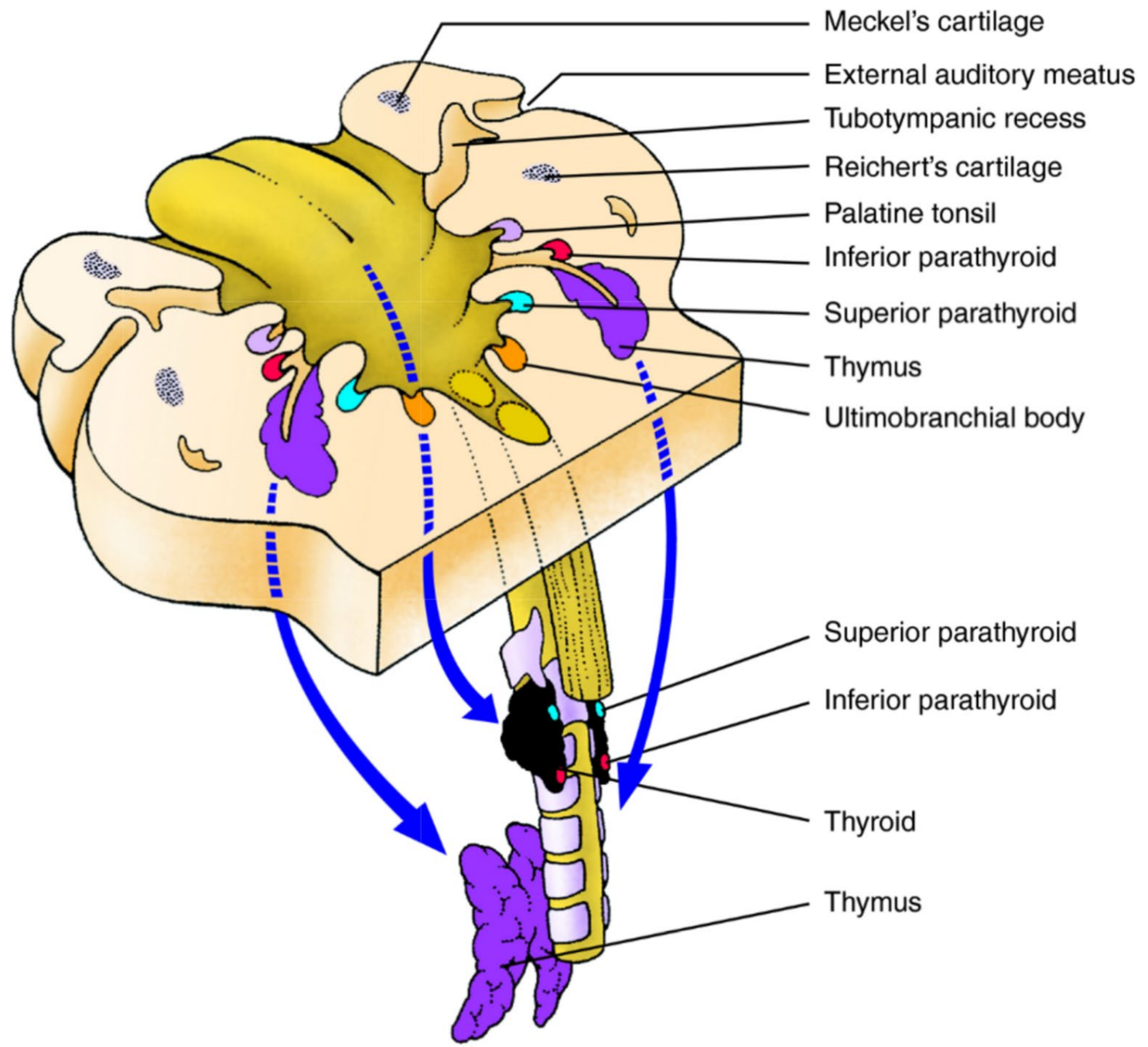
Early 5th week


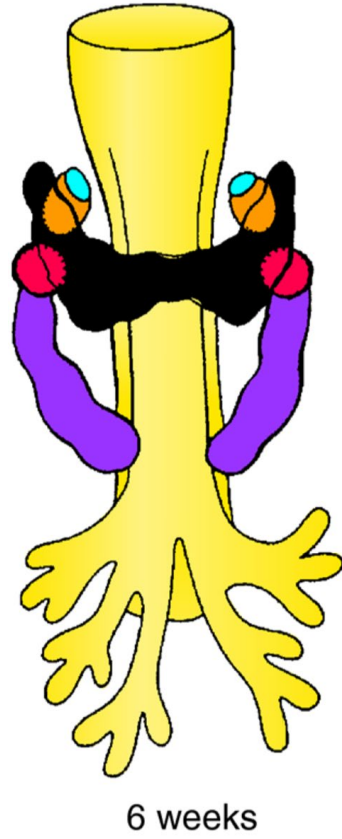



7th week

Late 5th week

7th week

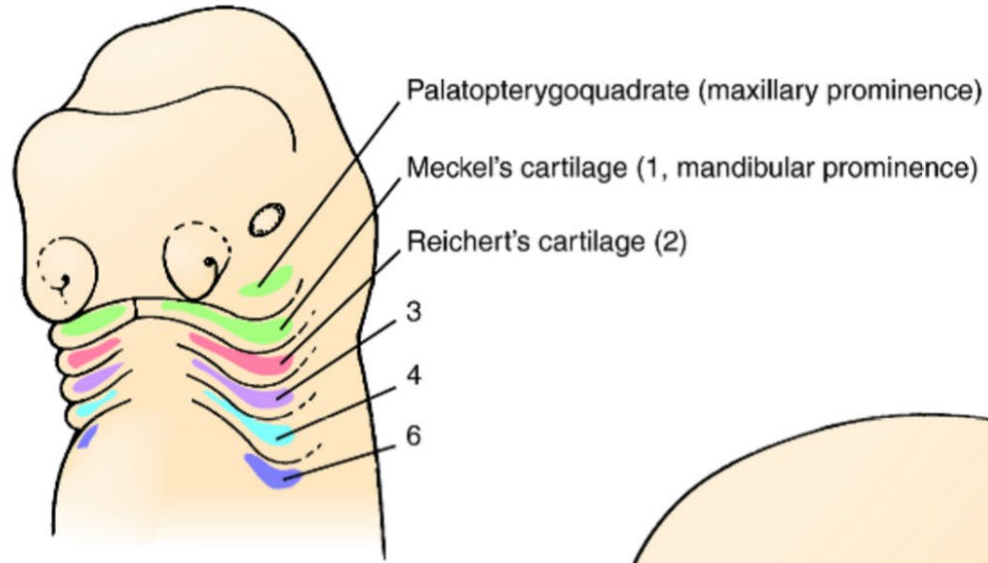




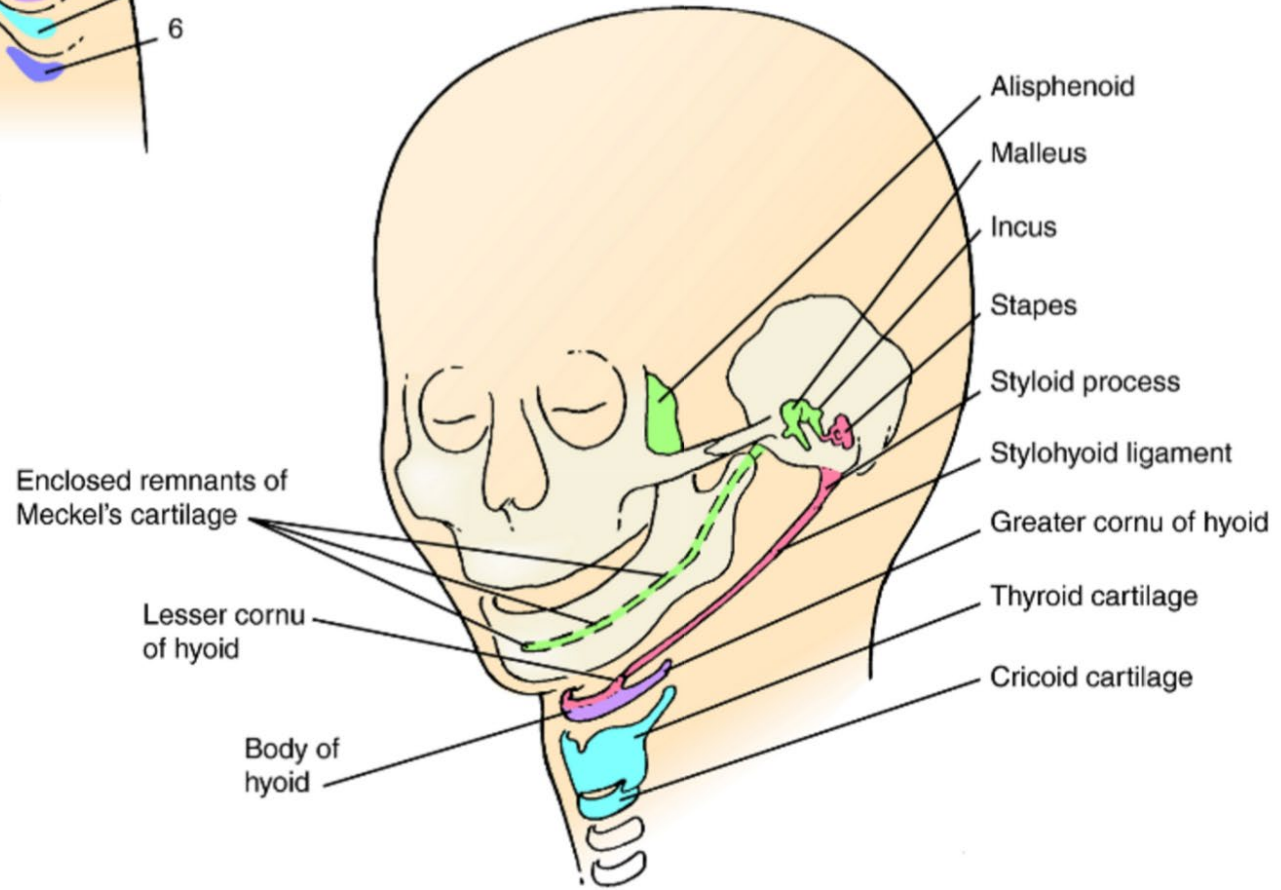
- Parathyroid III (inferior)
- Parathyroid IV (superior)
- Ultimobranchial body
- Thymus
- Thyroid



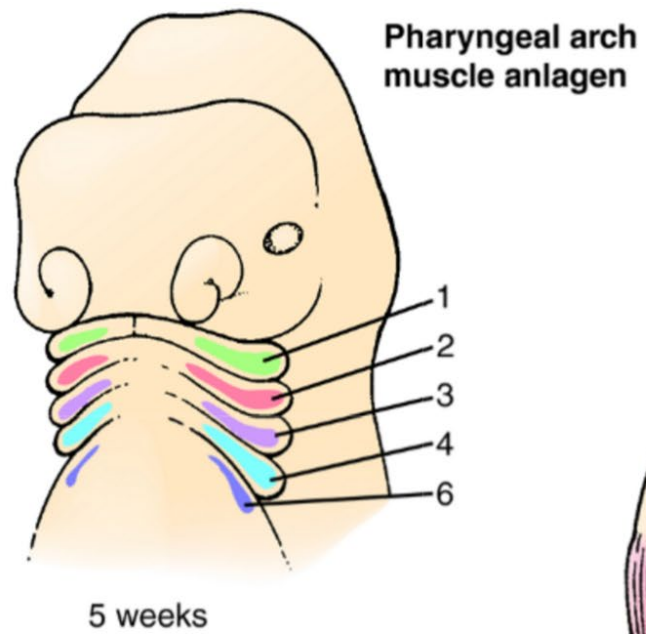
### Pharyngeal arch cartilages



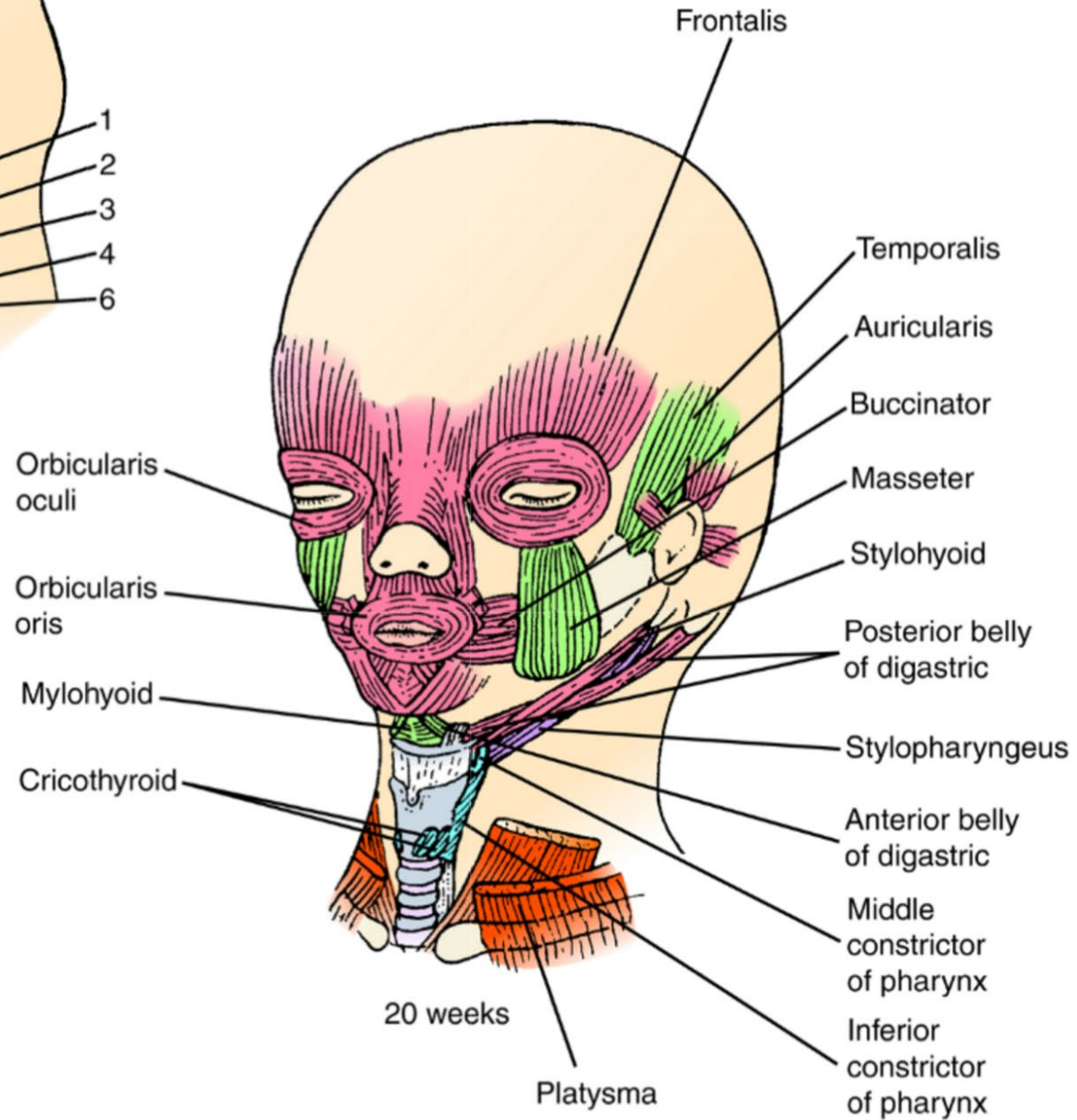
5 weeks

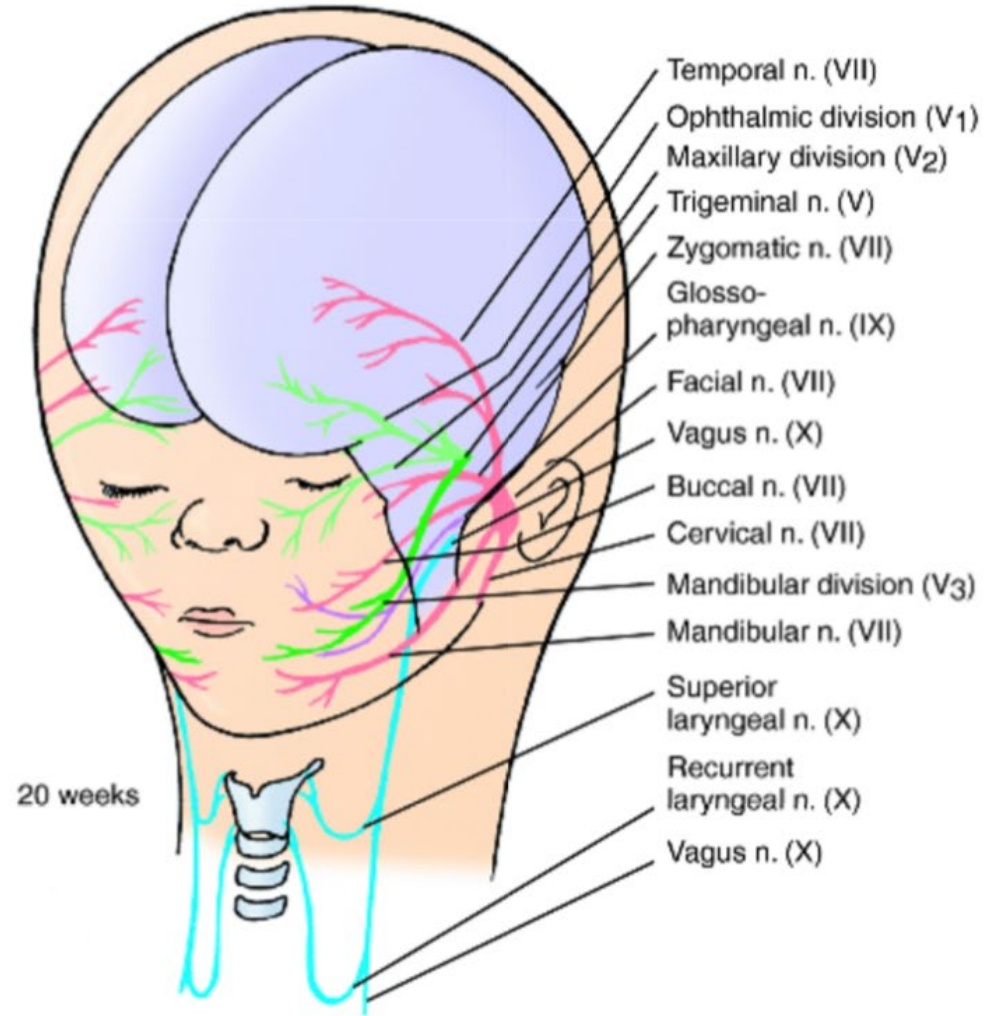
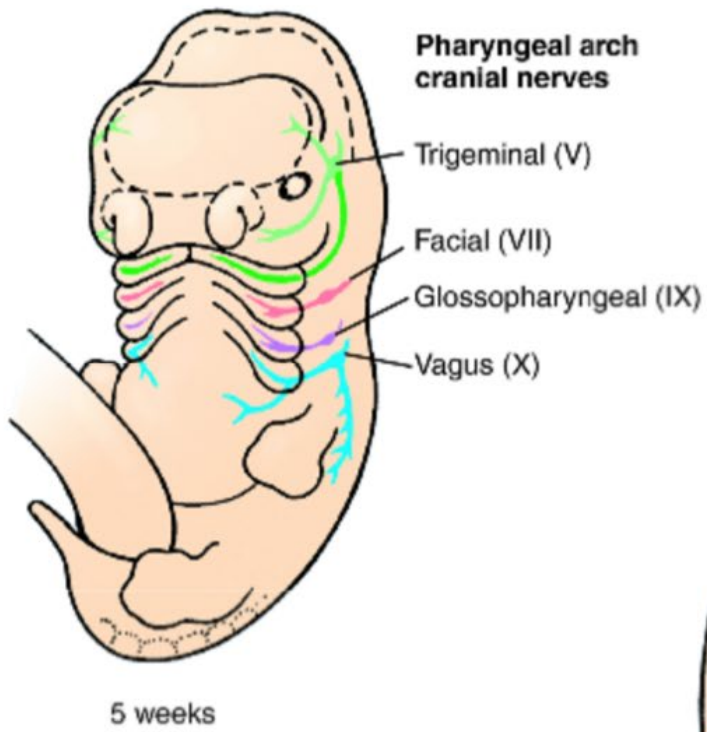


20 weeks

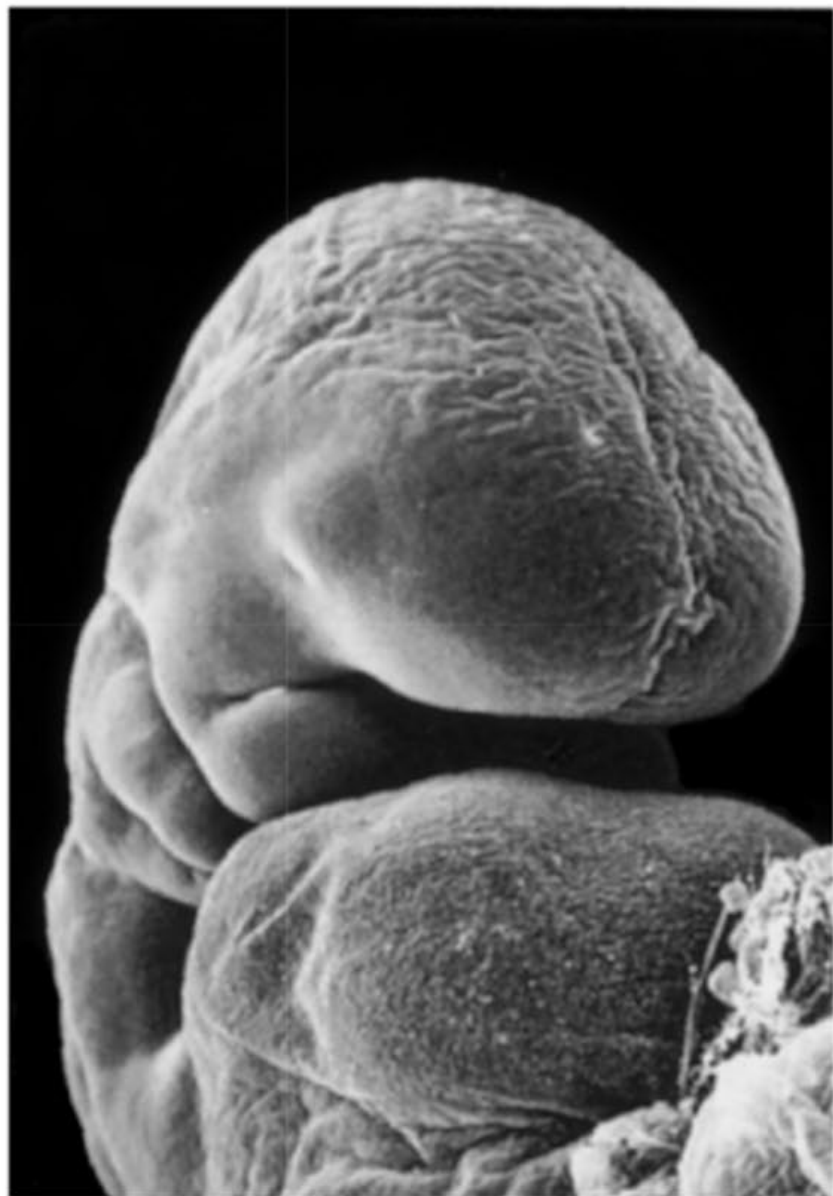


5 weeks









B

4th week

Frontonasal  
prominence

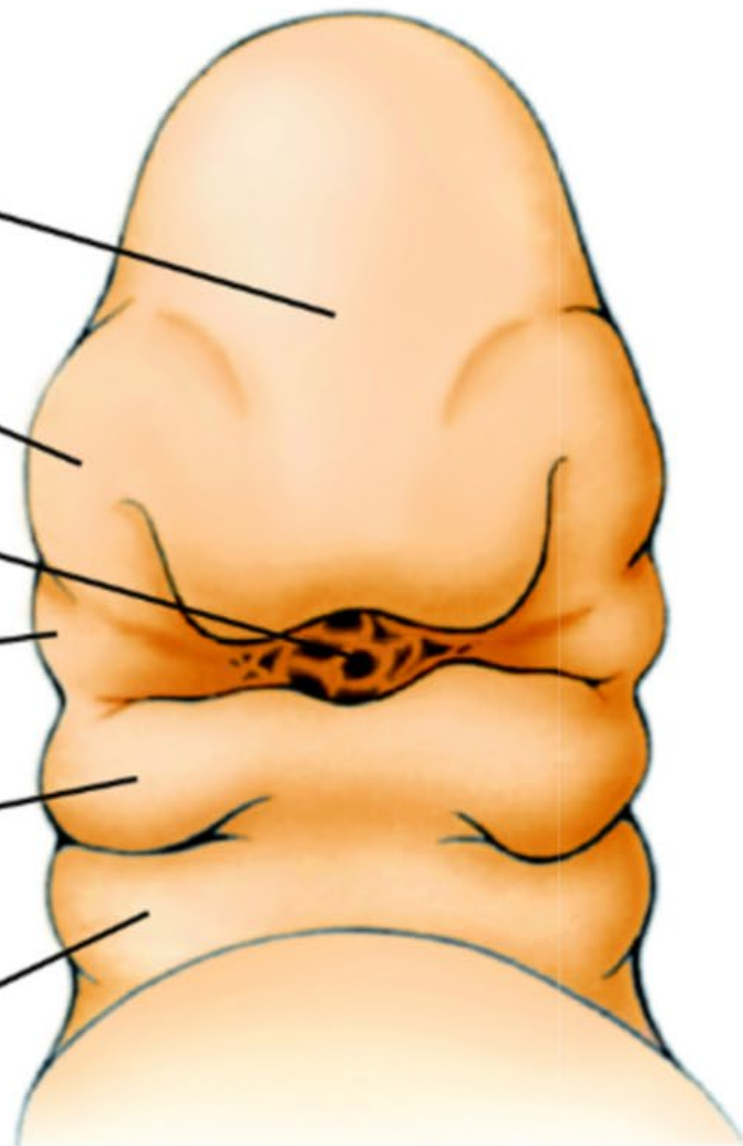
Nasal pit

Disintegrating  
oropharyngeal  
membrane

Maxillary  
prominence

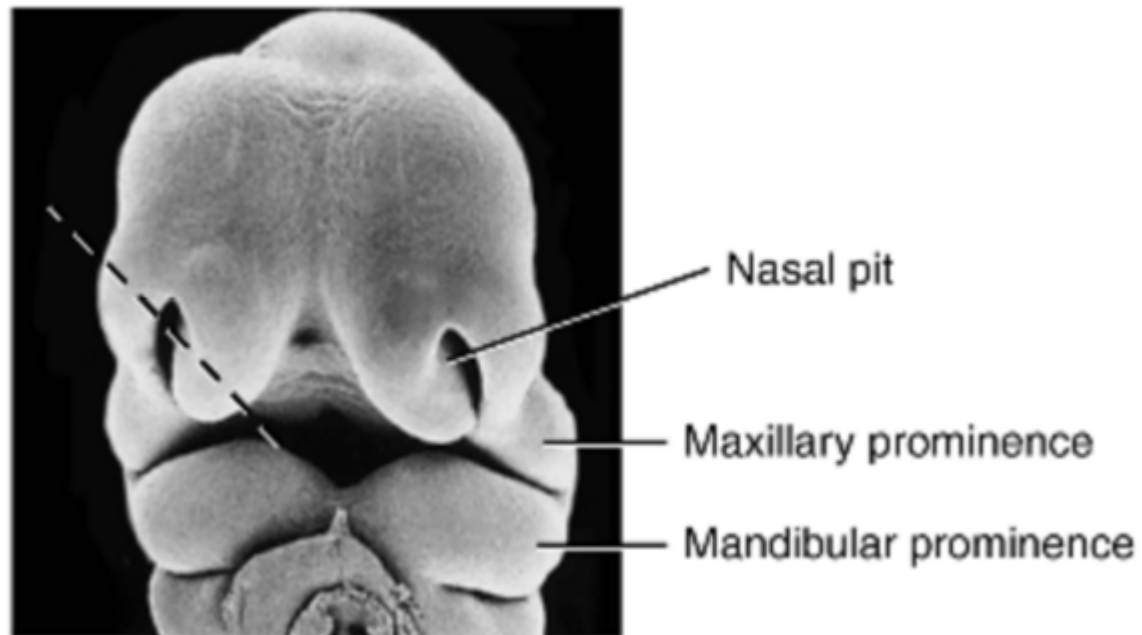
Mandibular  
prominence

2nd pharyngeal  
arch

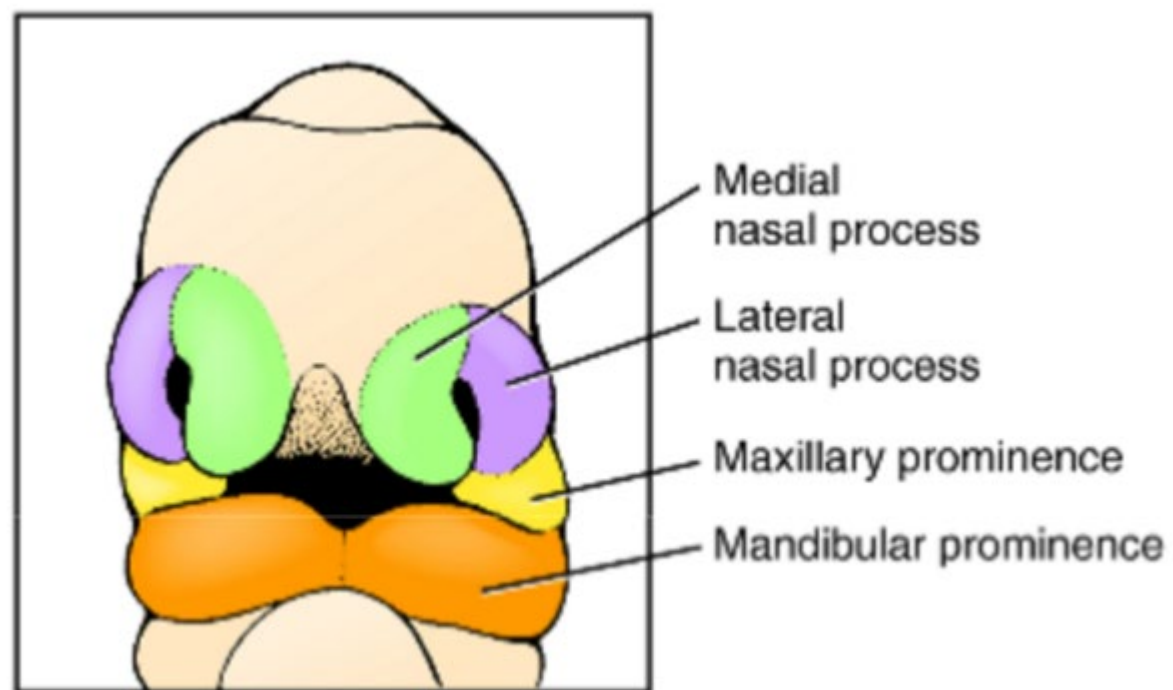


C

5th week

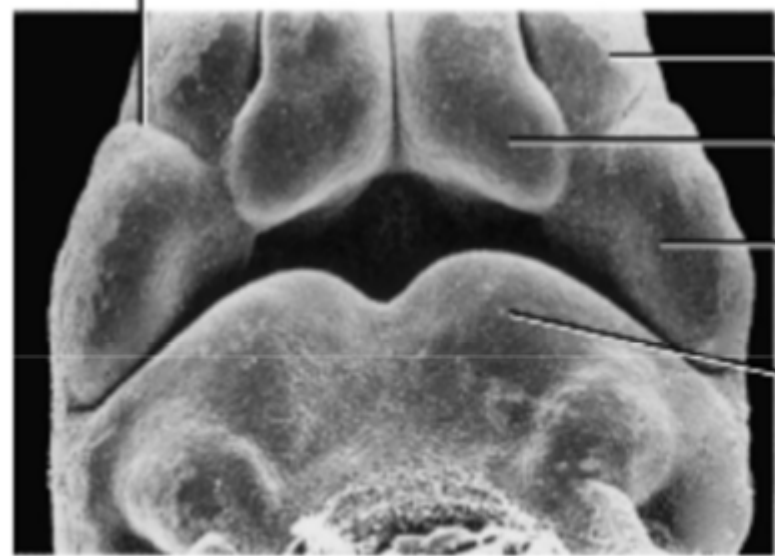


A Early 6th week



B Early 6th week

Nasolacrimal groove



Lateral nasal process

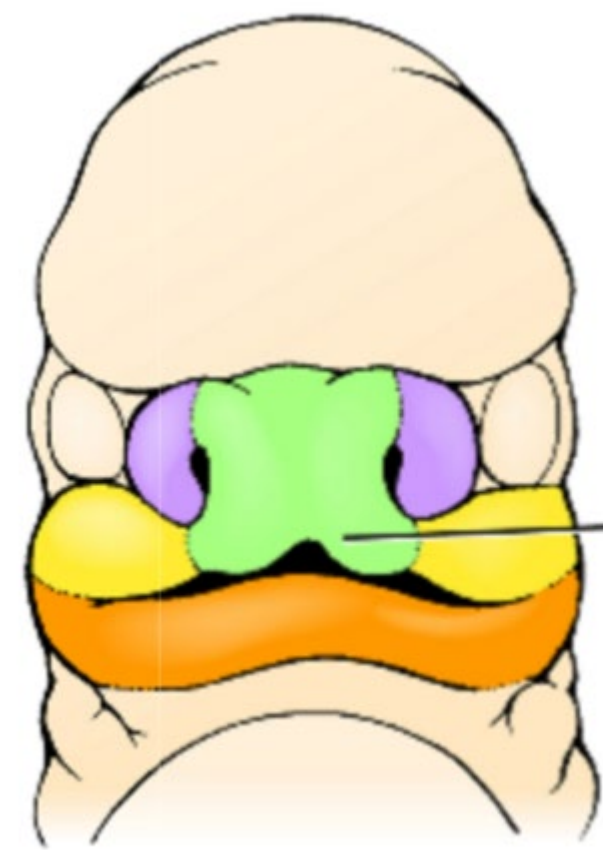
Medial nasal process

Maxillary prominence

Mandibular prominence

C

Early 7th week

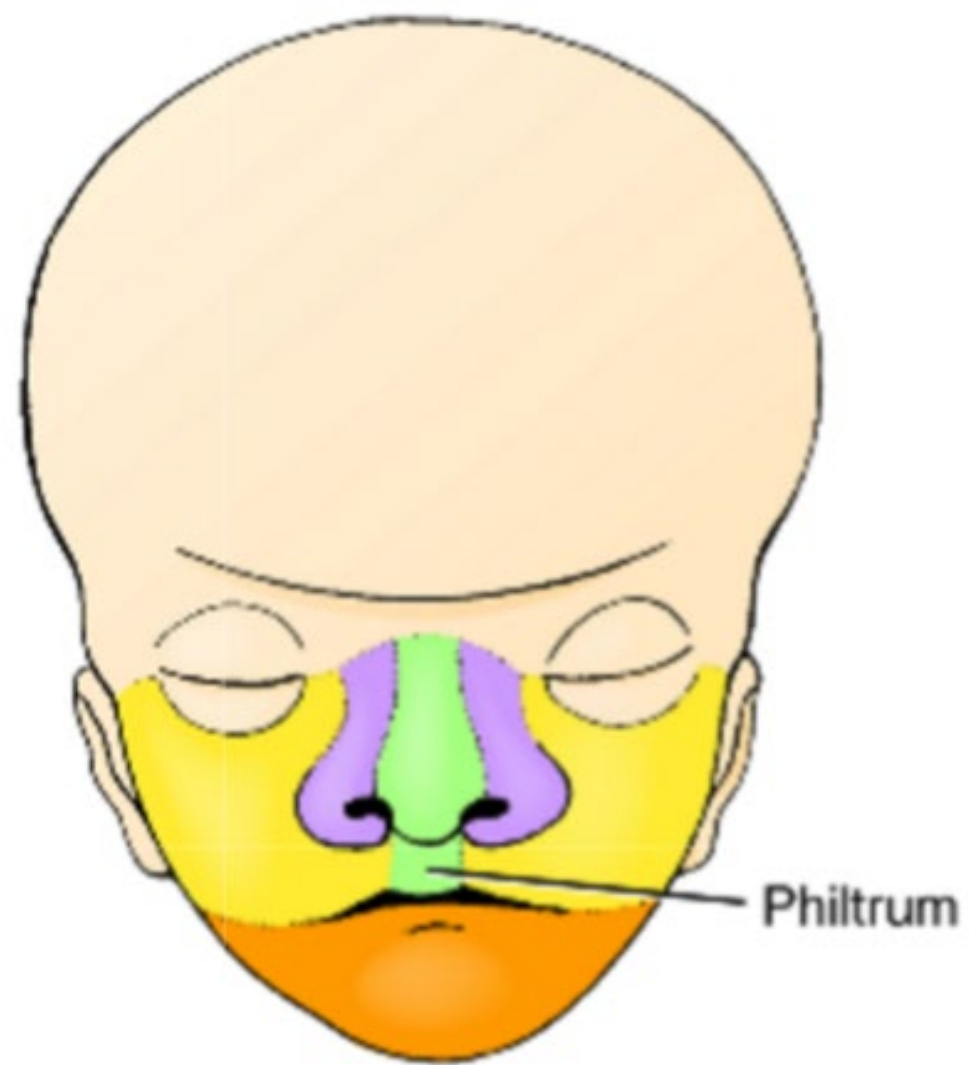


Intermaxillary process

D

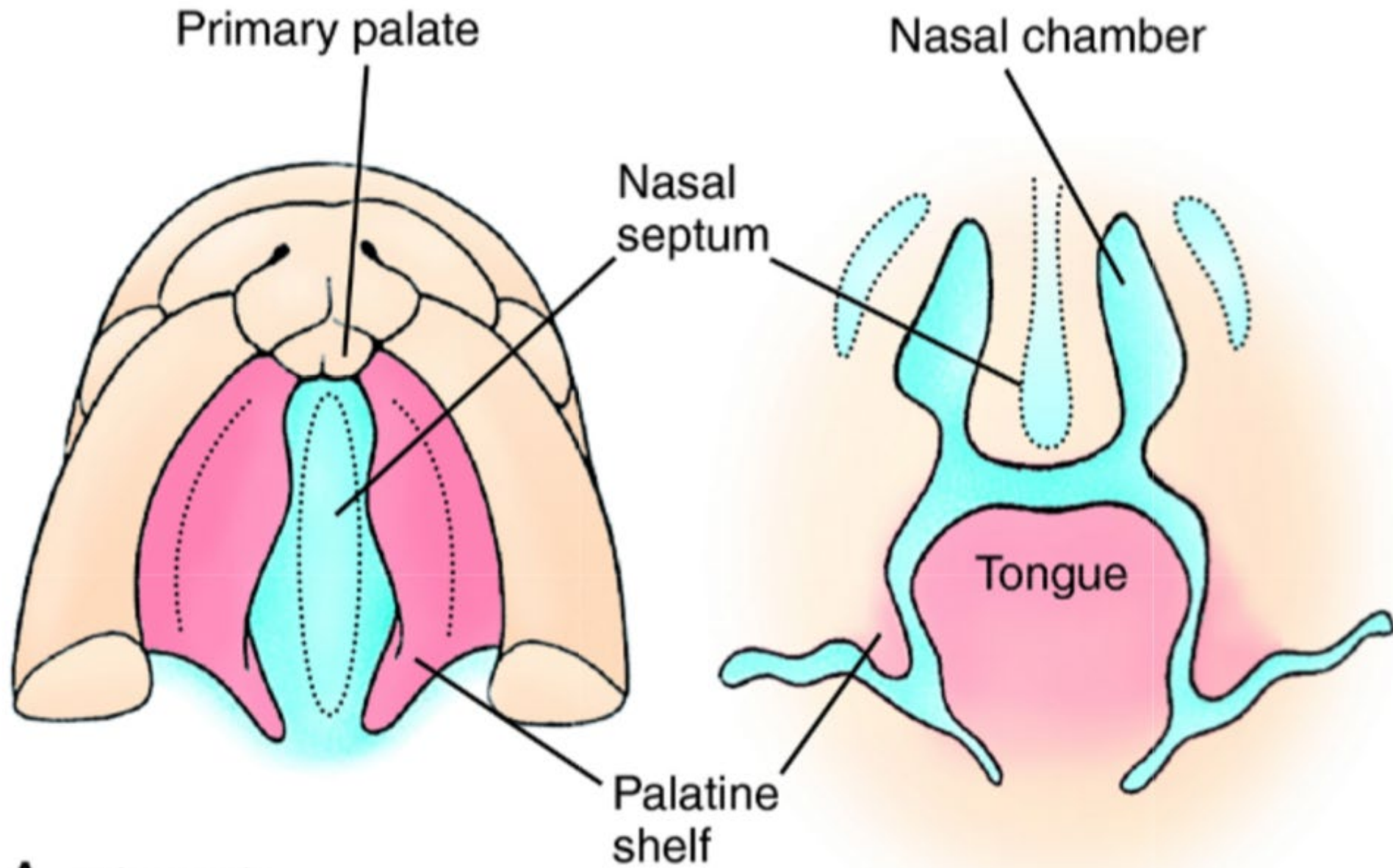
Late 7th week



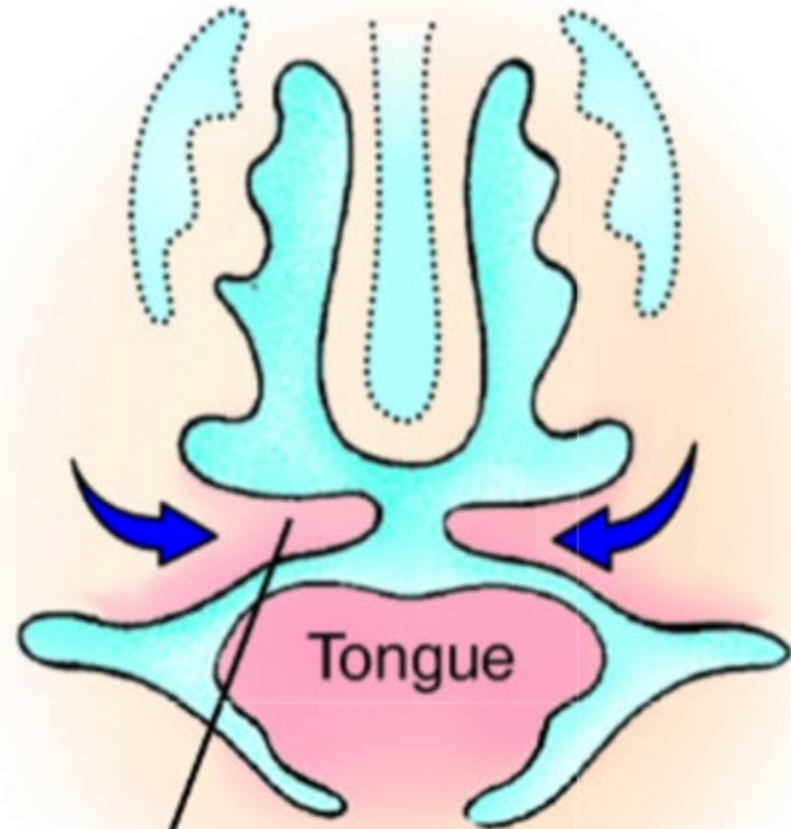
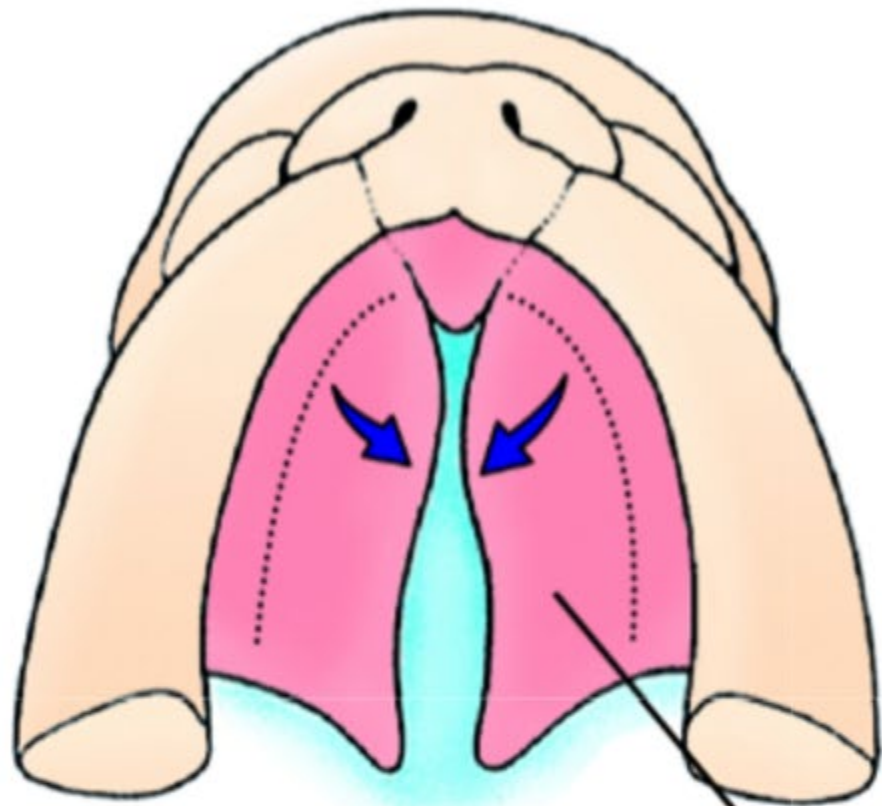


E

10th week



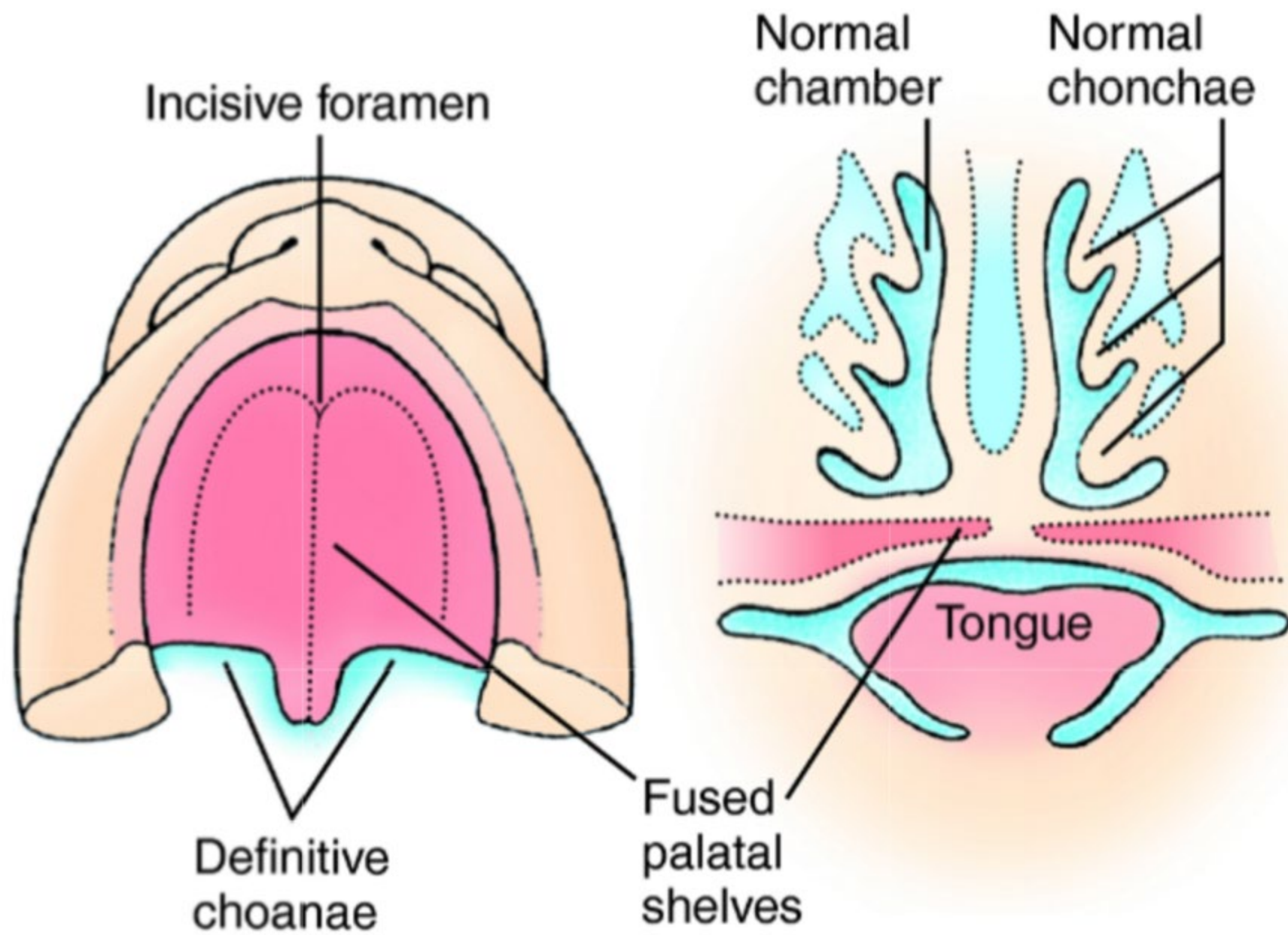
A 7th week



Palatine shelf

C Late 7th/8th week

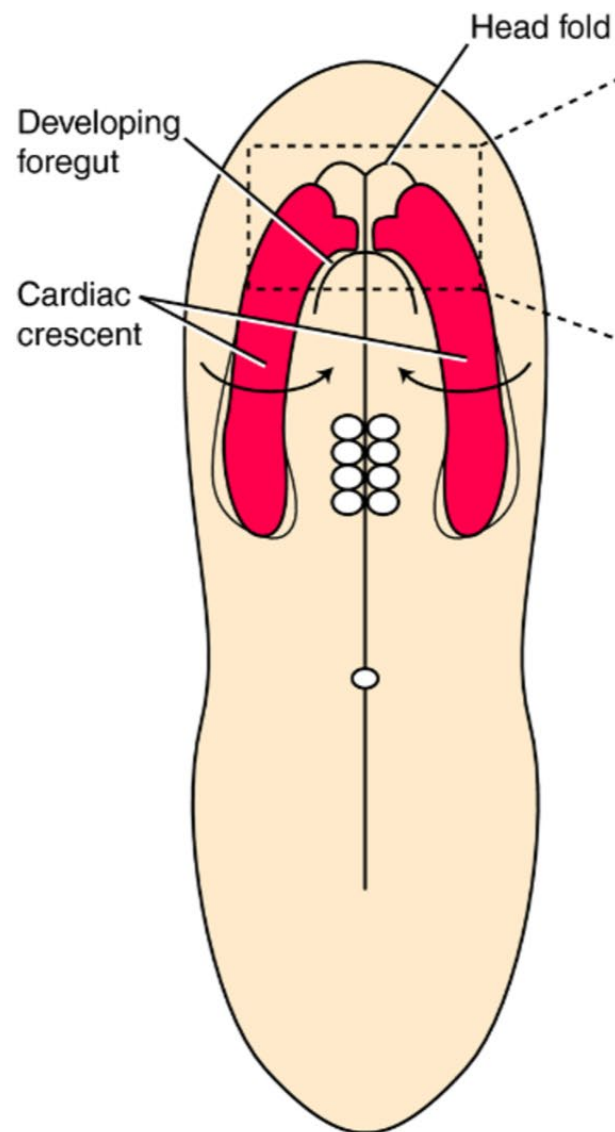




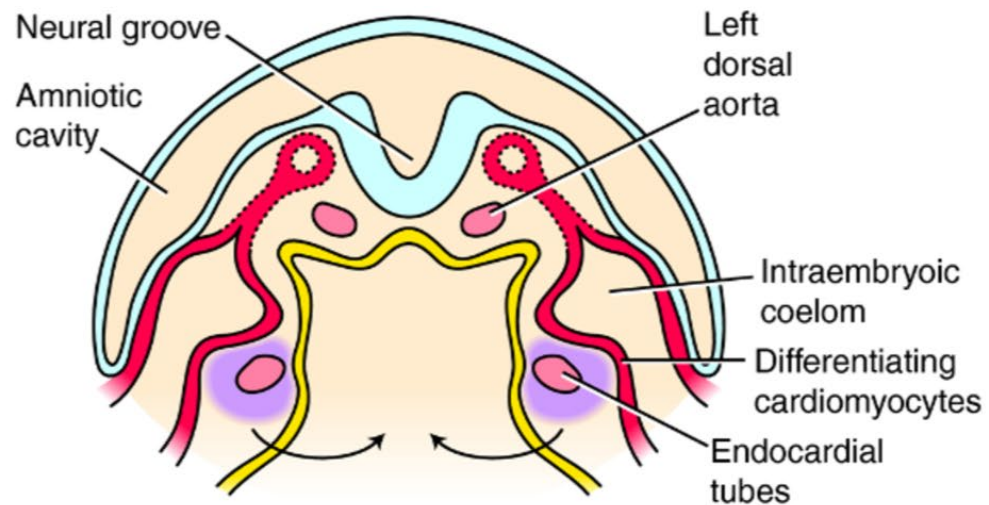
D 10th week

# Overview

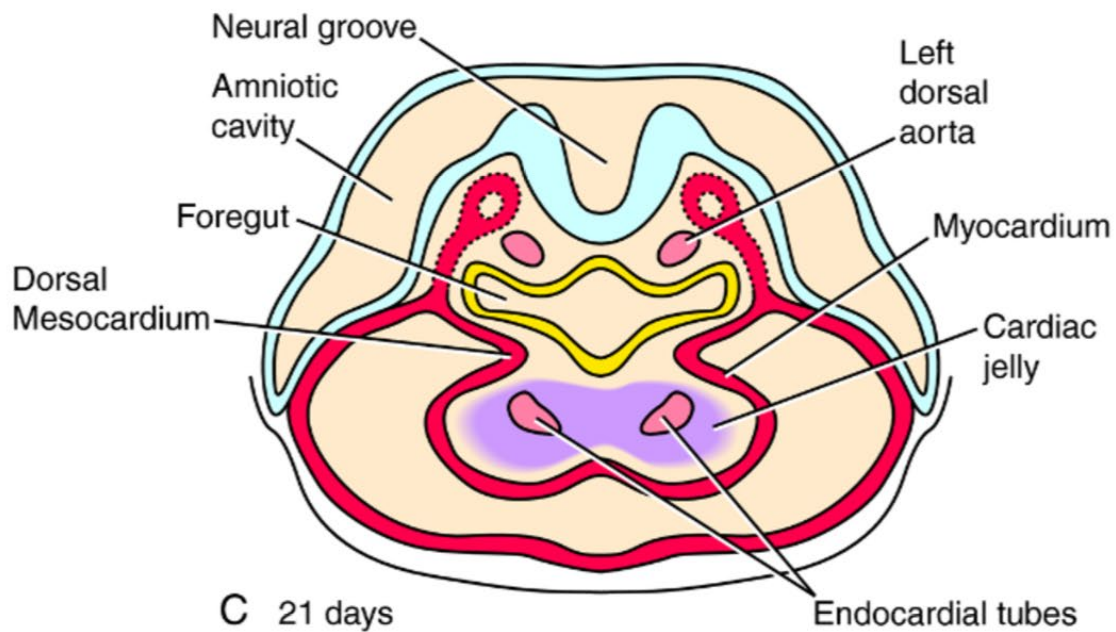
1. Early embryonic development
2. Central nervous system development
3. Endodermal tube formation and derivatives
4. Urogenital system development
5. Branchial cleft derivatives
6. **Cardiac and vasculature development**



A 20 days

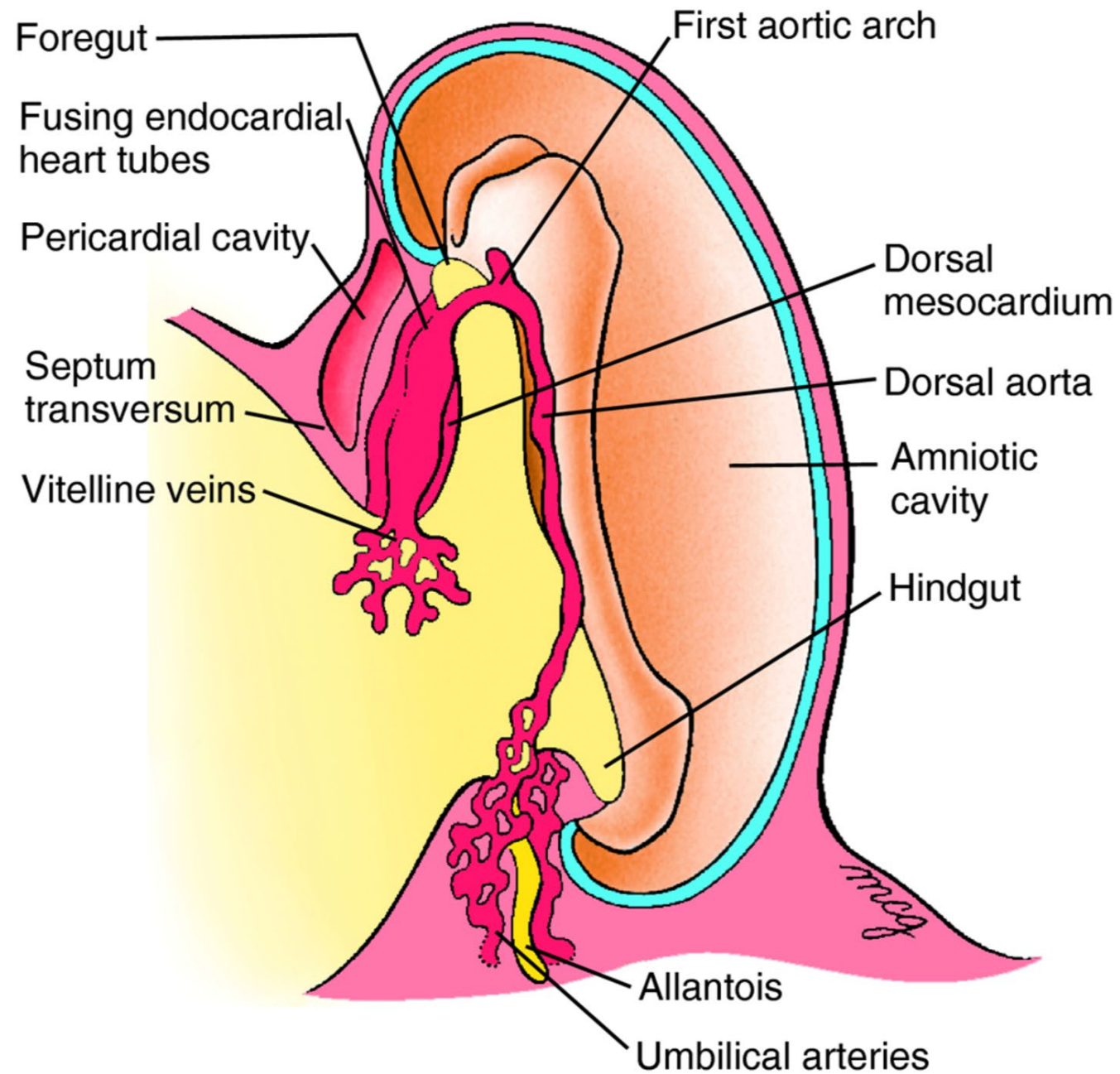


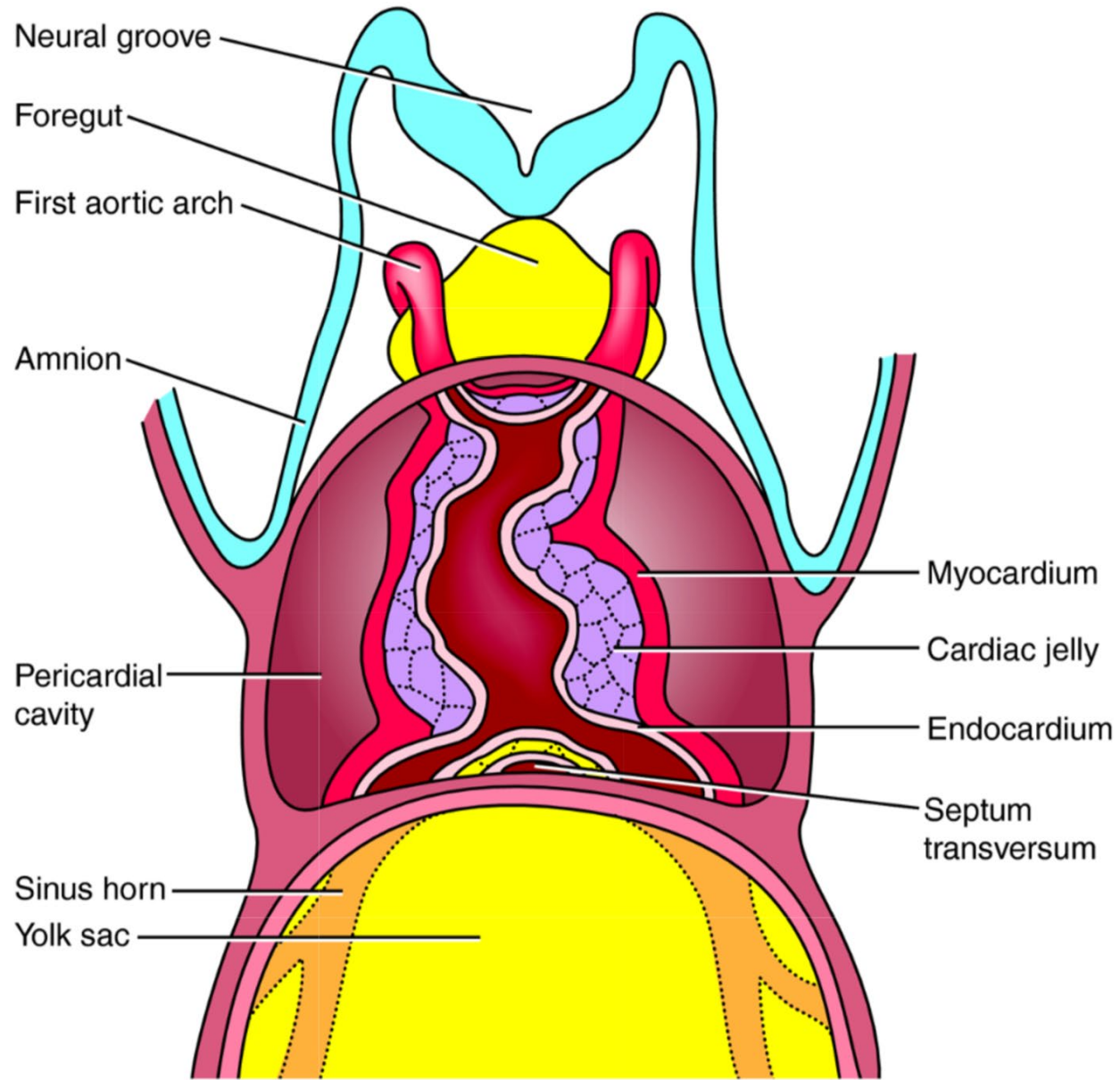
B 20 days



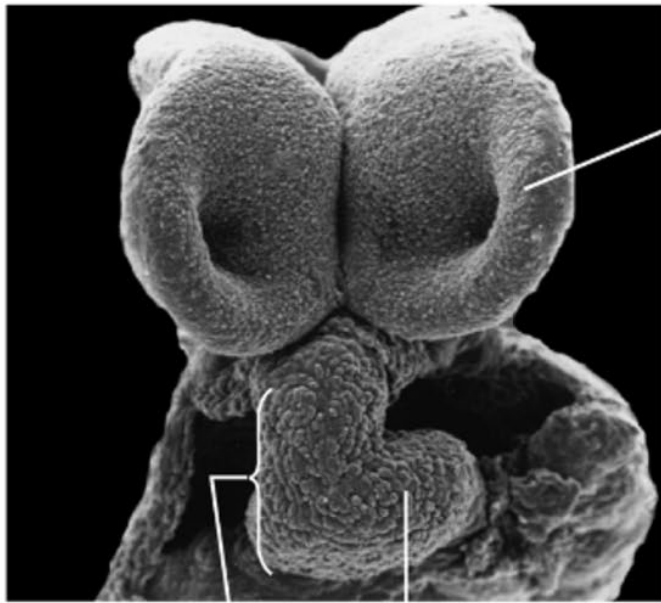
C 21 days







22 days



Neural fold

22 days

Bulbus cordis

Ventricle

Outflow tract

Future right ventricle (bulbus cordis)

Pericardial cavity

Sinus venosus

Yolk sac

Neural fold

First aortic arches

Foregut

Ventricle (future left ventricle)

Atrioventricular sulcus

Primitive atrium

Future right ventricle

24 days

Neural groove

Outflow tract

Future left ventricle

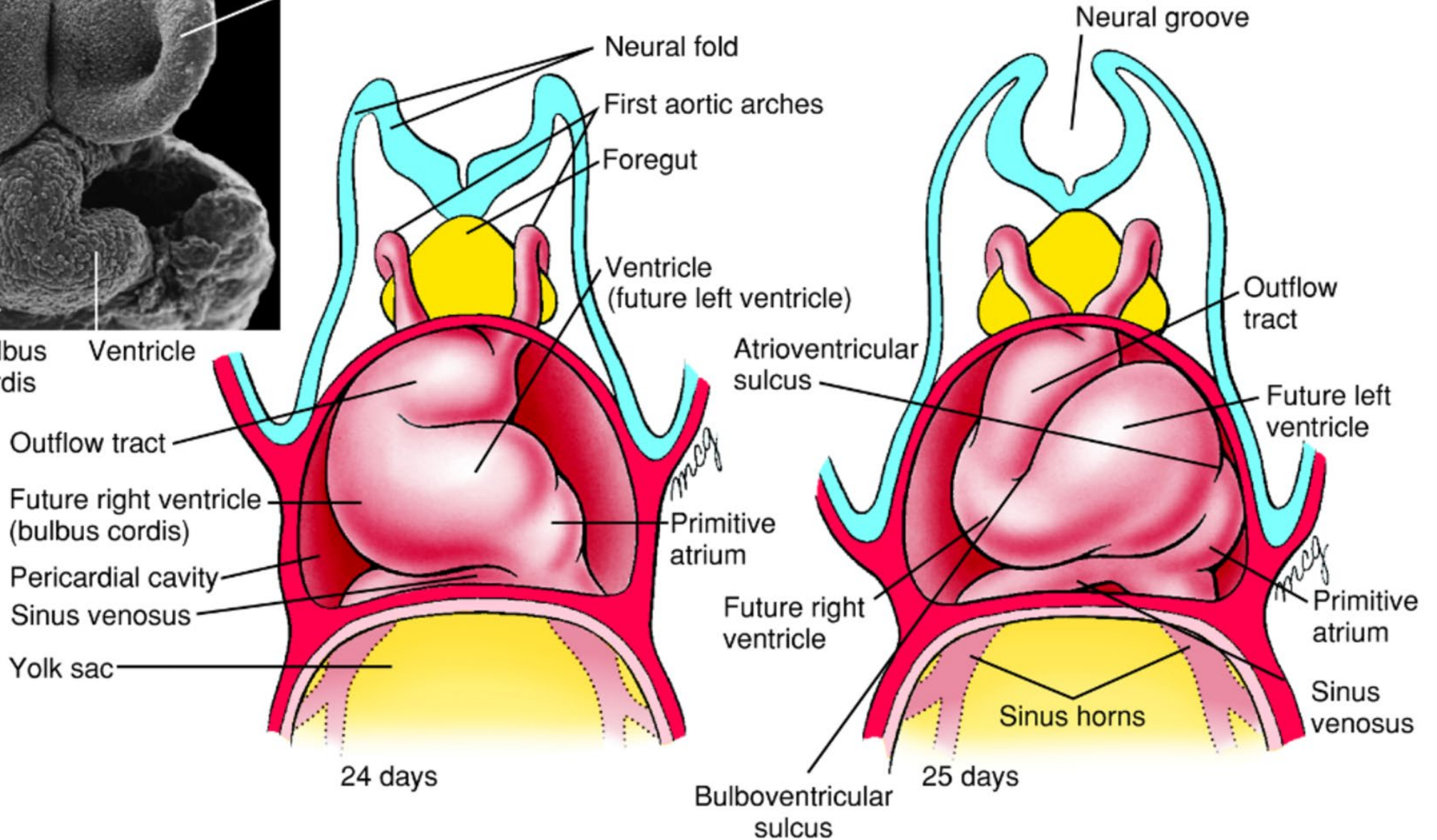
Primitive atrium

Sinus venosus

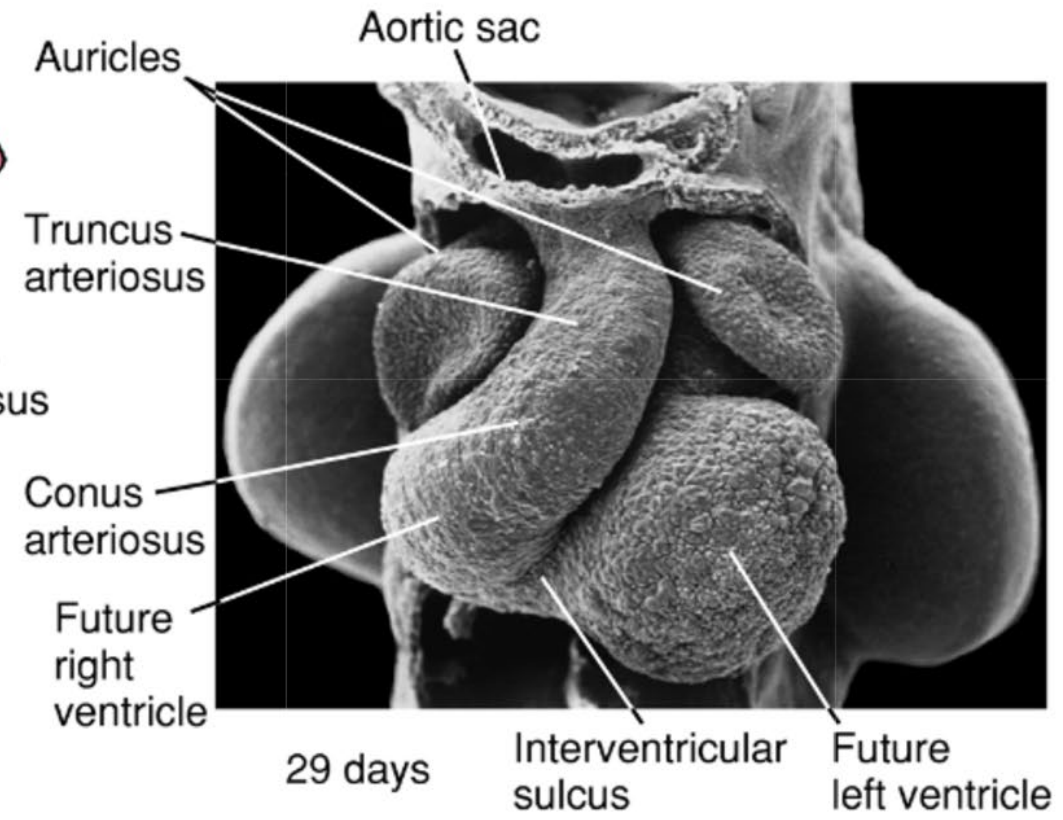
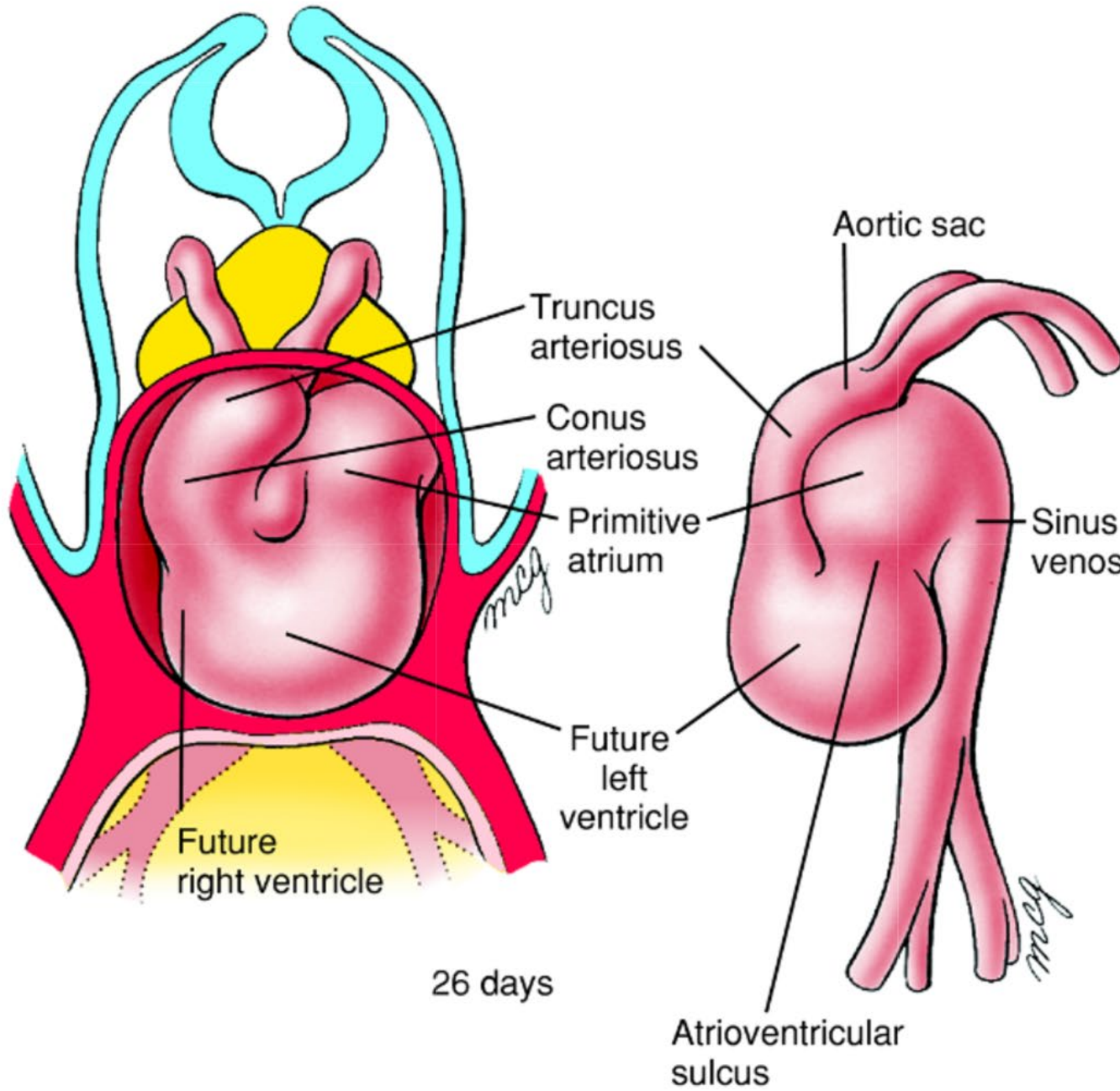
Sinus horns

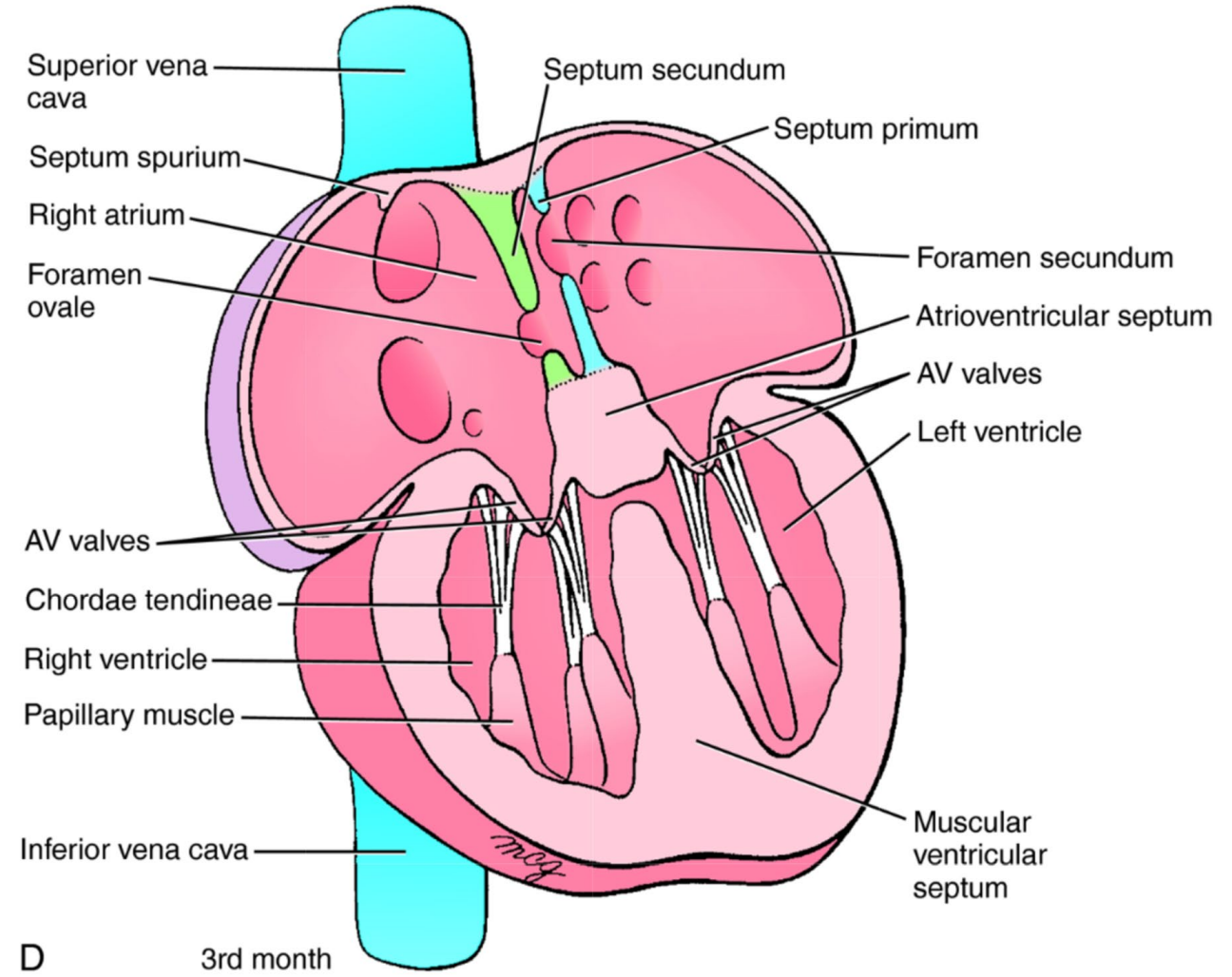
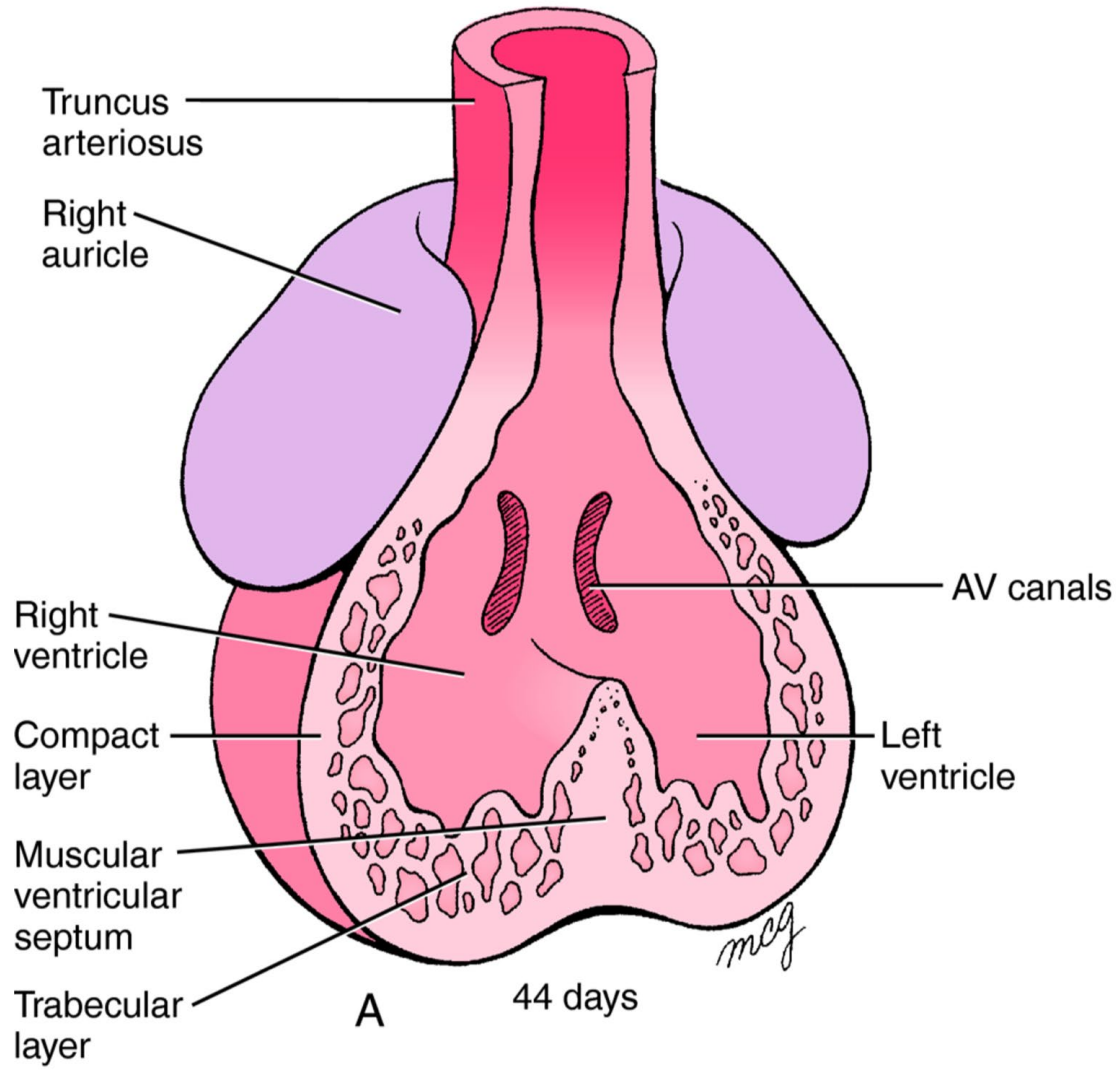
25 days

Bulboventricular sulcus

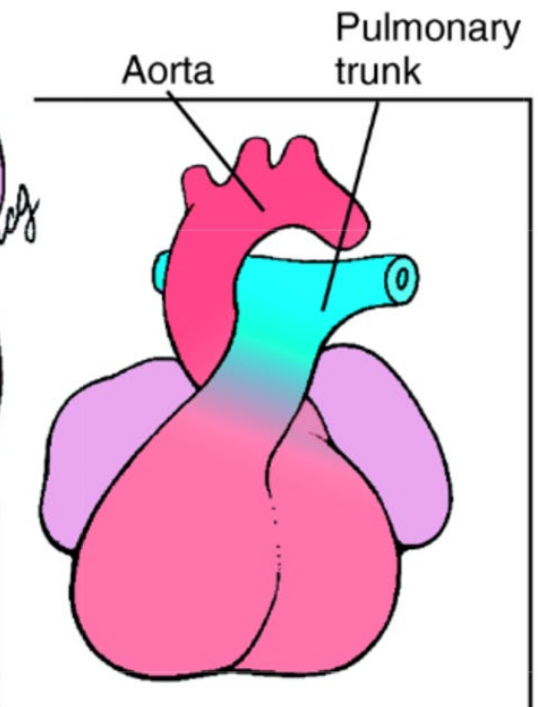
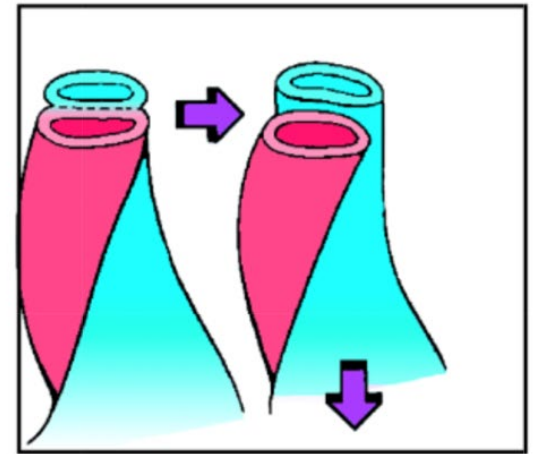
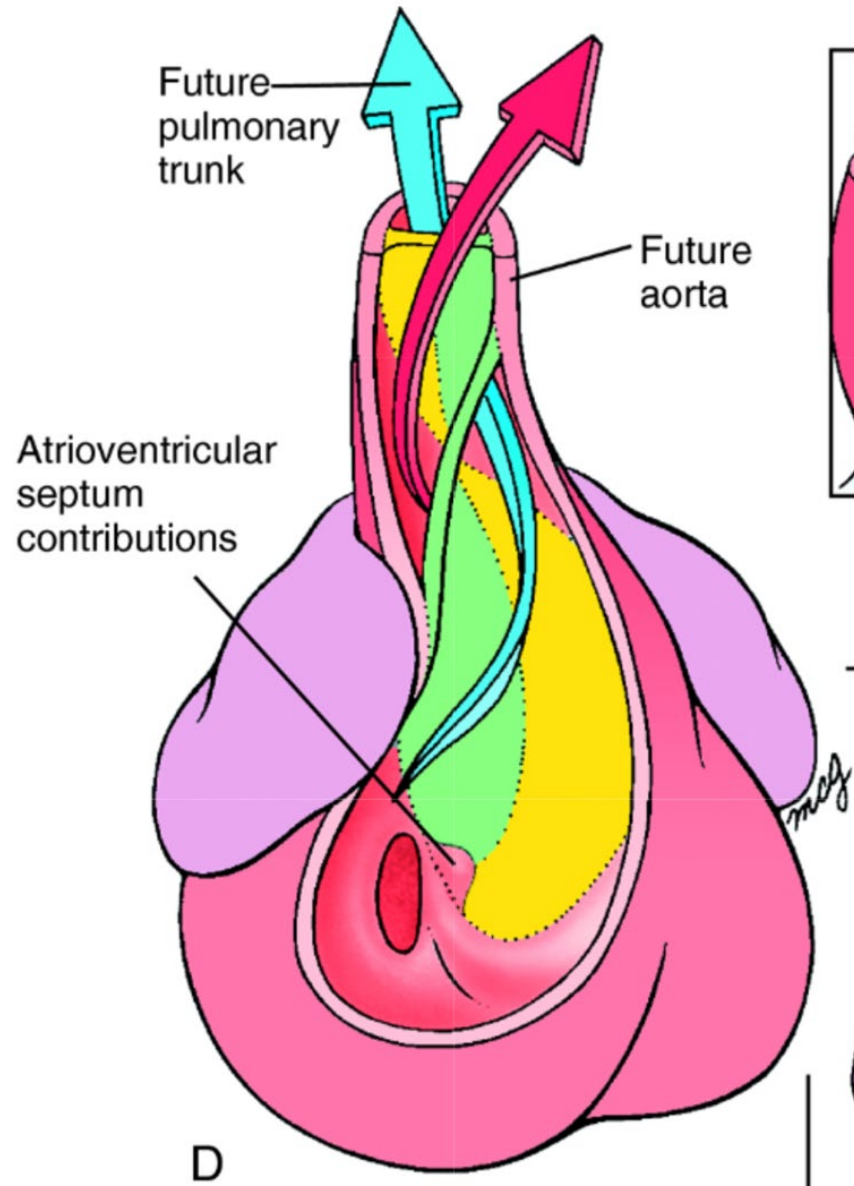
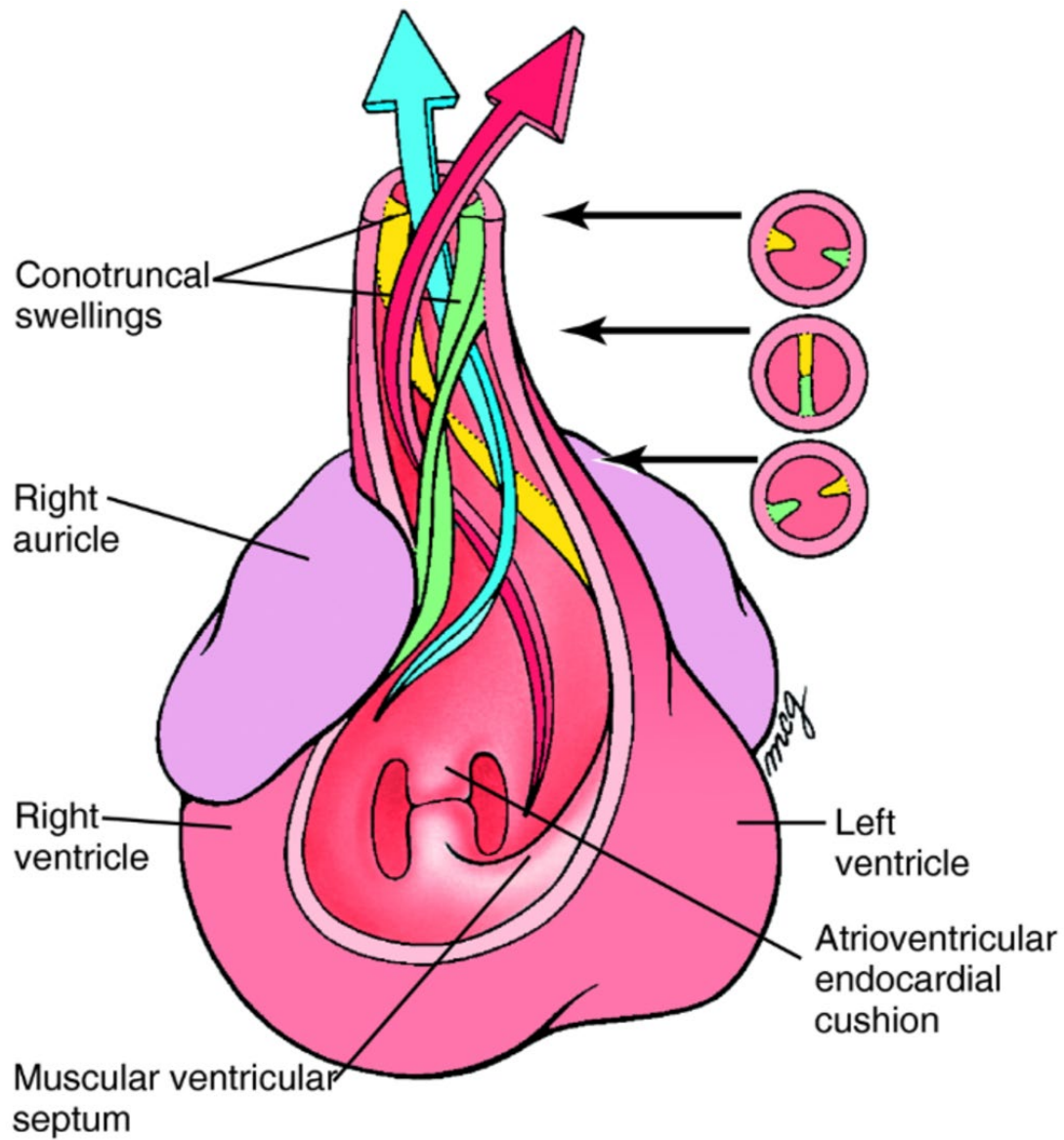




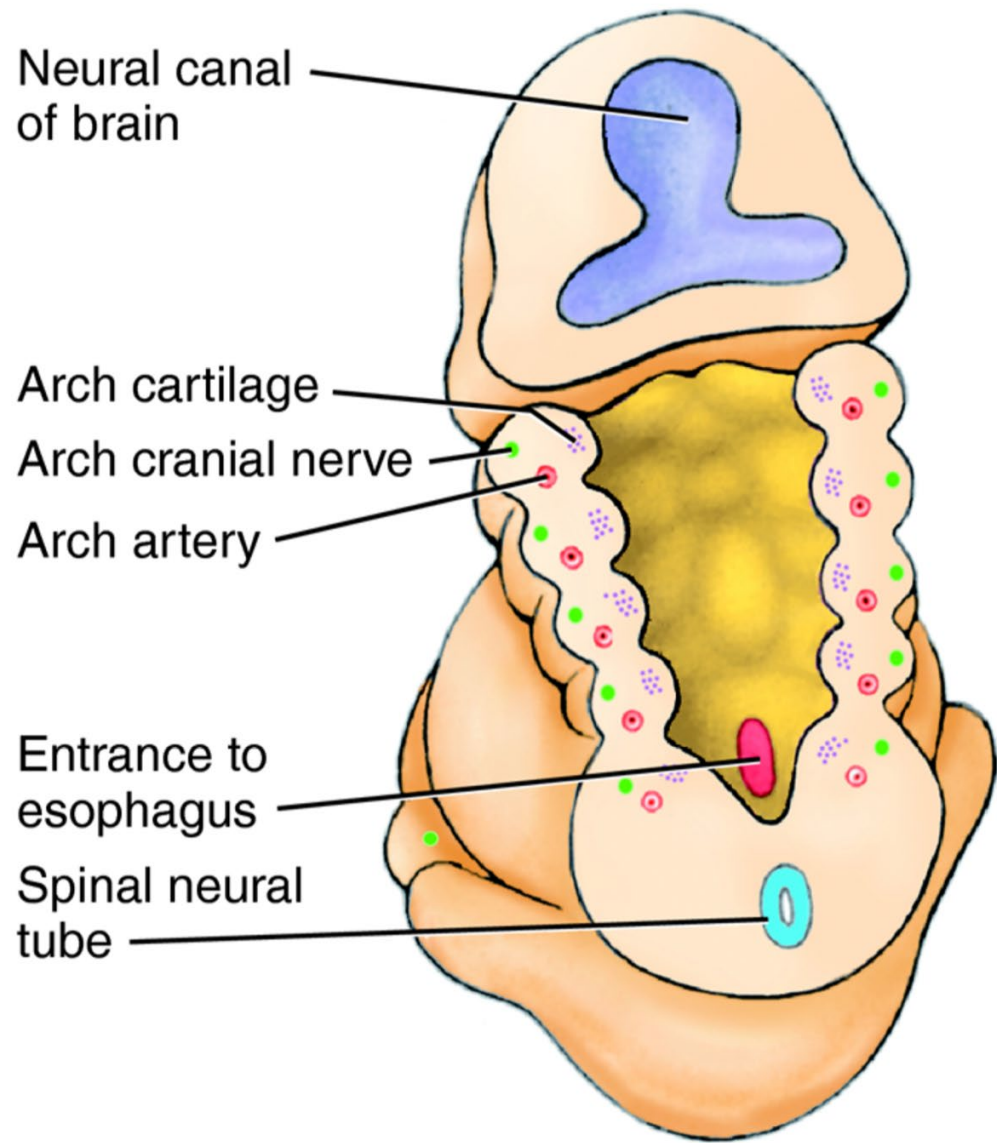






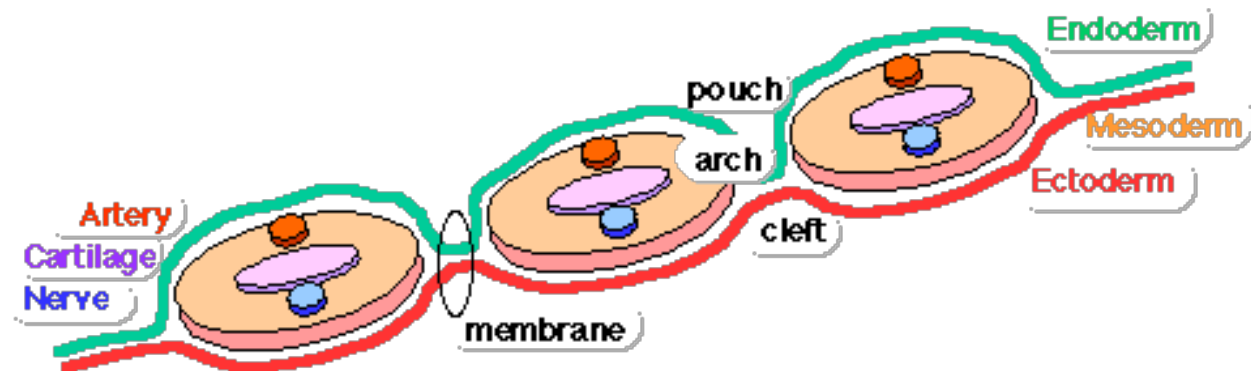


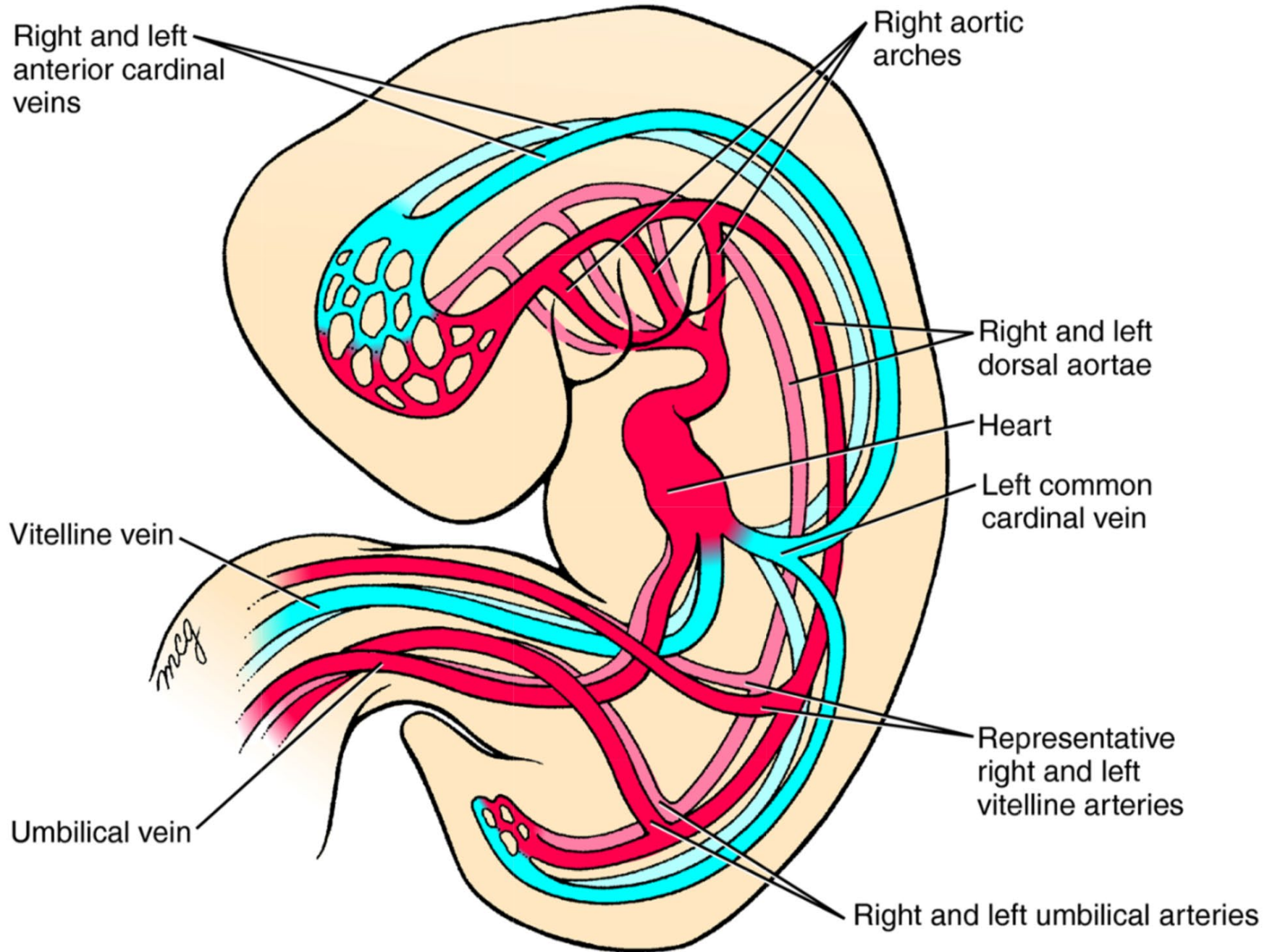


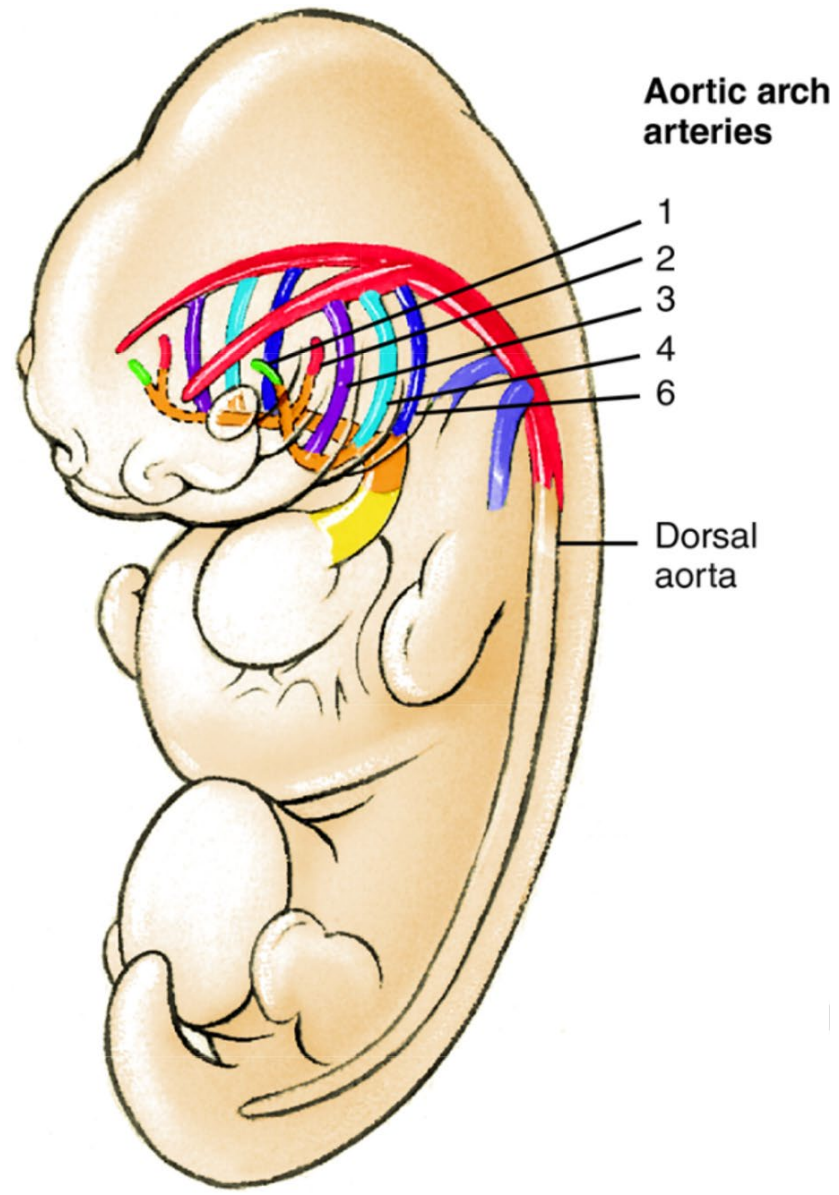


Dorsal side

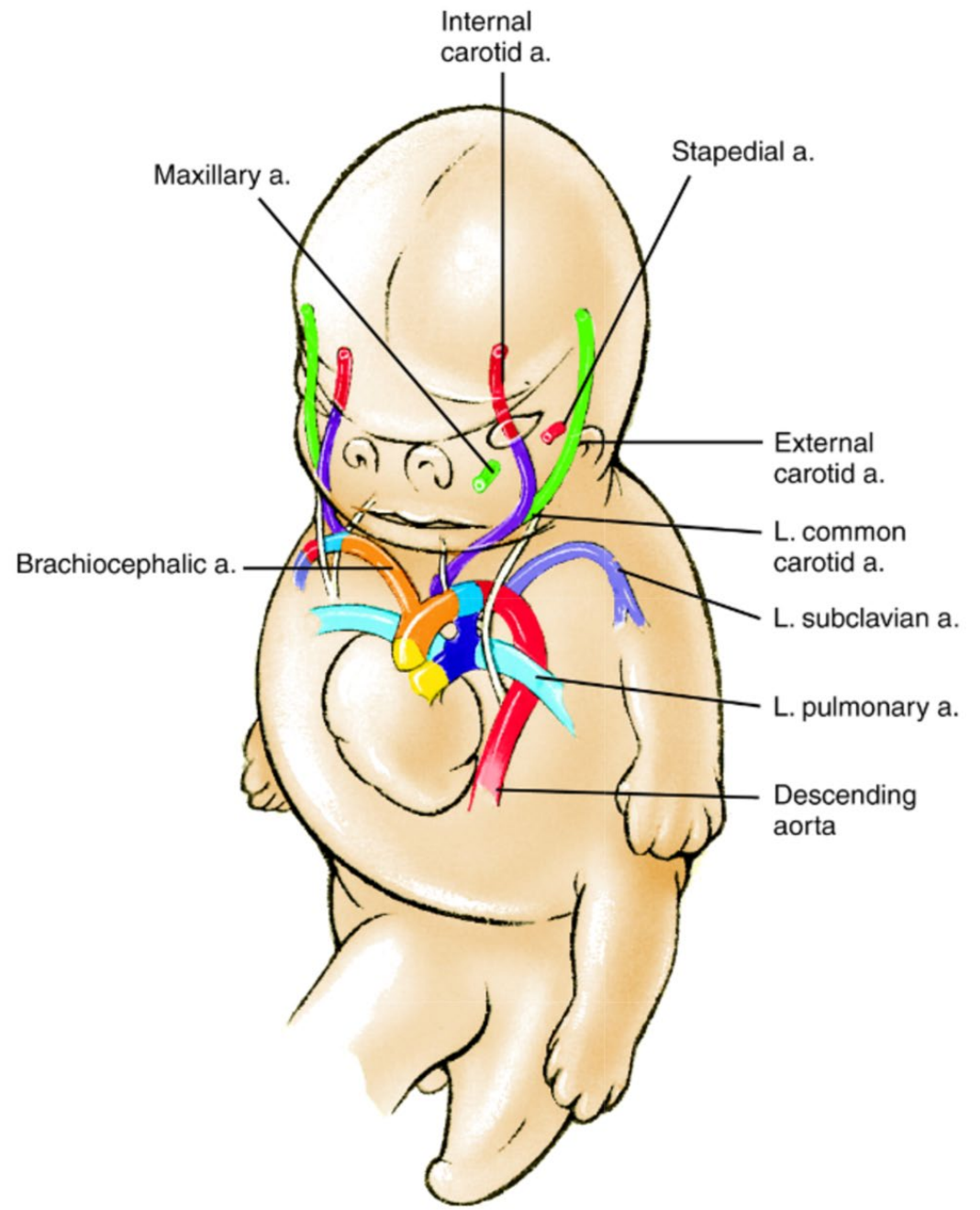
D 29 days







5th week



8 weeks



