

2019

# Operative Management of Catastrophic Bleeding

---

Dr David Evans  
Vascular Surgeon  
St Vincent's Sydney

---



---

# Aims

---

- ❖ Feel more comfortable with bleeding
- ❖ cABCD
- ❖ Hard and Soft Signs of Bleeding
- ❖ Pre Operative Management
- ❖ Intra Operative Management
- ❖ Post Operative Management
- ❖ Cases & Special Situations



---

# cABCD

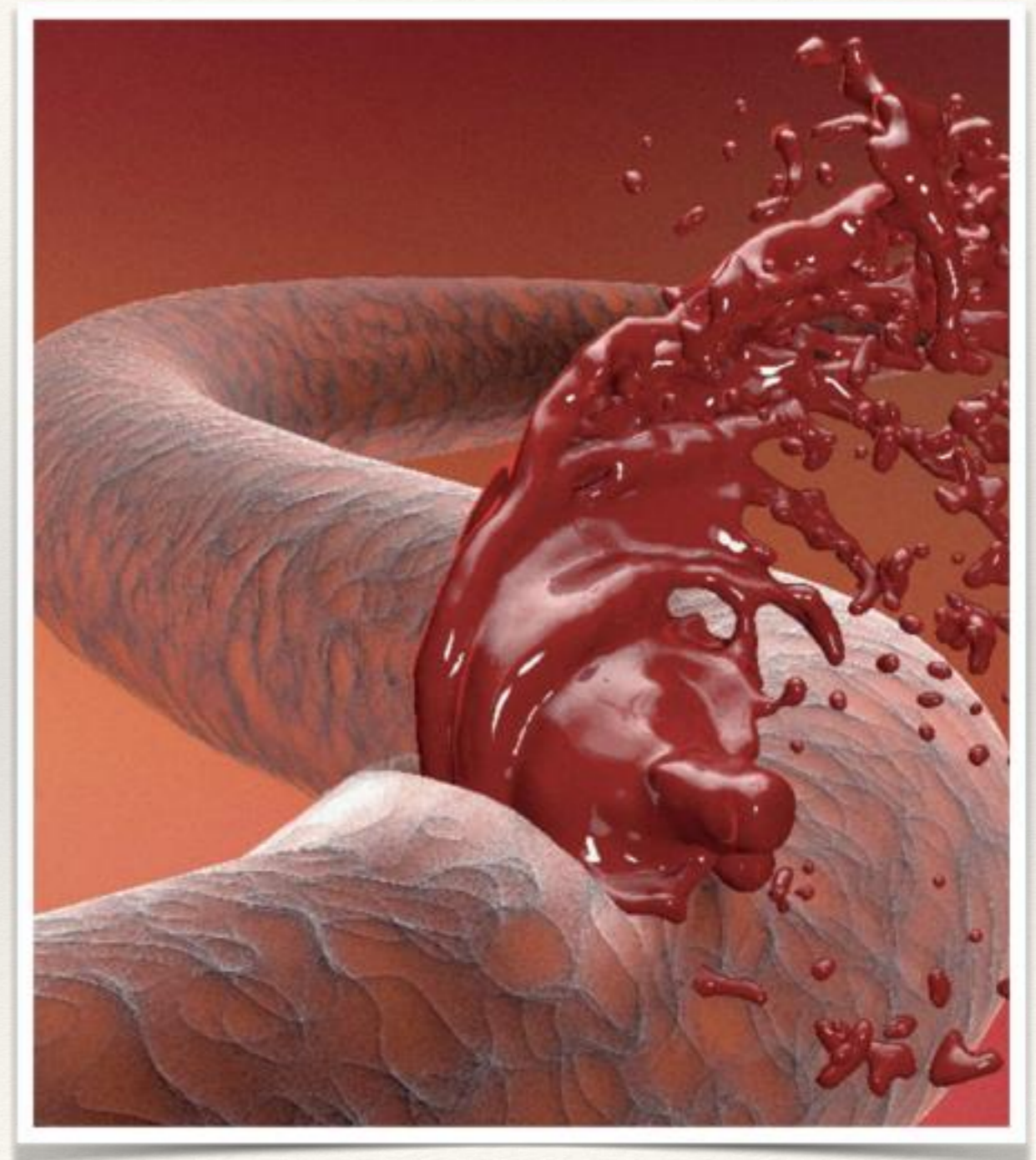
---

- ❖ “C”
- ❖ Catastrophic Bleeding
- ❖ Priority
- ❖ Reinforces the issue that the patient needs theatre
- ❖ Code Crimson



# Catastrophic Bleeding

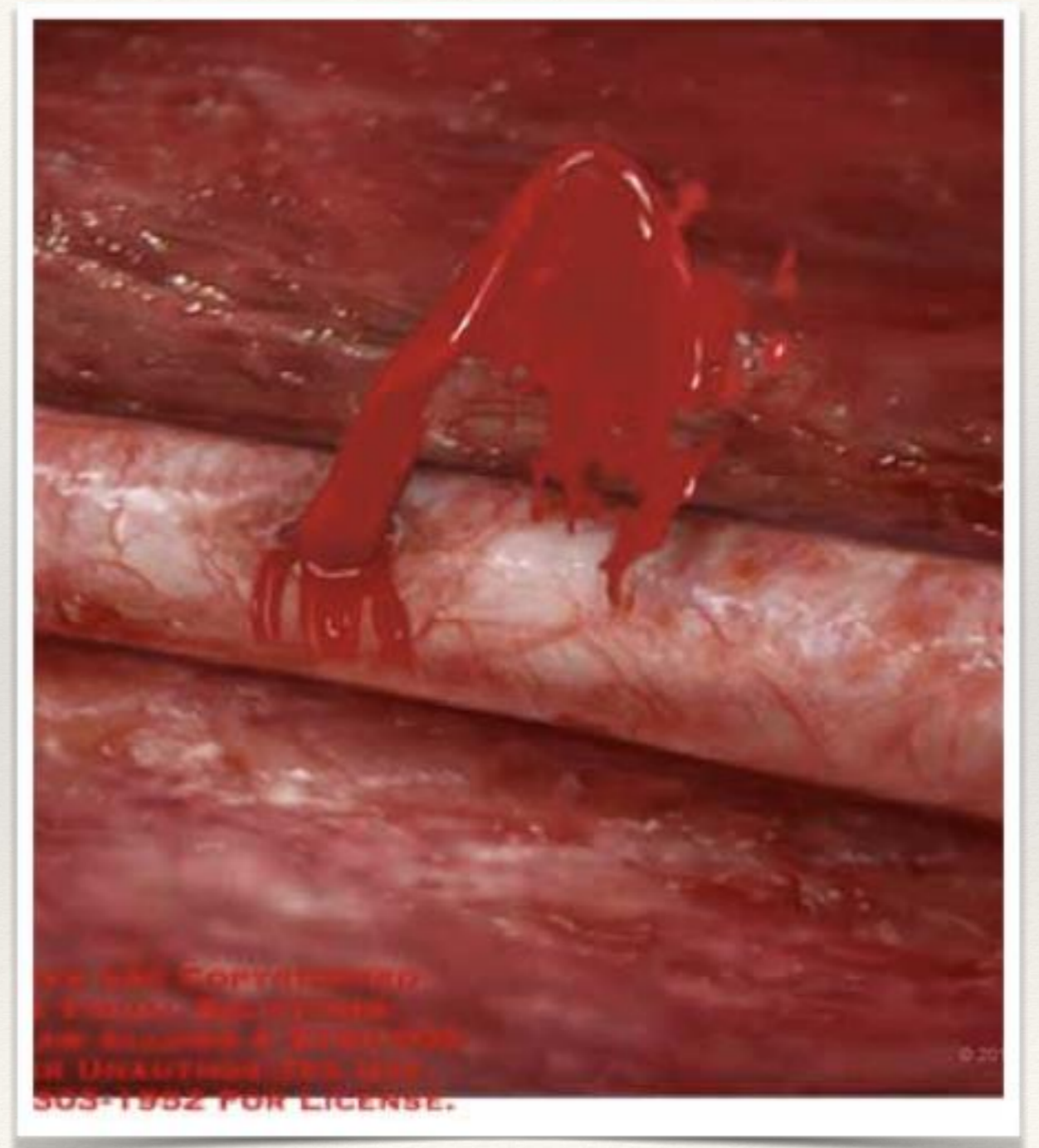- ❖ No universally accepted definition
- ❖ “know it when you see it”
- ❖ Life threatening and likely result in massive transfusion
- ❖ Massive Transfusion
  - ❖ 4units in 4 hrs and unstable
  - ❖ blood volume in 24hrs
  - ❖ severe injury
  - ❖ 150mls/min





# Hard Signs of Bleeding

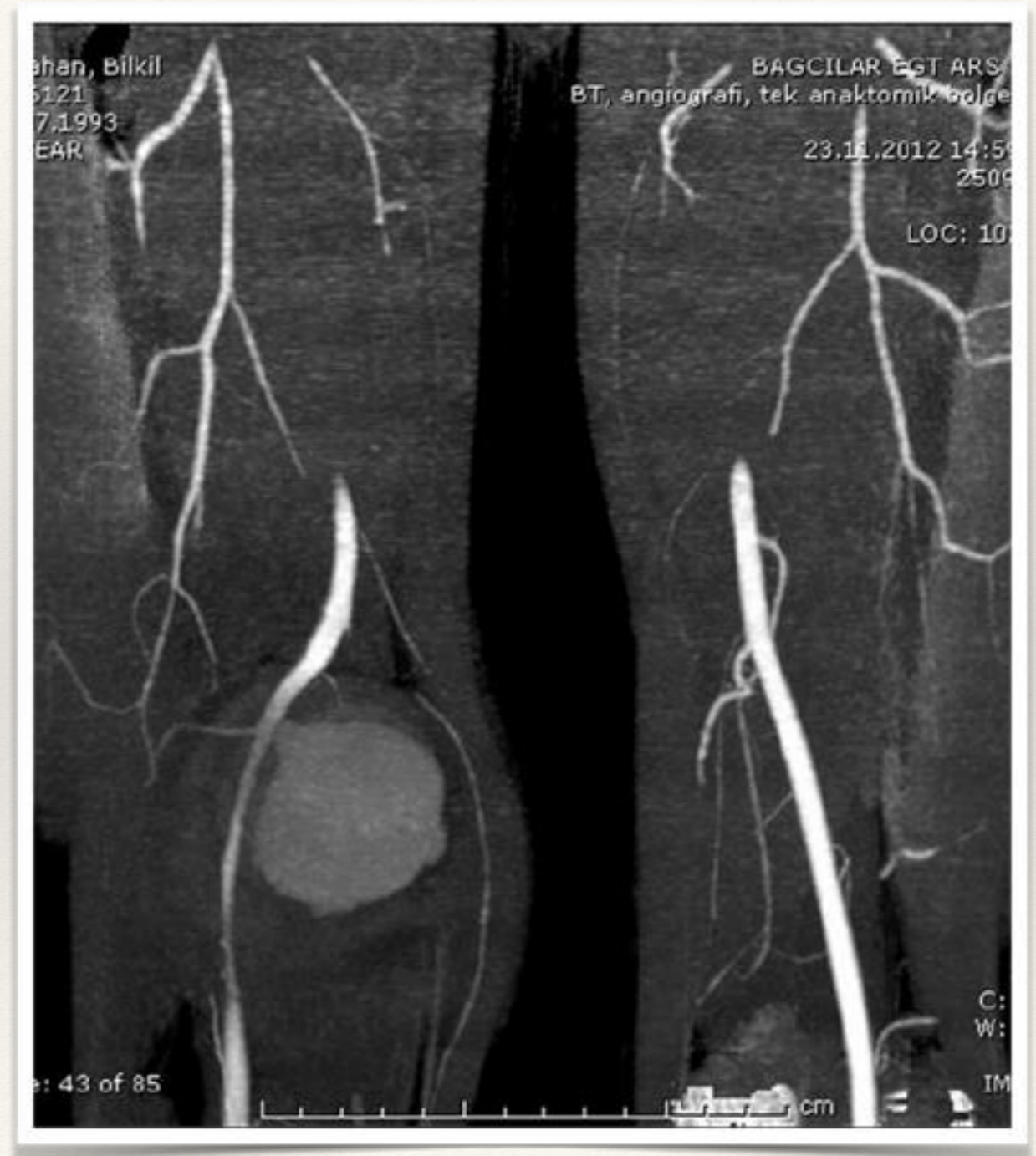- ❖ Signs of Ischemia
- ❖ Active Haemorrhage
- ❖ Expanding or Pulsatile haematoma
- ❖ Bruit or Thrill over wound





# Soft Signs of Bleeding

- ❖ Reduced pulse
- ❖ Injury in proximity
- ❖ Neurologic deficits
- ❖ Stable Haematoma
- ❖ History of Haemorrhage
  
- ❖ Investigate - CTA, USS, serial examinations



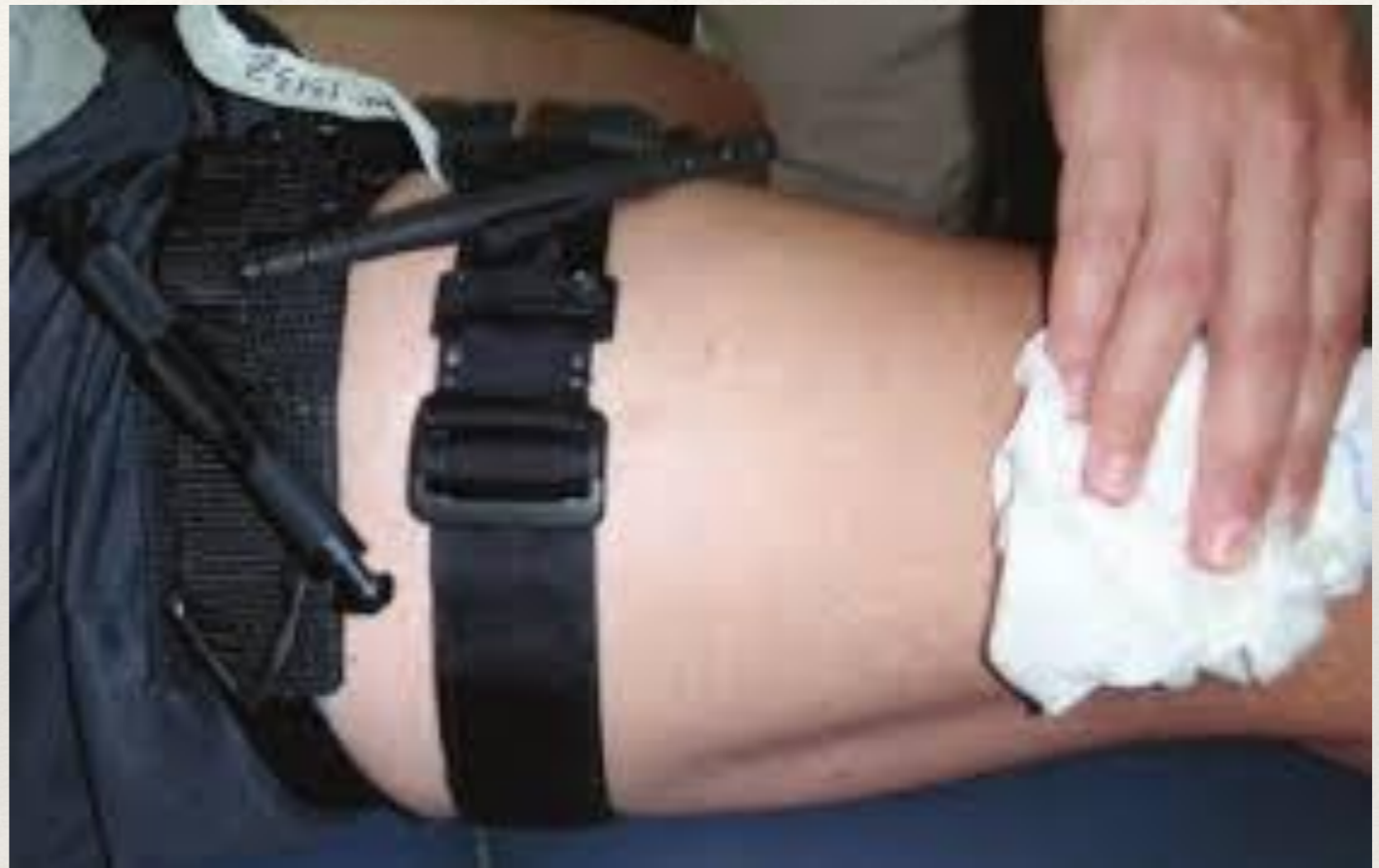

---

# Pre Operative Management

---

- ❖ Proximal Control
  - ❖ Pressure
  - ❖ Tourniquet
- ❖ Phone a friend
- ❖ Code Crimson
- ❖ Massive Transfusion
- ❖ Hypotensive Resuscitation
- ❖ TXA



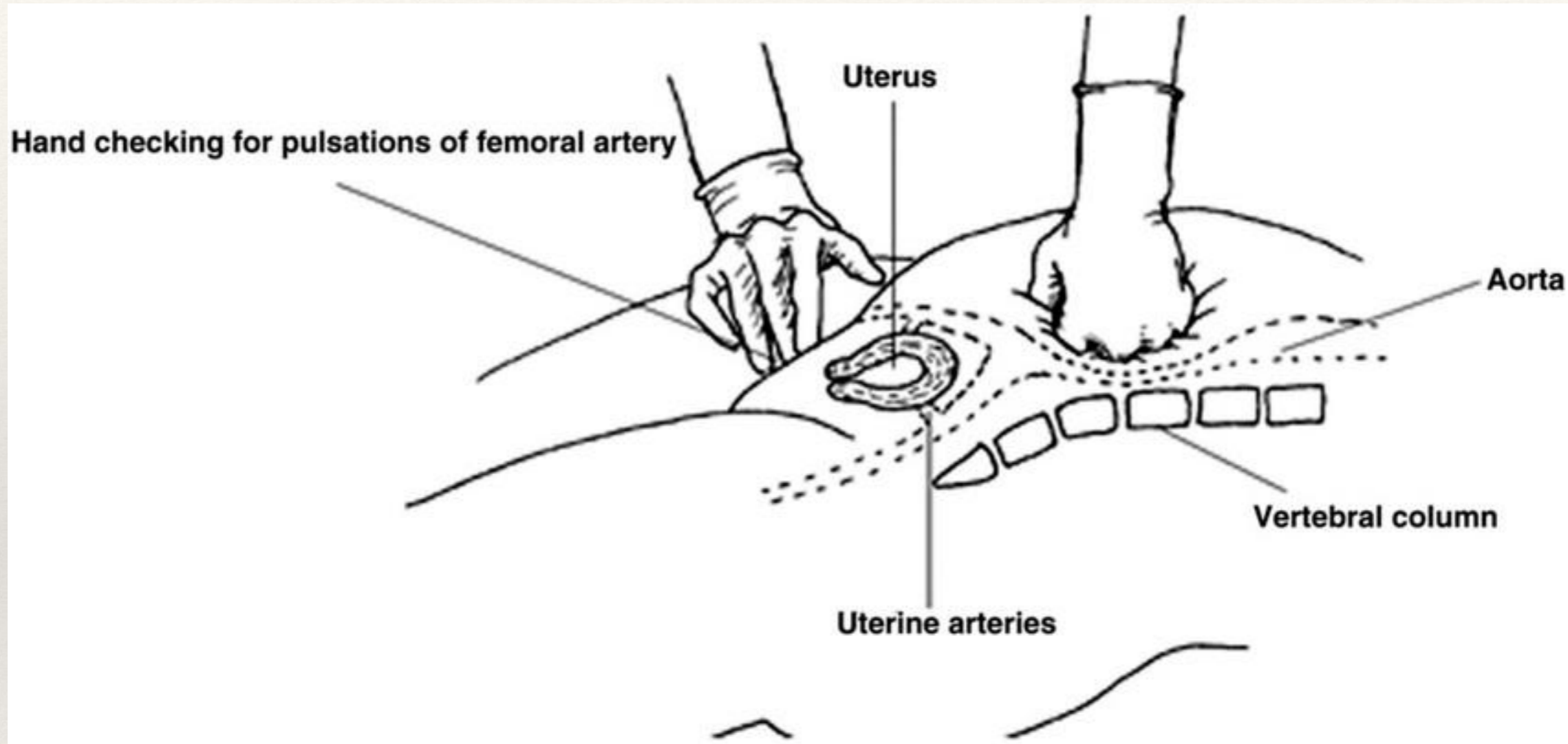
## Criteria for Activation

Persistent haemodynamic instability despite standard trauma care (see below), assessed as being secondary to ongoing haemorrhage in blunt or penetrating trauma, which is unresponsive to intravenous fluids and or blood transfusion.

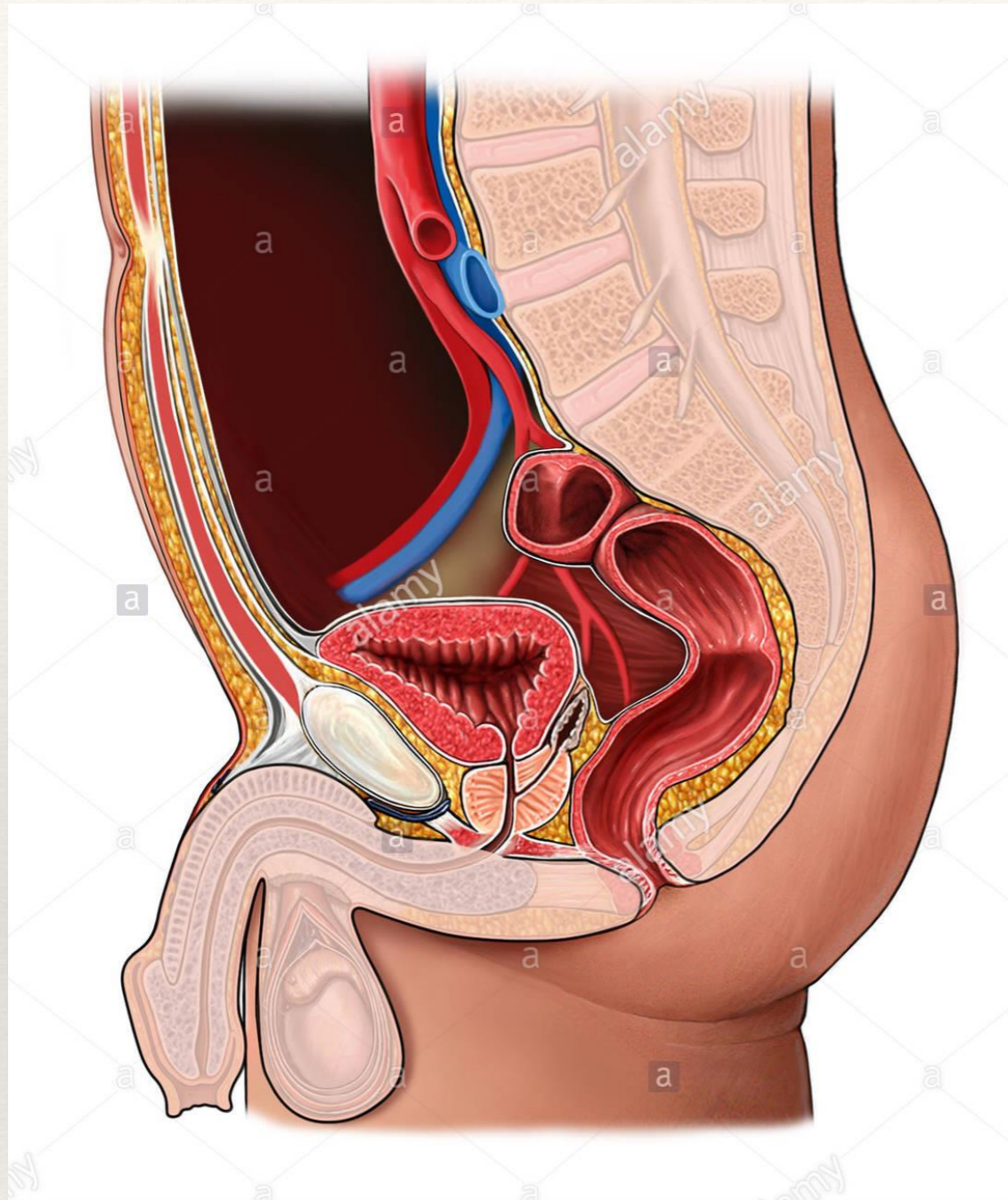
Clinical examples of potential injuries meeting the above criteria:

Blunt trauma	Penetrating trauma
<ul style="list-style-type: none"><li>• Abdominal trauma with grossly positive E-FAST</li><li>• Uncontrolled maxillo-facial haemorrhage</li><li>• Gross pelvic disruption</li><li>• Massive haemothorax</li><li>• Traumatic amputation</li></ul>	<ul style="list-style-type: none"><li>• Penetrating trauma to chest/abdomen</li><li>• Junctional penetrating trauma</li><li>• Pericardial tamponade on E-FAST</li><li>• Penetrating neck wounds with hard signs of vascular injury</li></ul>



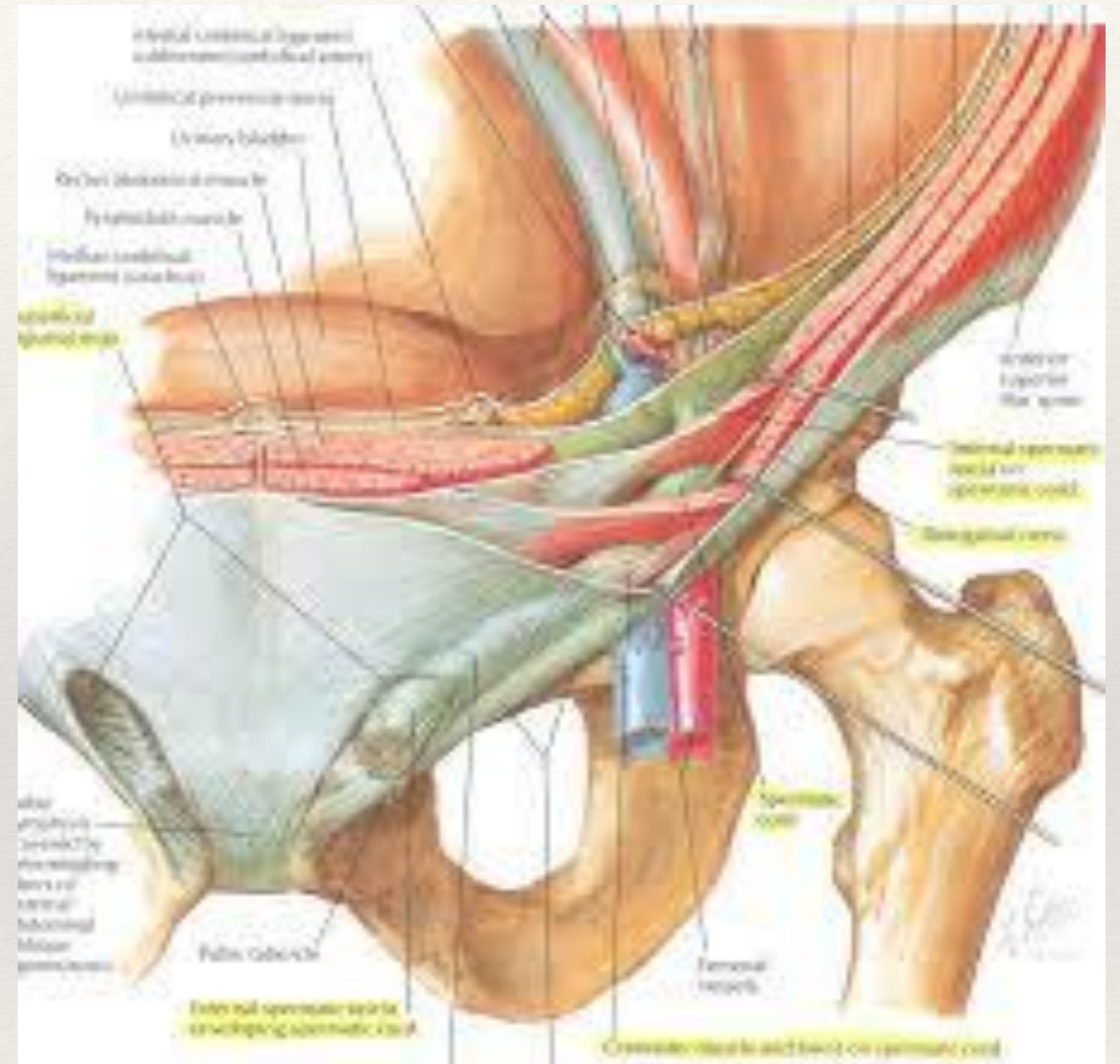






**a** alamy stock photo

CR3G7J  
www.alamy.com





# Damage-control Resuscitation

Permissive hypotension/  
Hypotensive resuscitation

Blood pressure targeted

Fluid restricted /controlled

Rapid definitive control of bleeding

Surgery

Interventional radiology

Transfusion

Prevention/treatment

Hypothermia

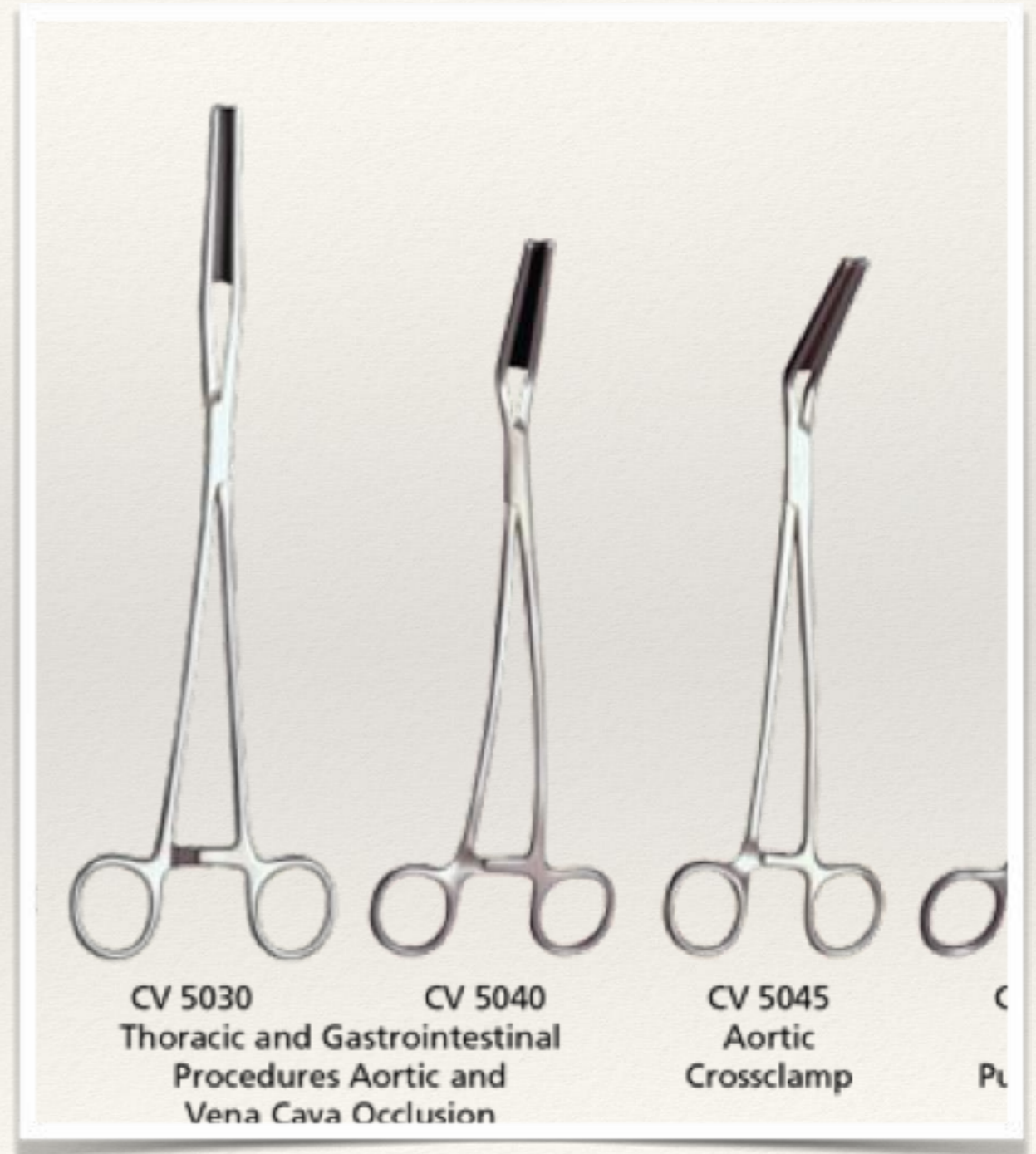Acidosis

Hypocalcaemia



# Intra Operative Management

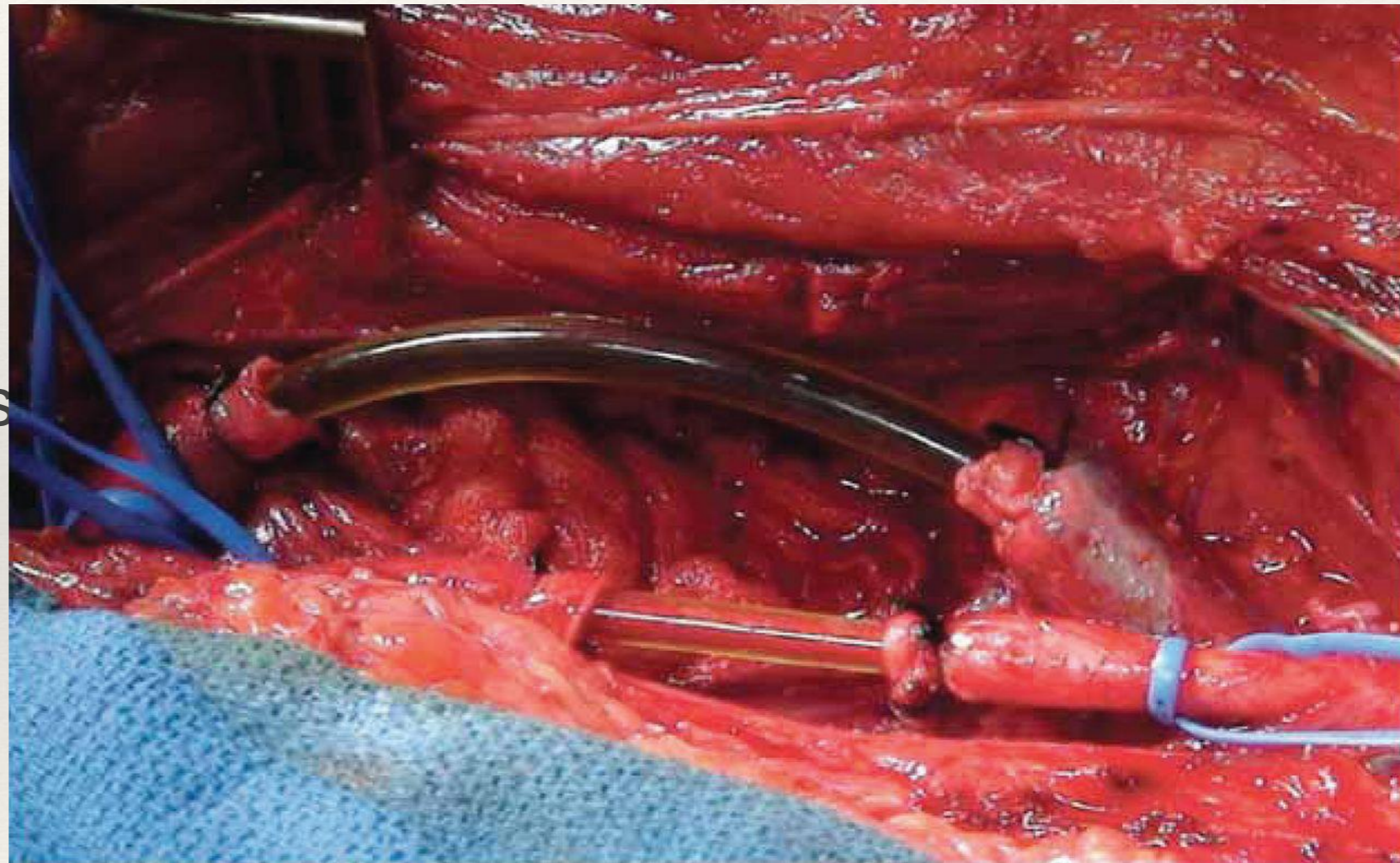
- ❖ Proximal Control
  - ❖ Pressure
  - ❖ Clamps
  - ❖ Balloons
- ❖ Phone a friend
- ❖ KNOW YOUR ANATOMY
- ❖ Each Site requires specific exposures





# Surgical Techniques

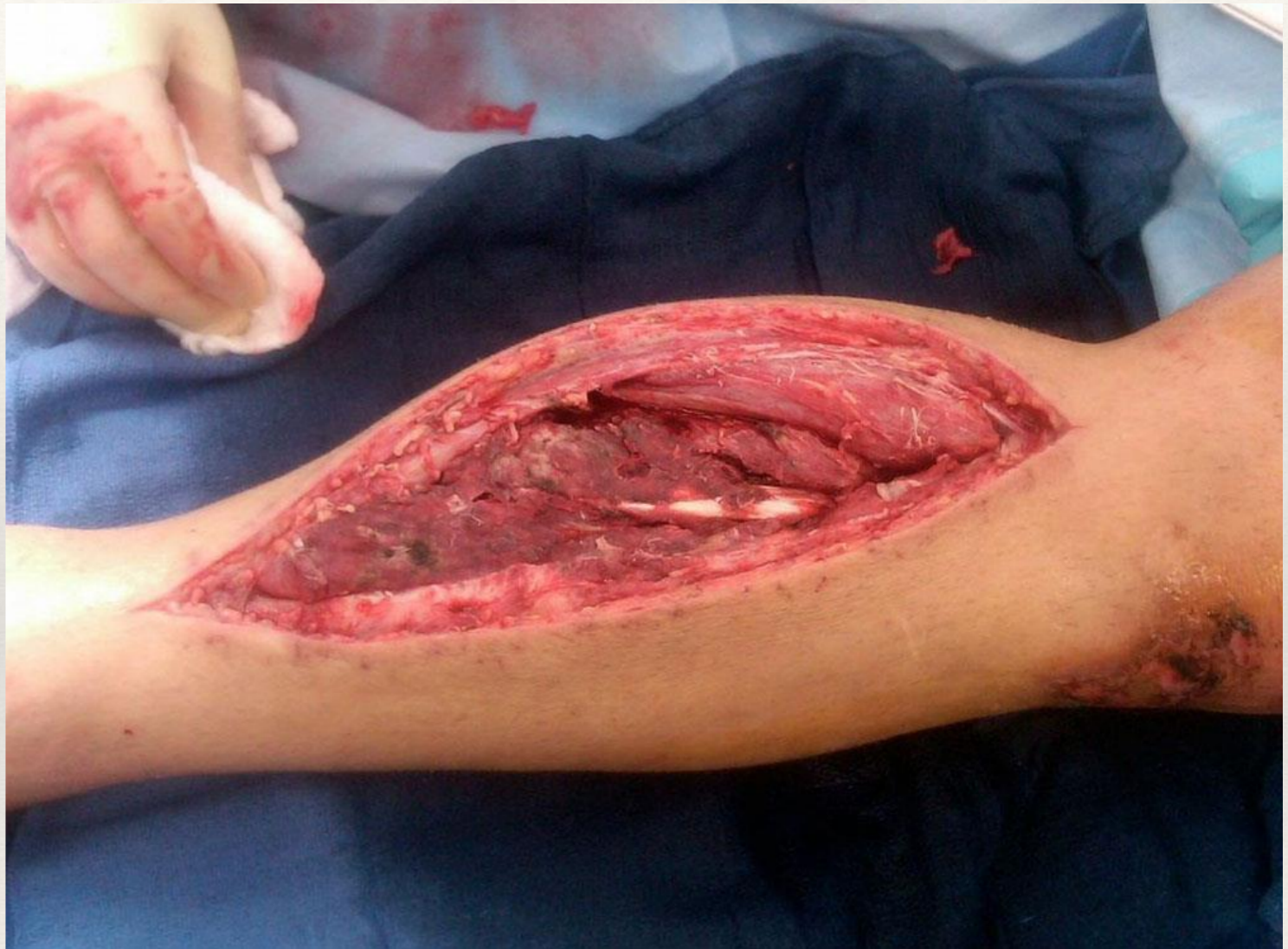- ❖ Lateral Suture
- ❖ Patch
- ❖ End to End anastamosis
- ❖ Interposition Graft
- ❖ Bypass Graft
- ❖ Ligation





# Post Operative Management

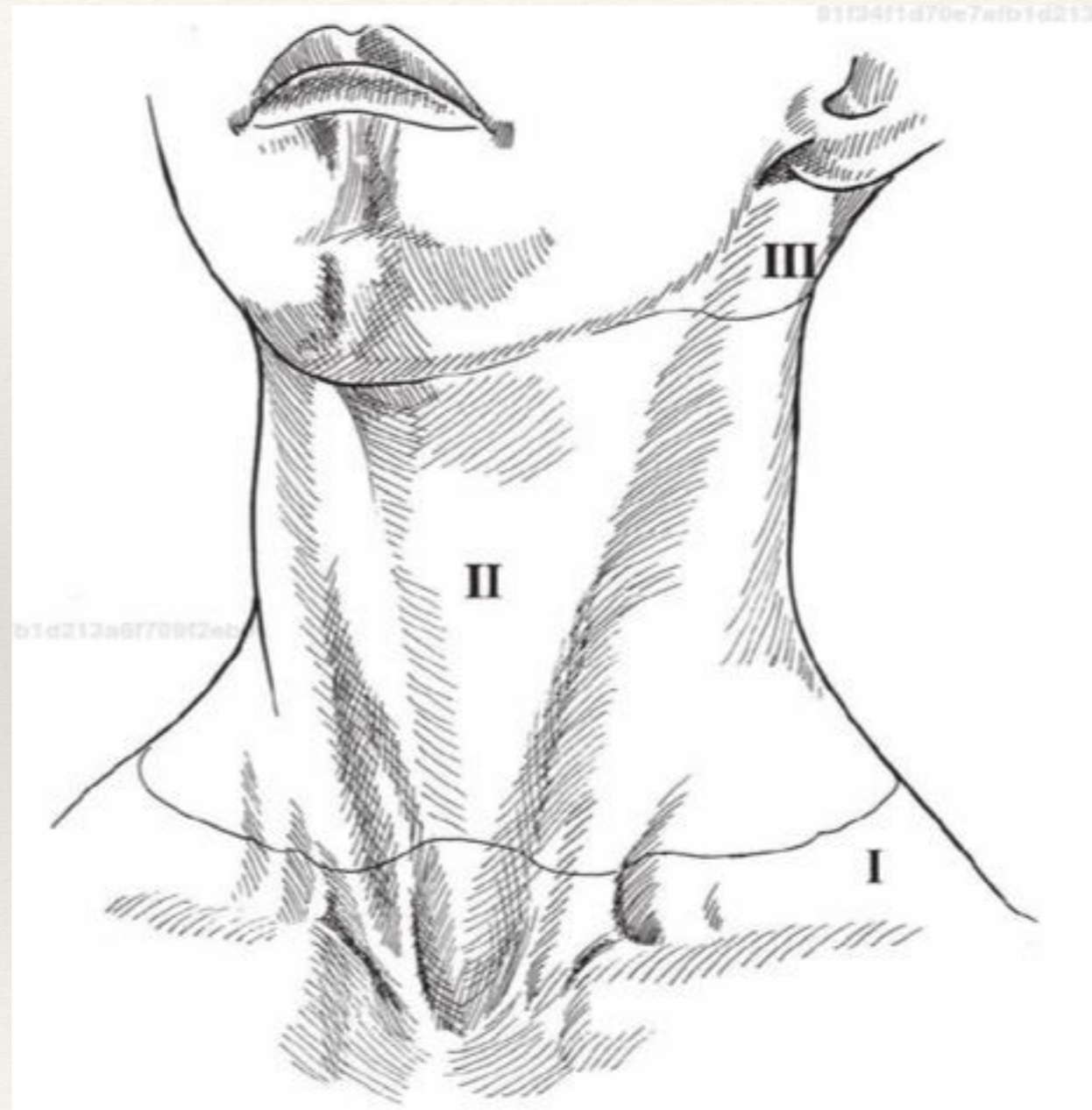
- ❖ Proximal Control
- ❖ Phone a friend
- ❖ Compartment Syndrome
- ❖ Positions
- ❖ PEEP
- ❖ Medications
  - ❖ DDAVP, TXA, Protamine, Heparin



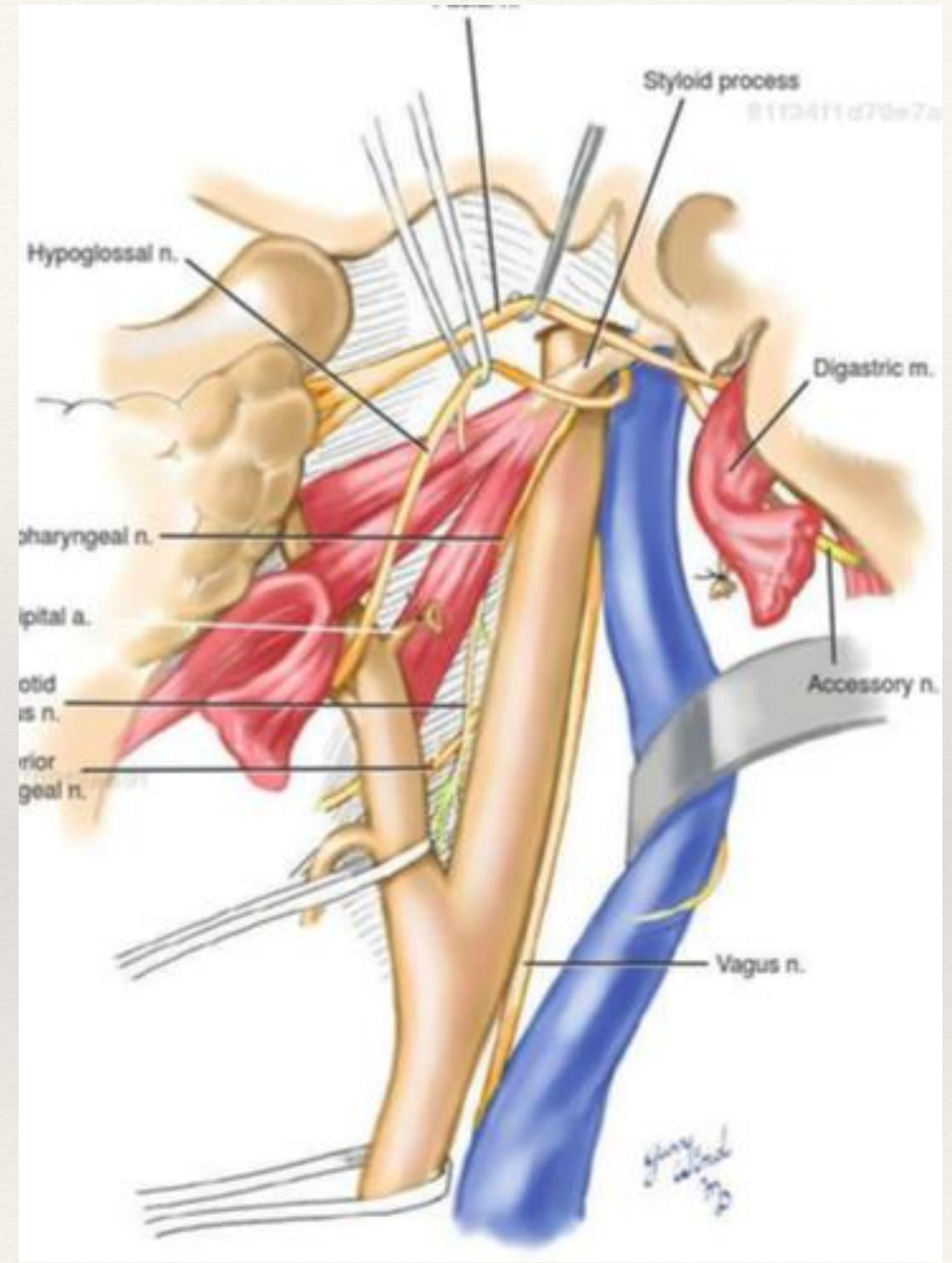
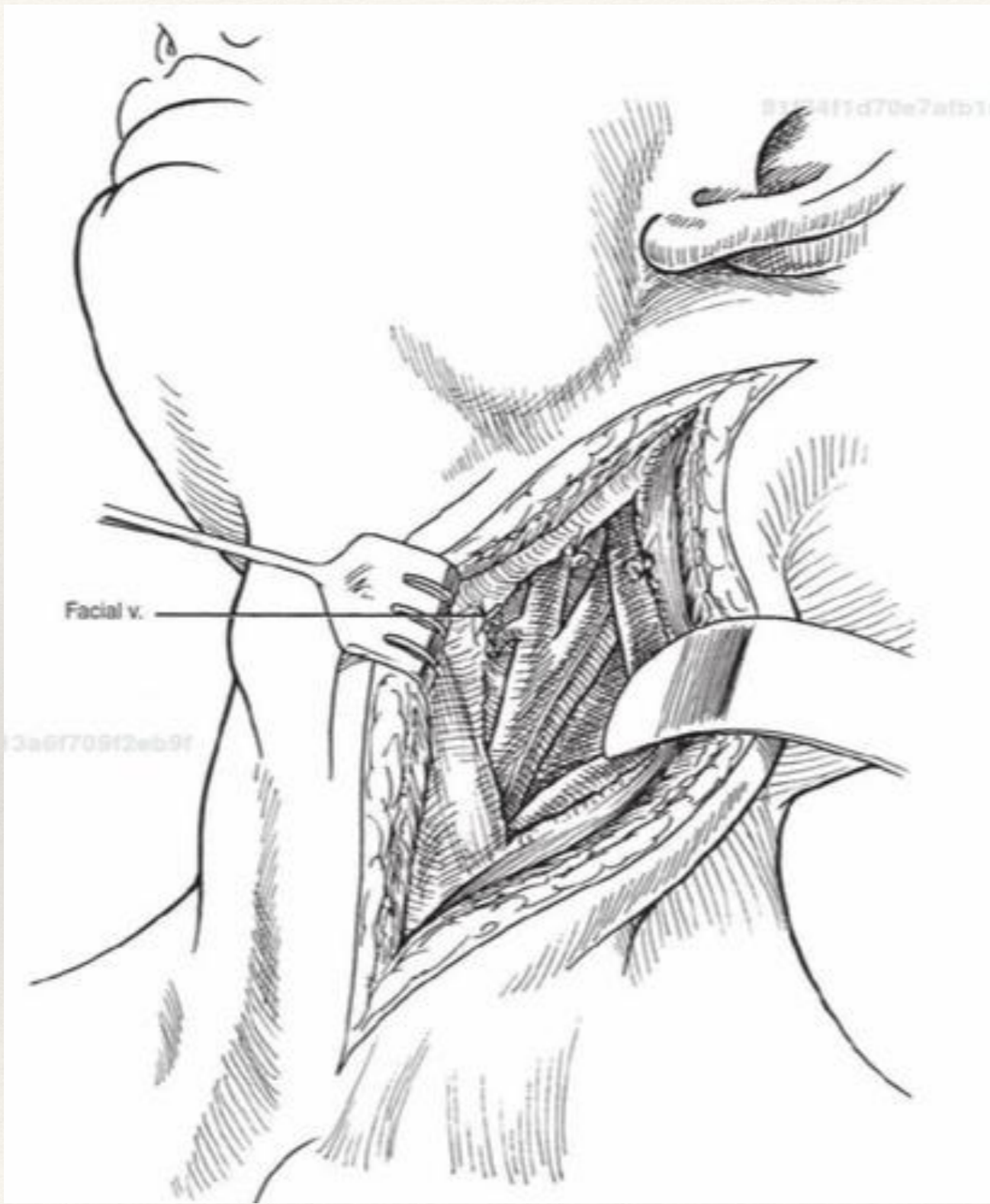


# Neck Stabbing

❖ Explore zone 2





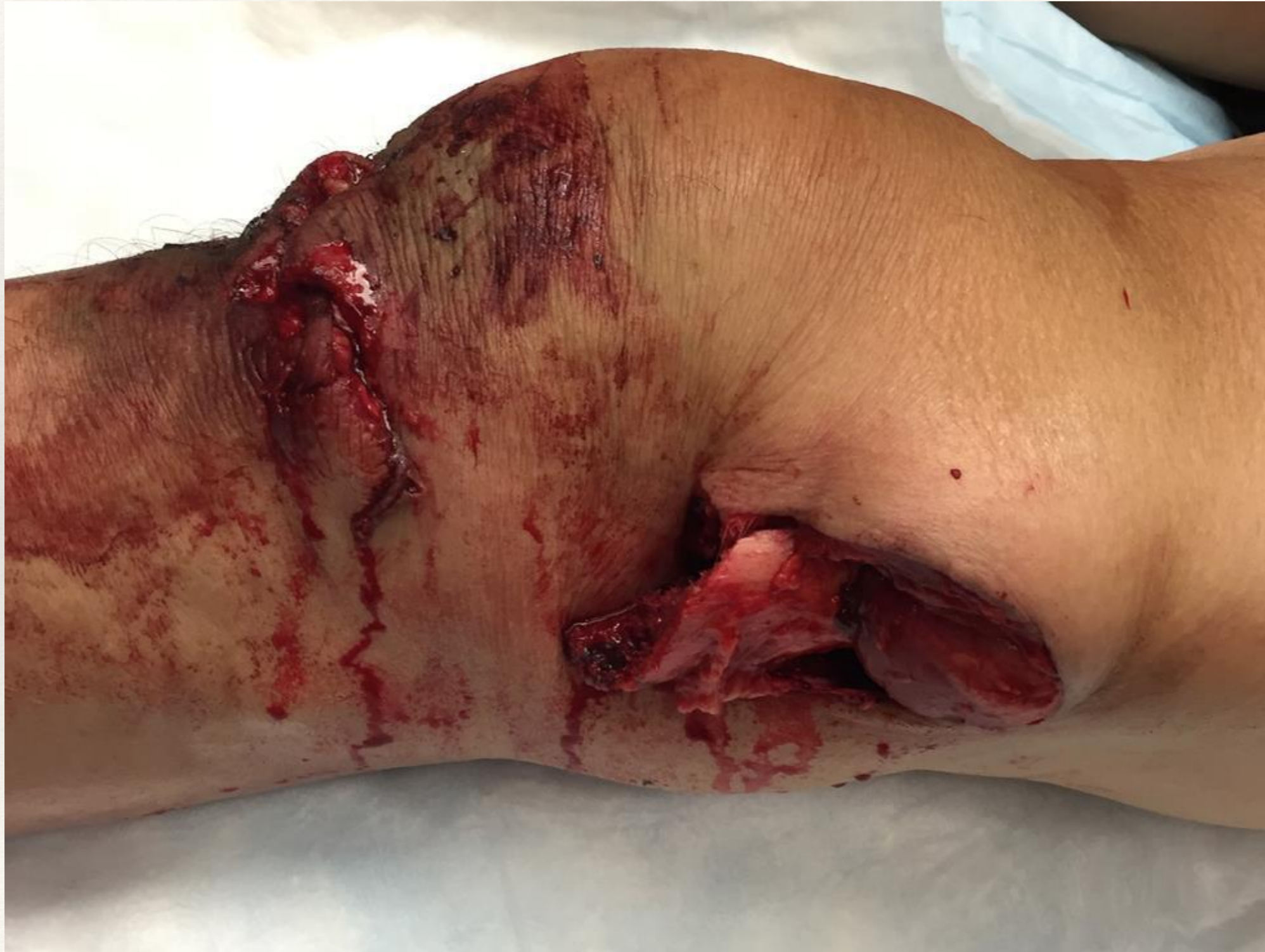



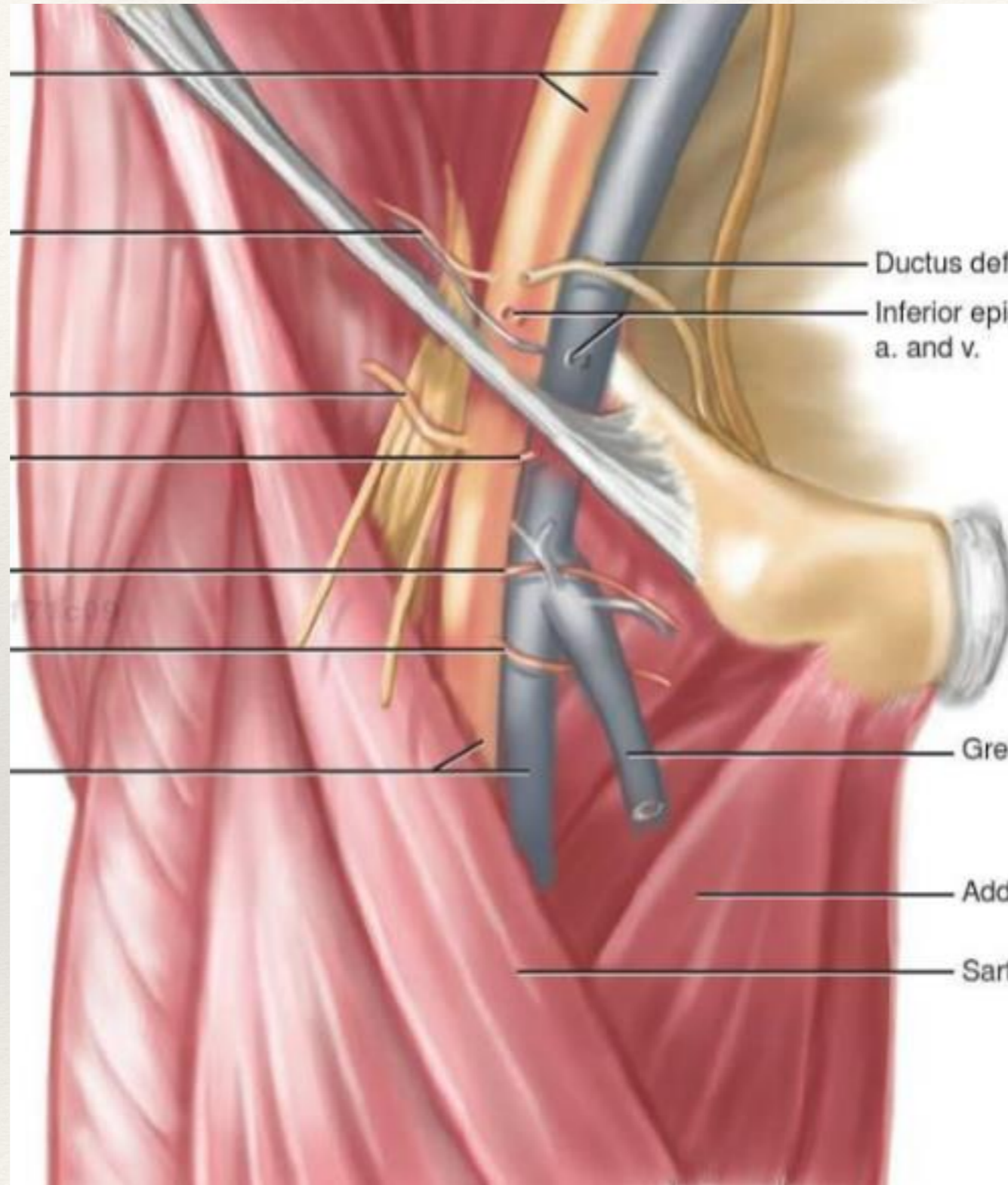
---

# Leg MBA

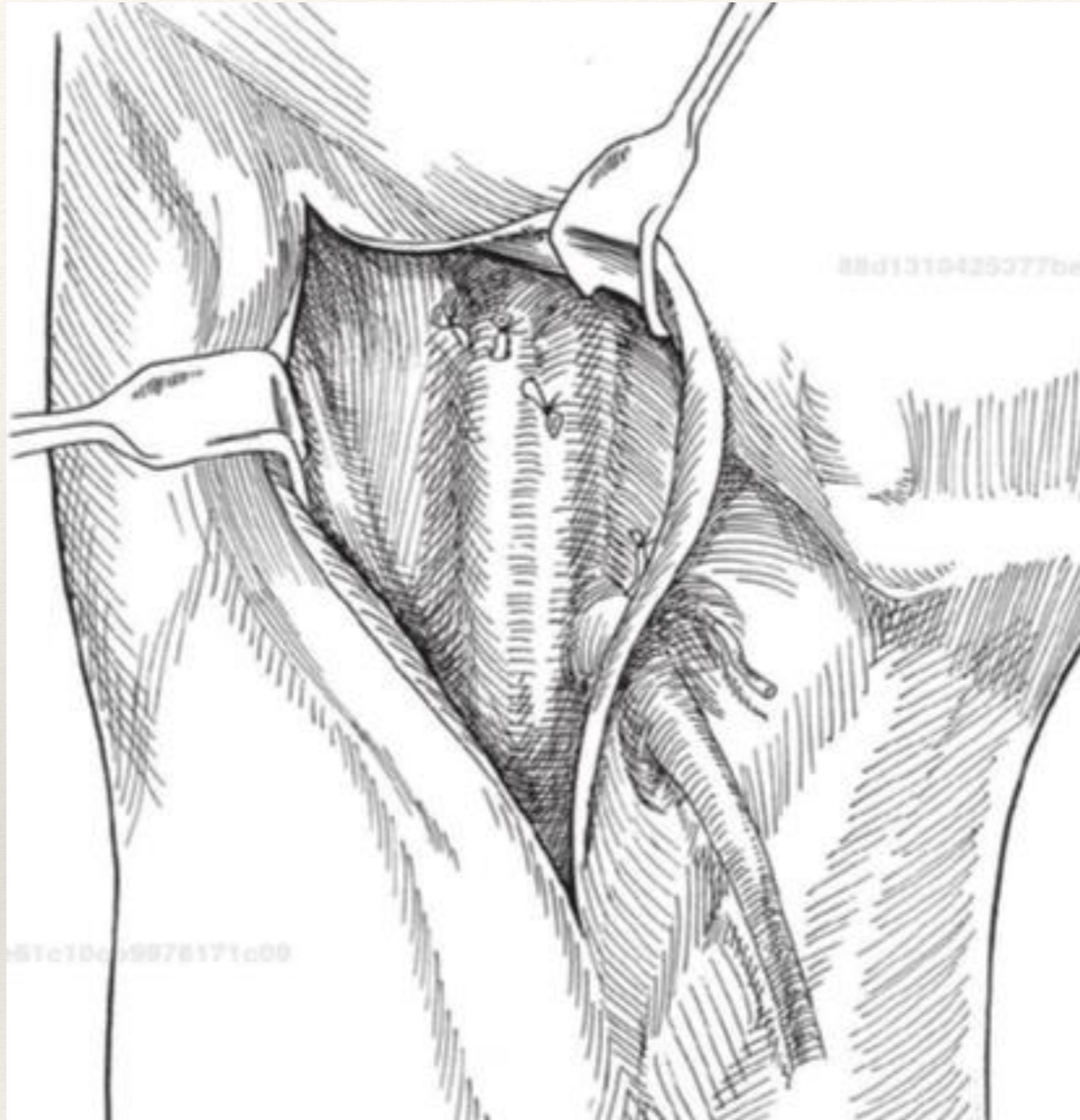
---





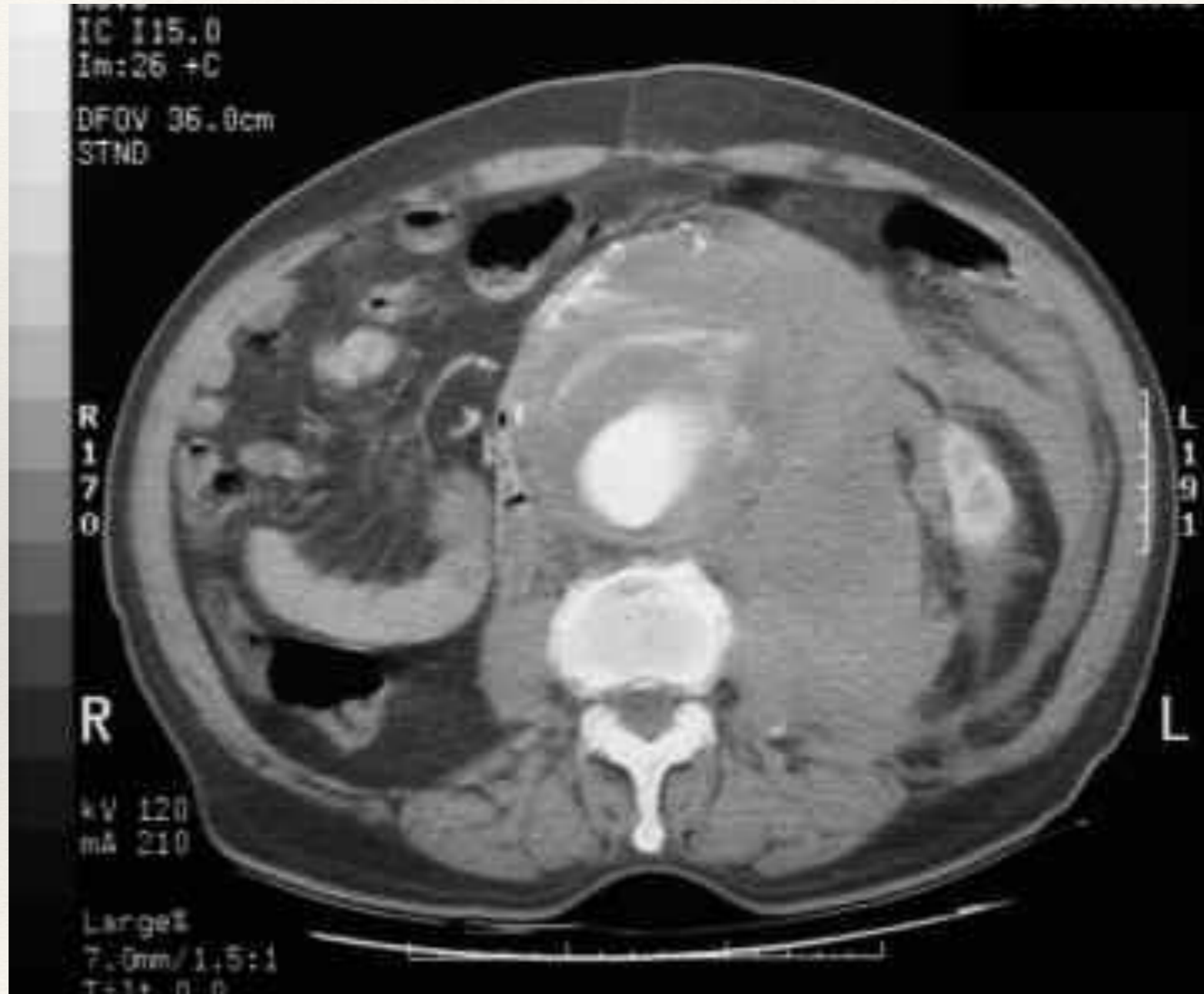



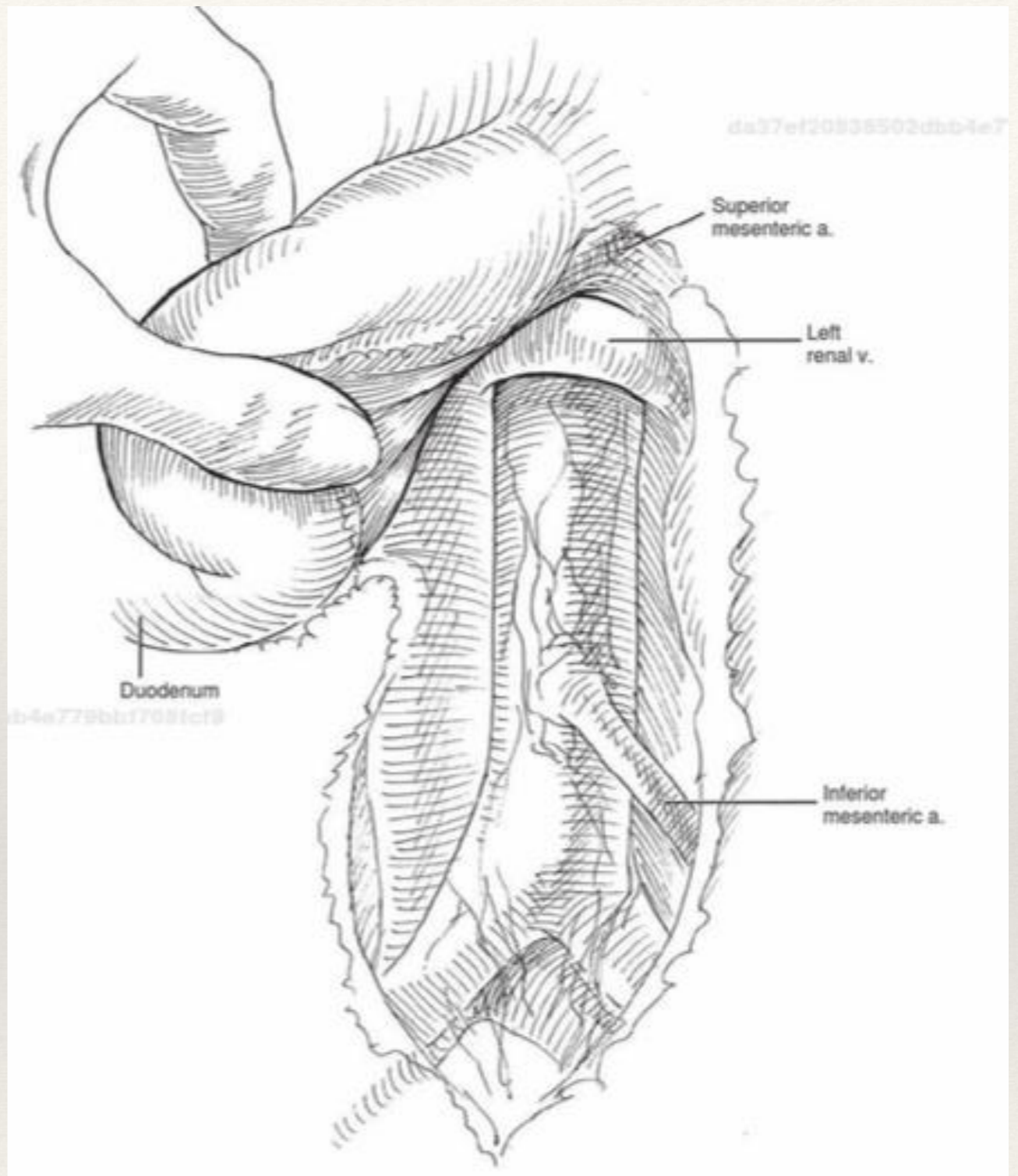
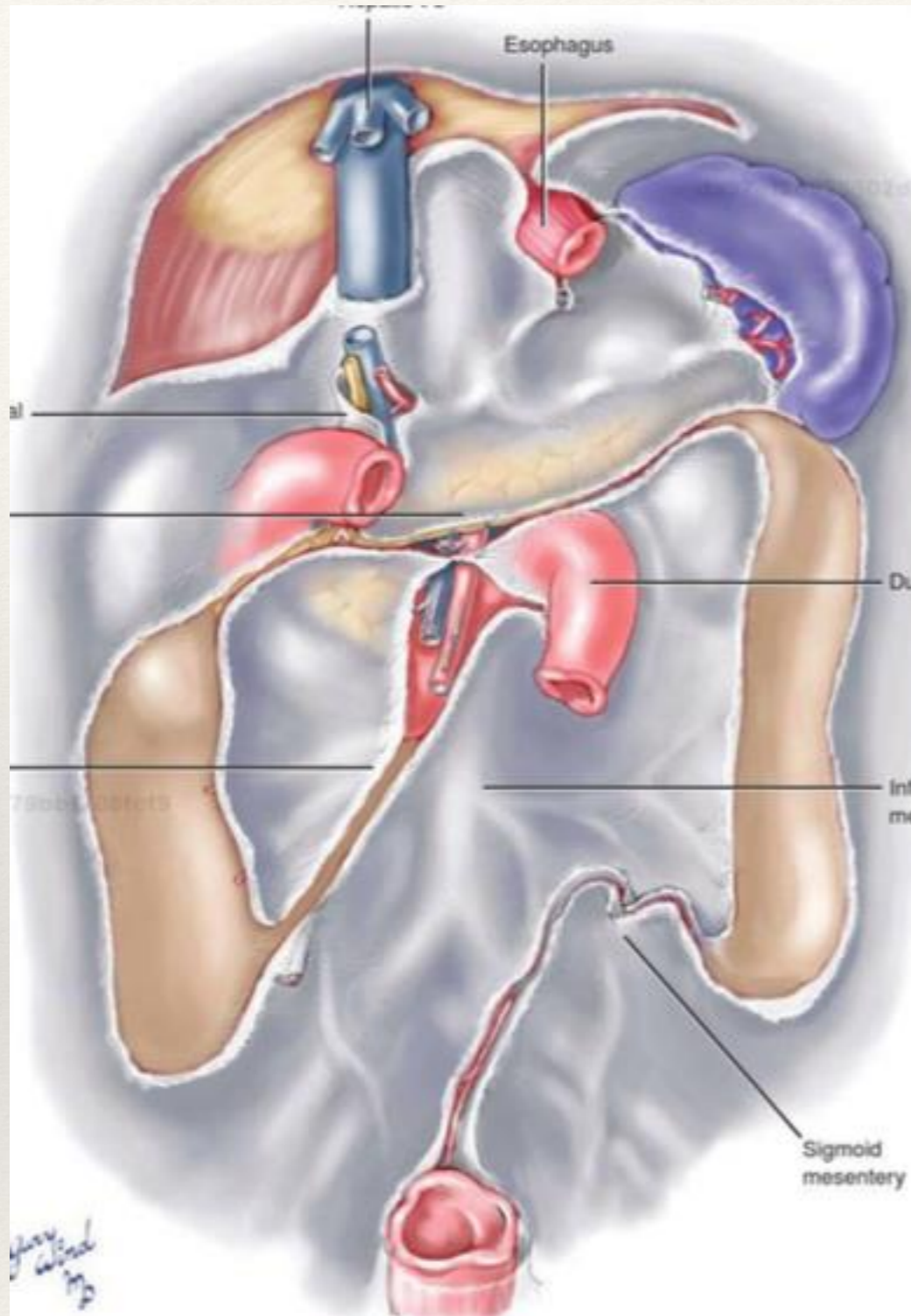




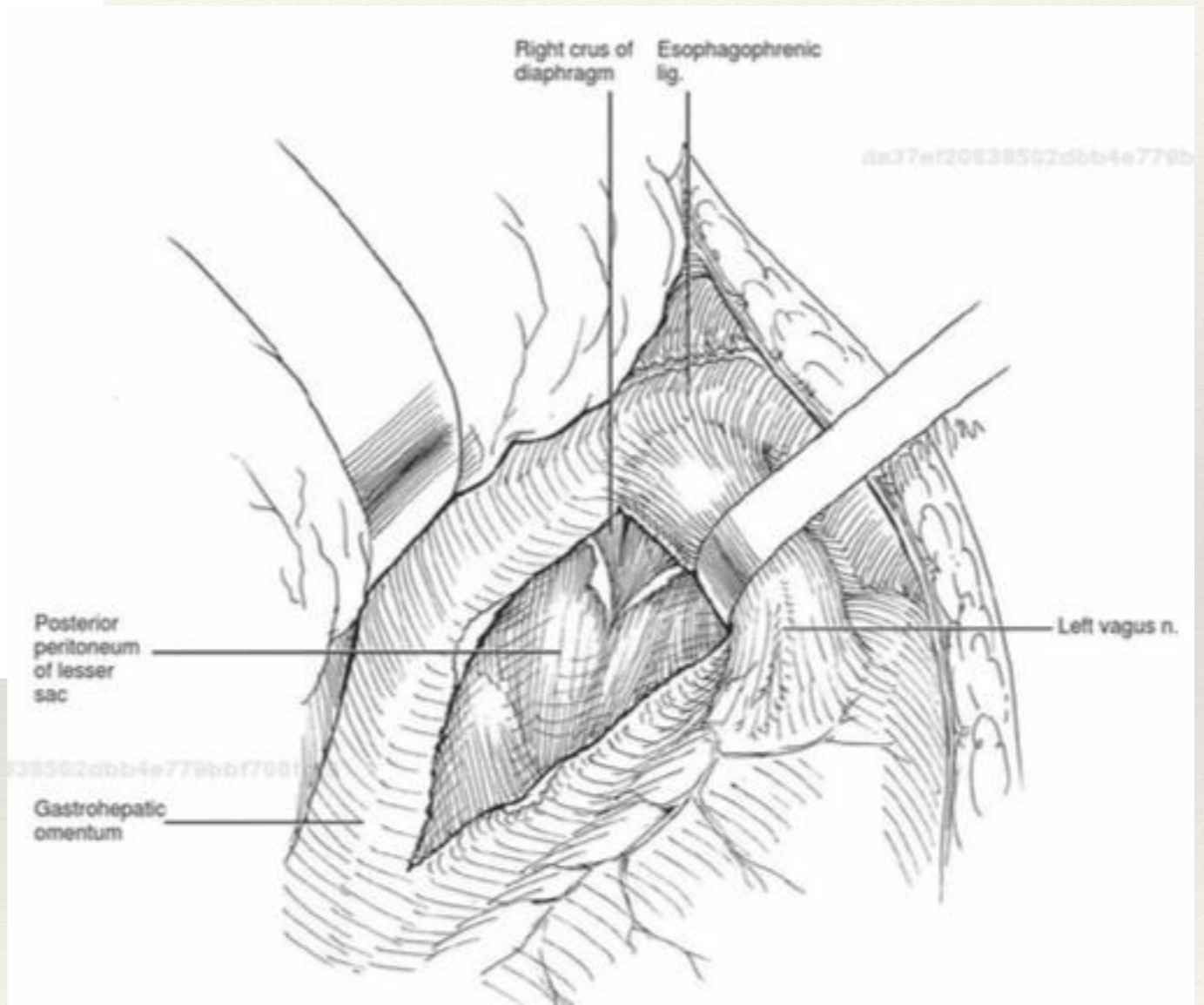
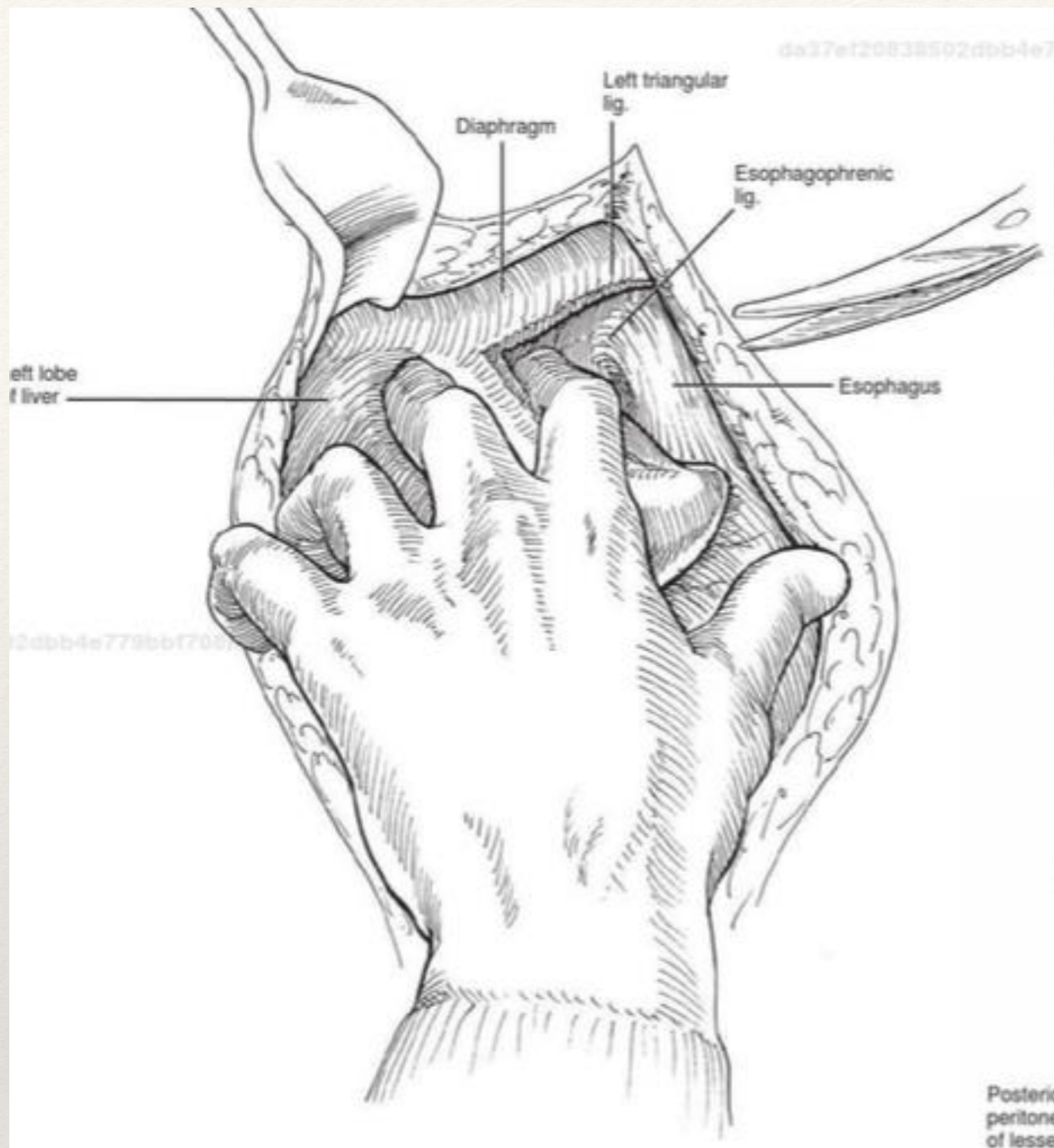
# Abdominal



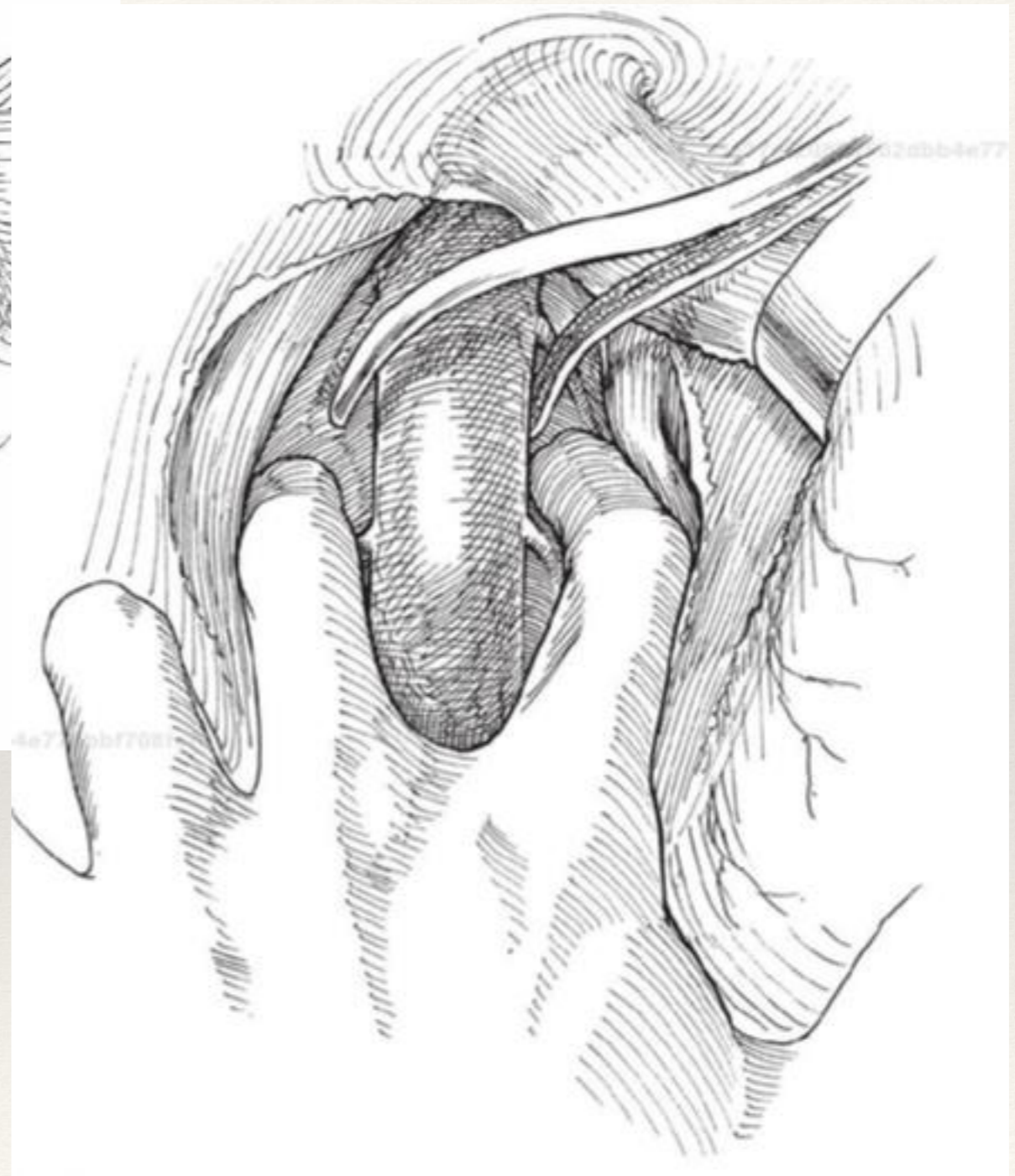
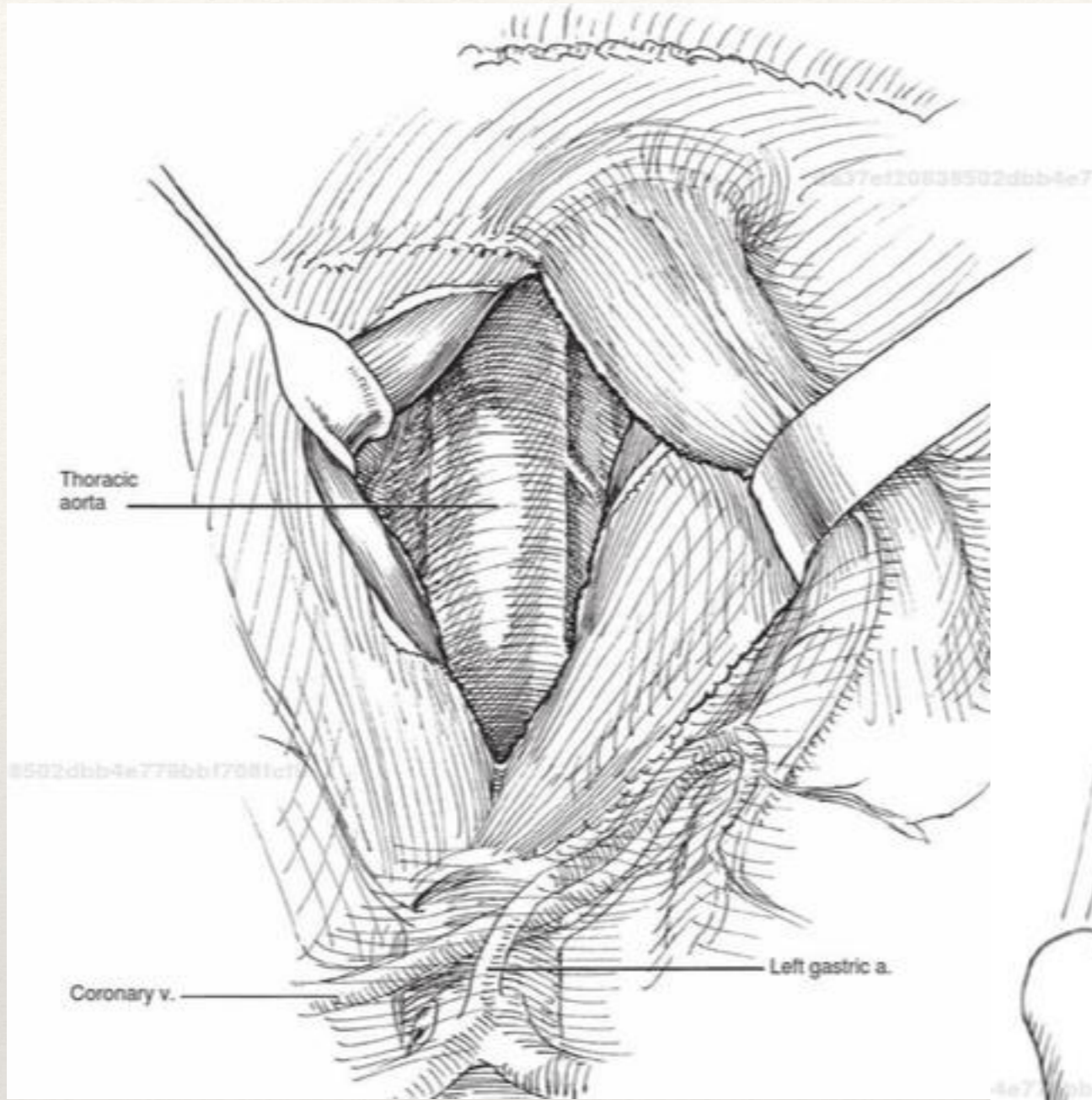









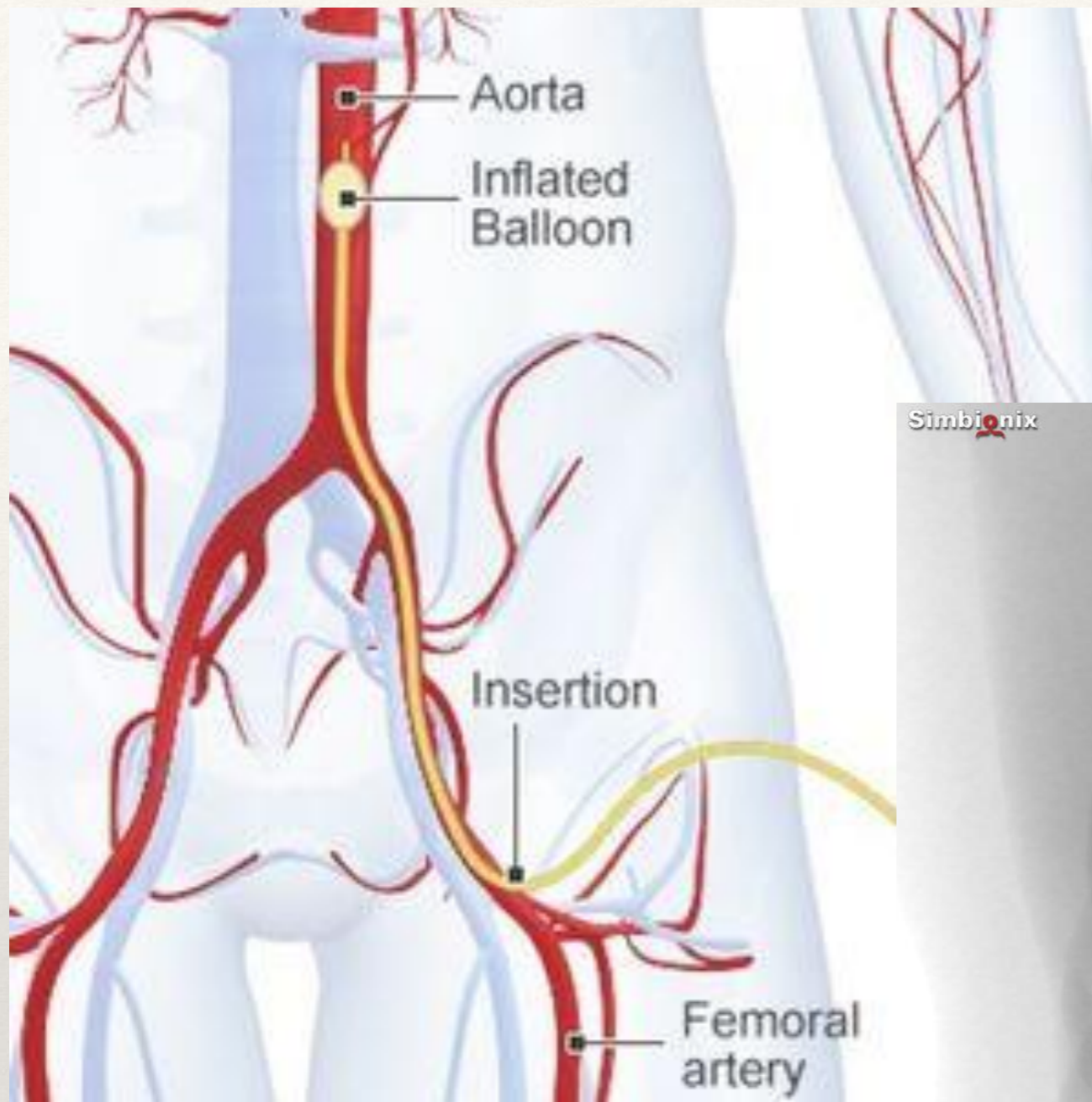






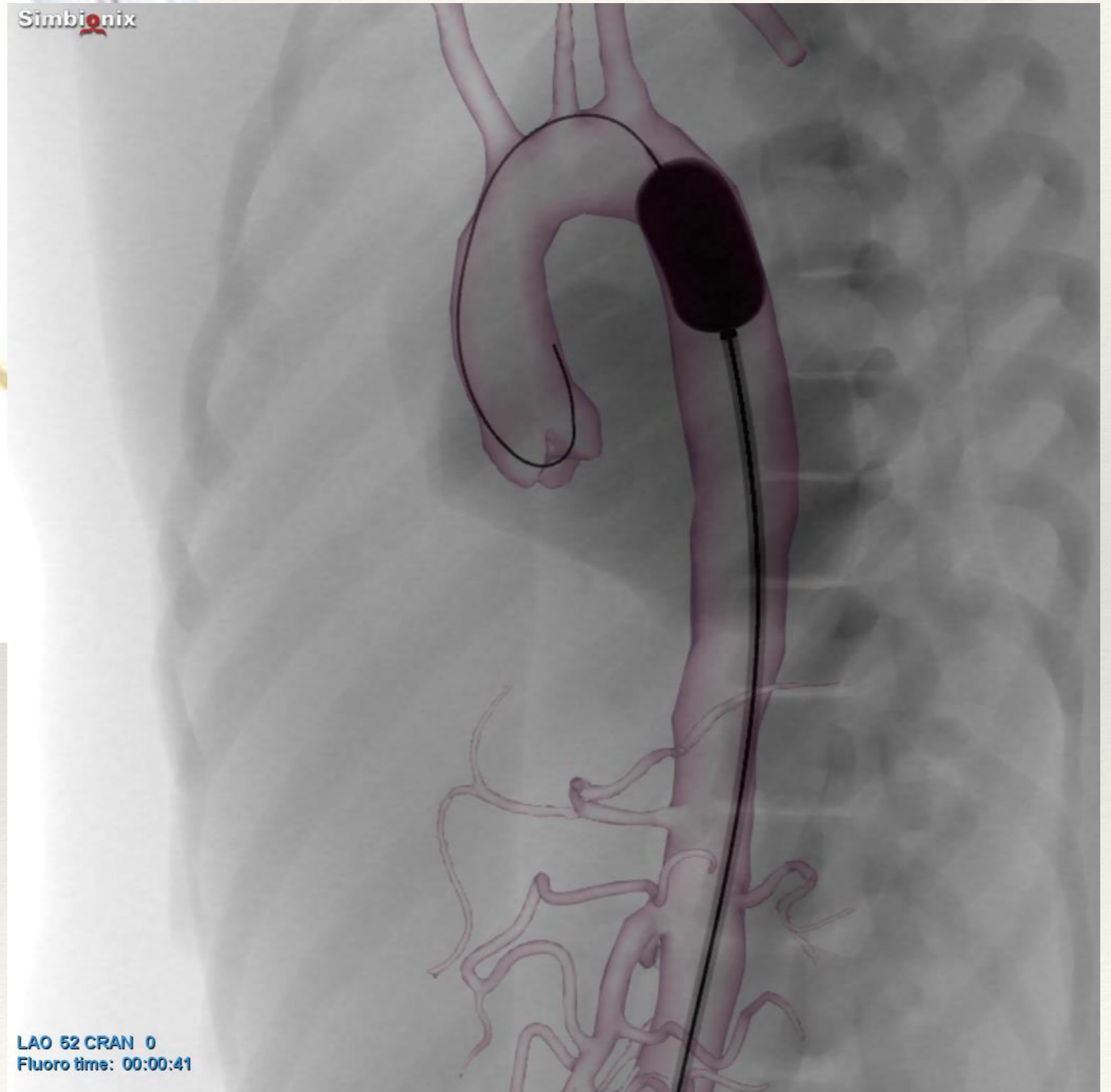






Simbionix

LAO 52 CRAN 0  
Fluoro time: 00:00:41

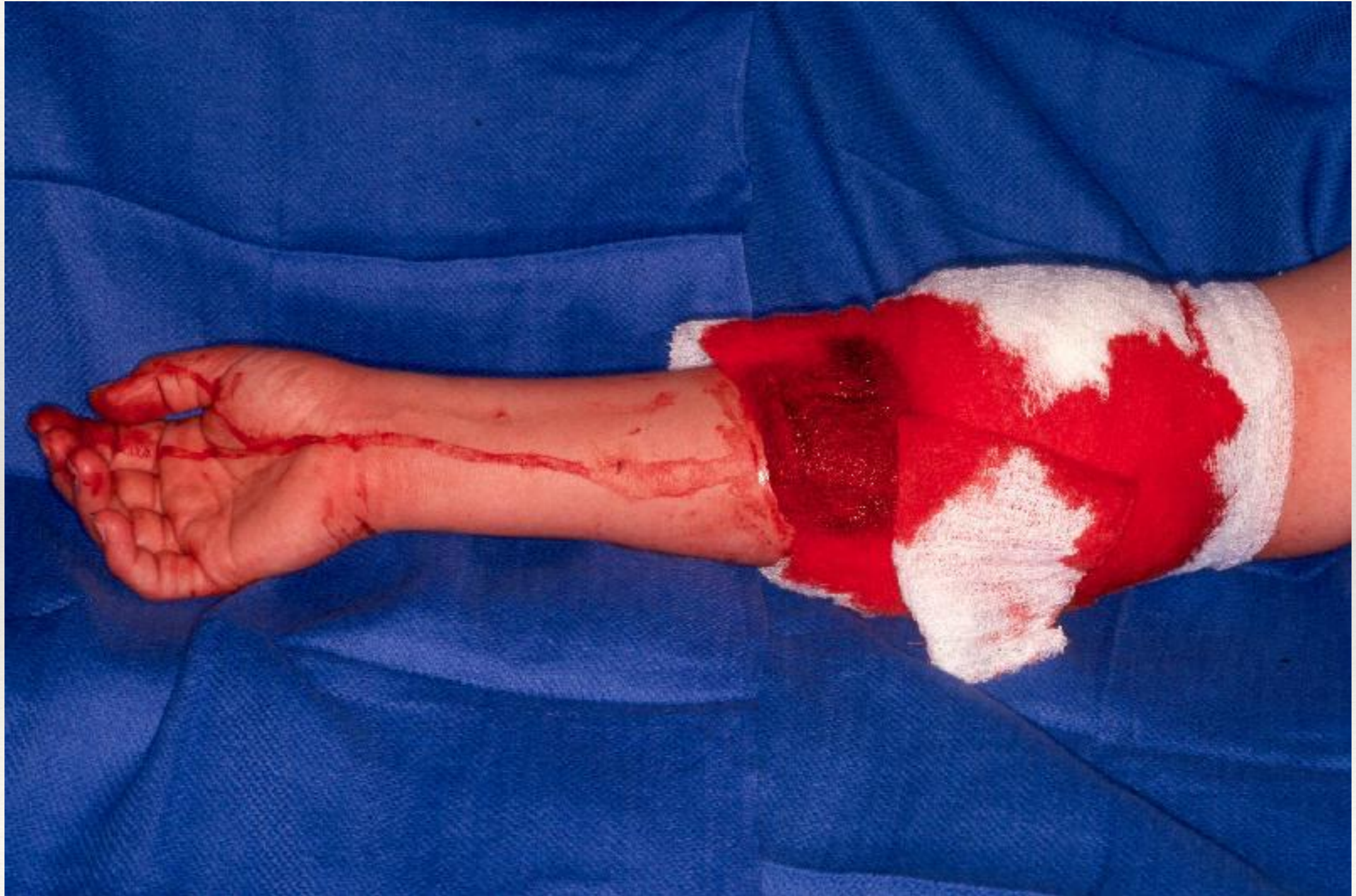



---

# Wrist

---

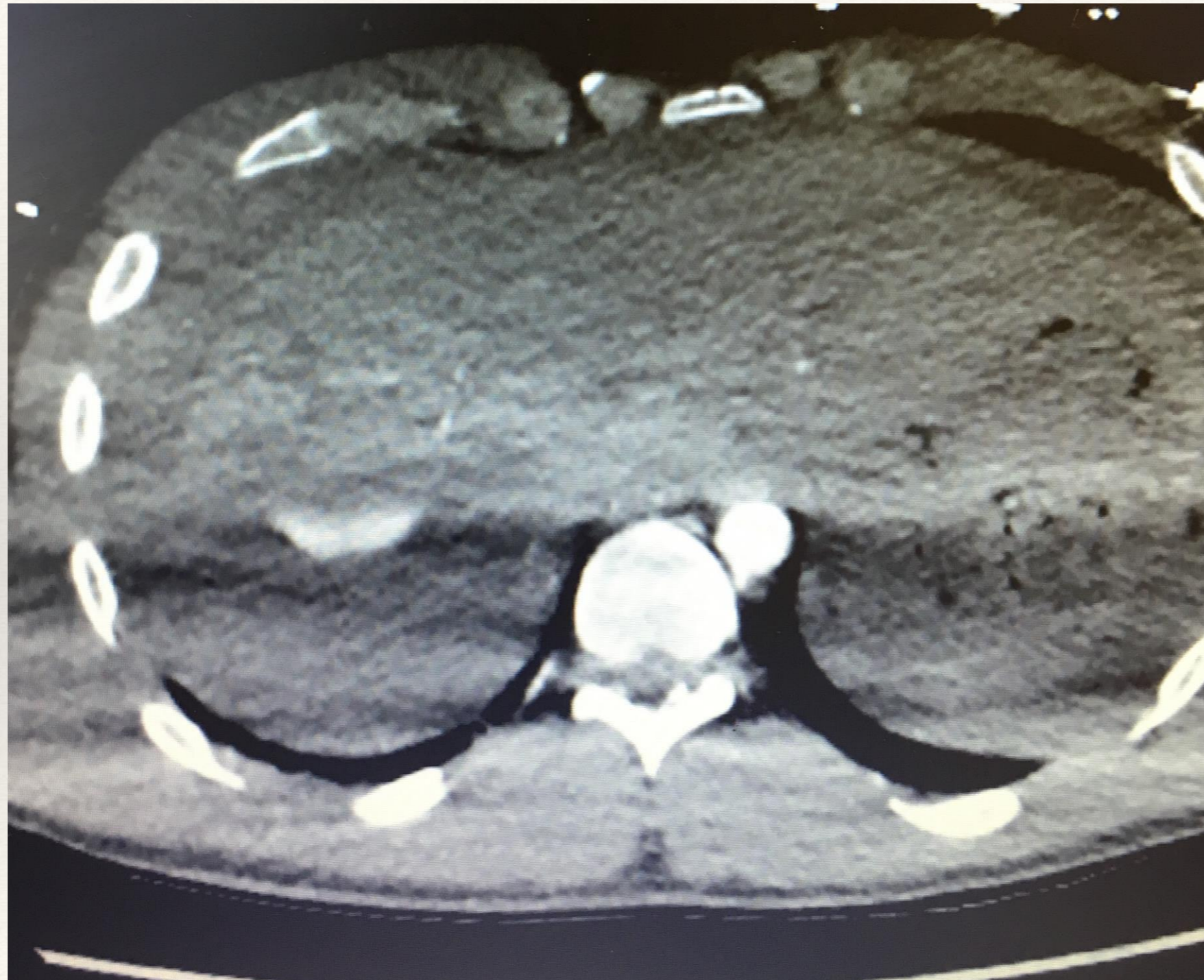



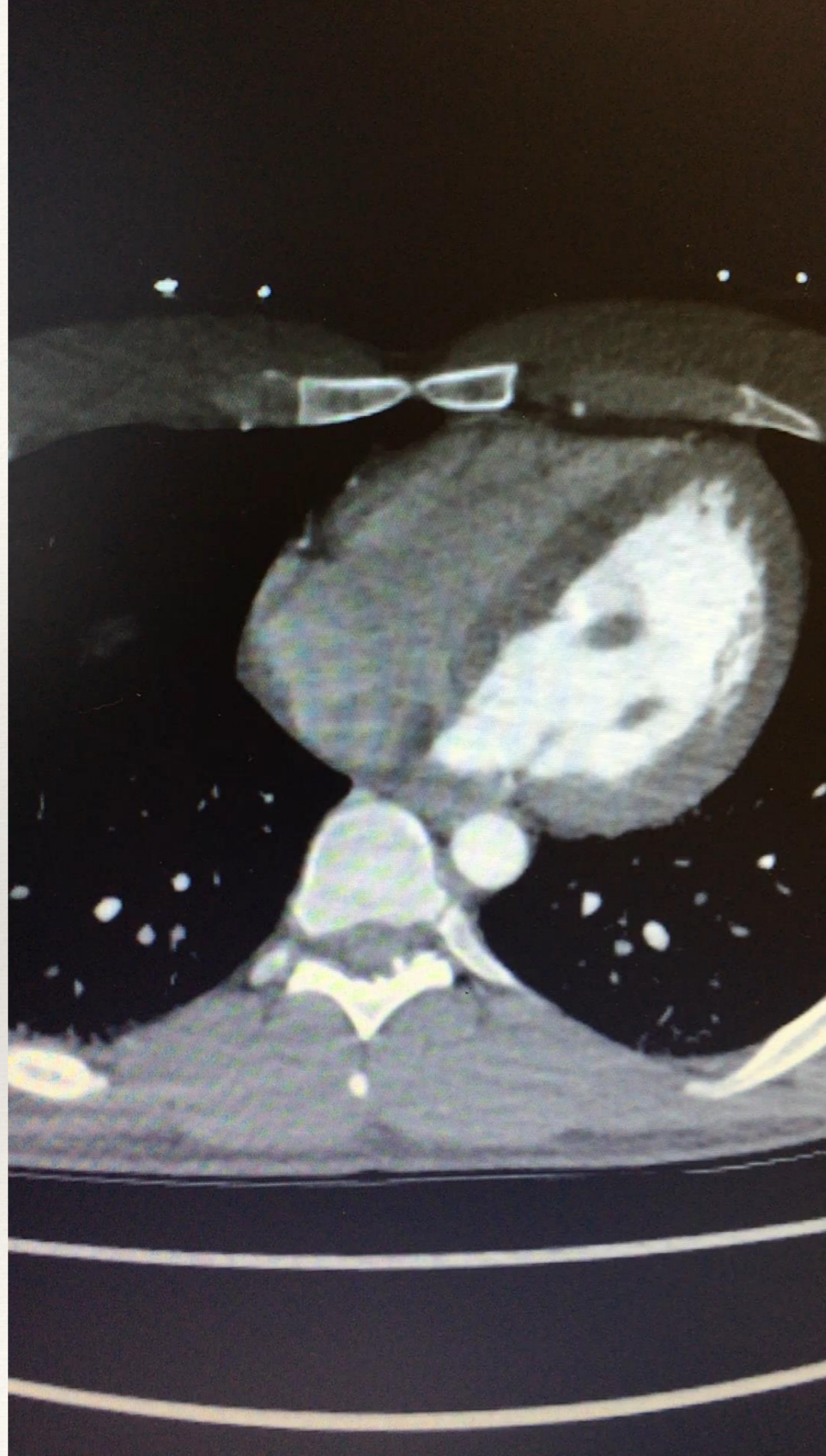---

# Liver

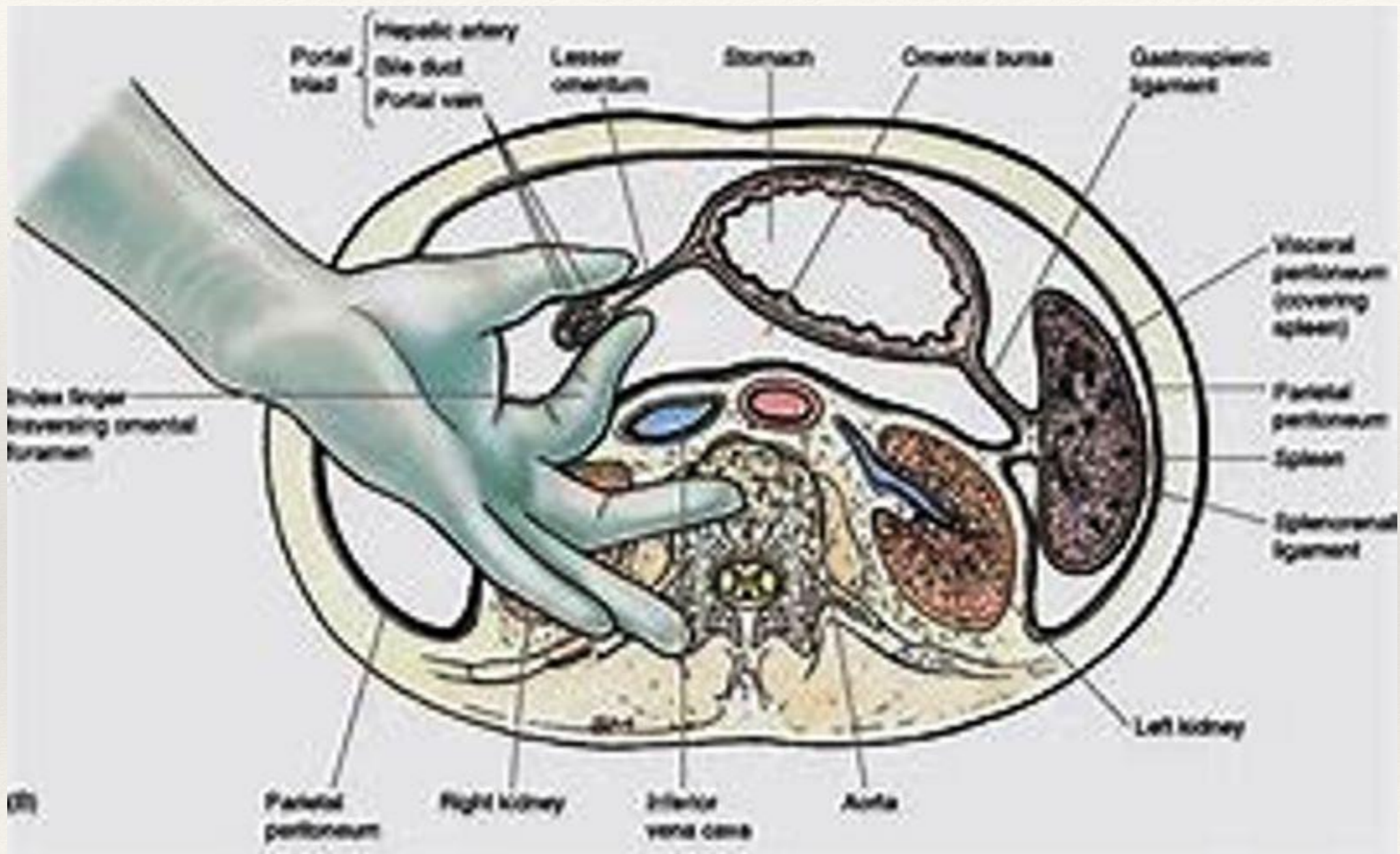
---



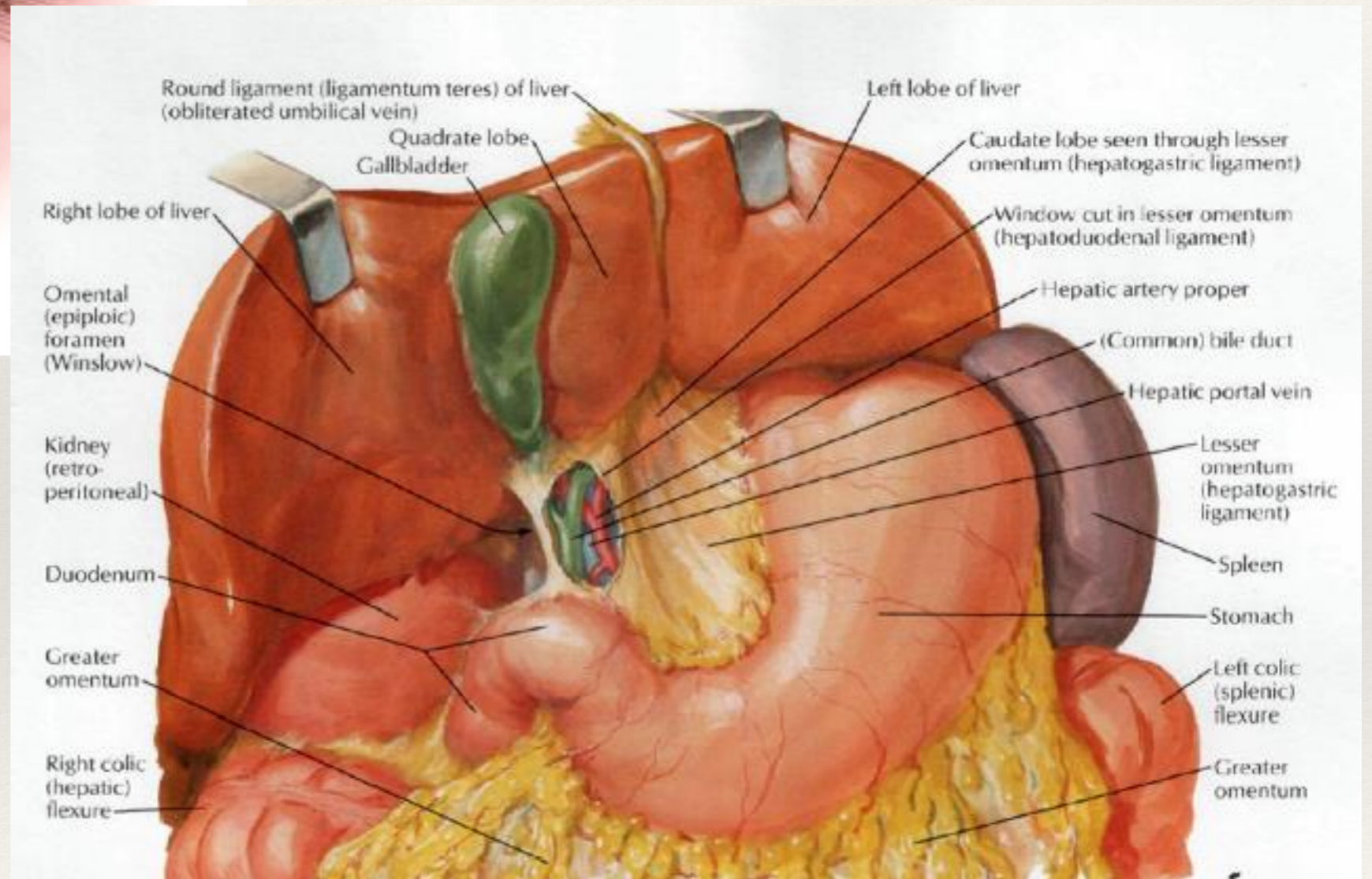
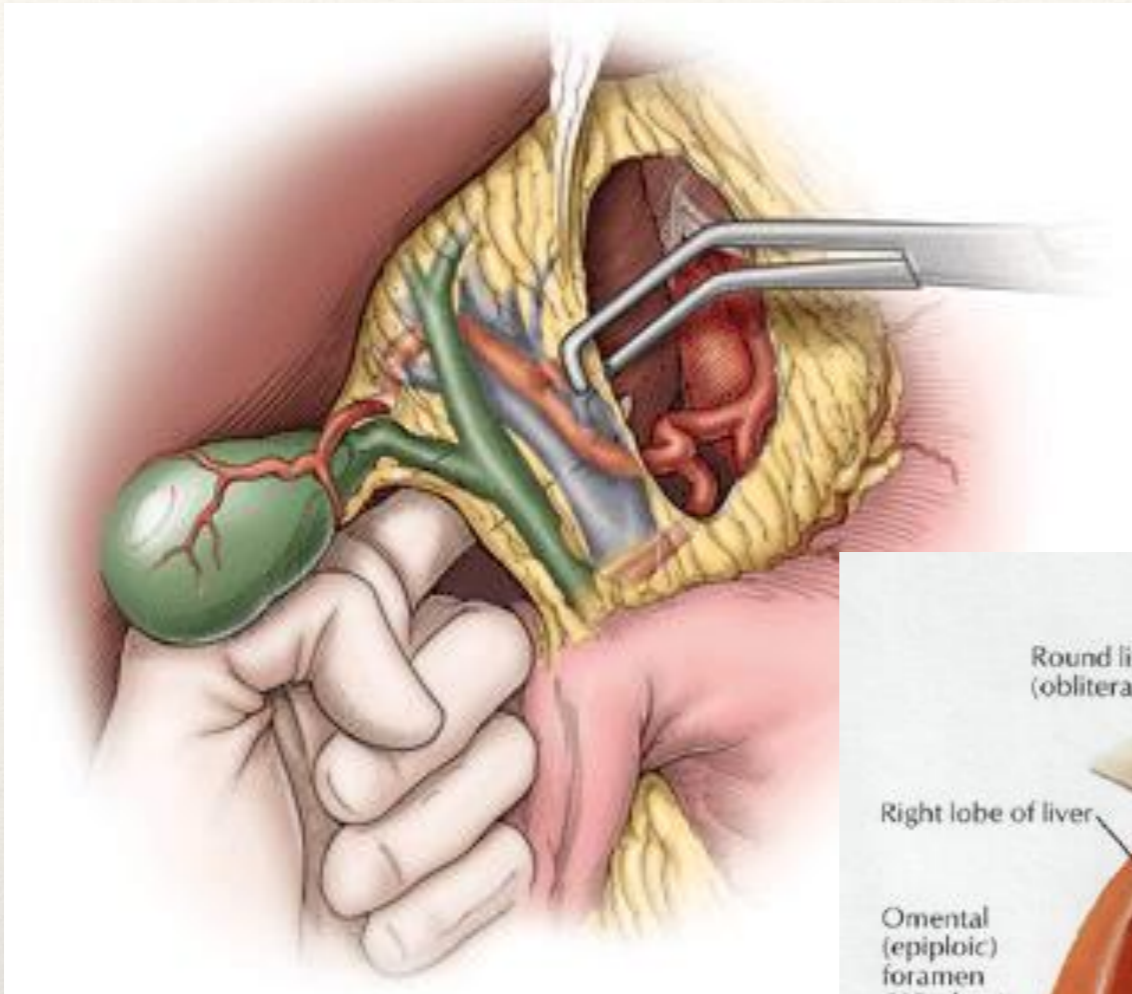




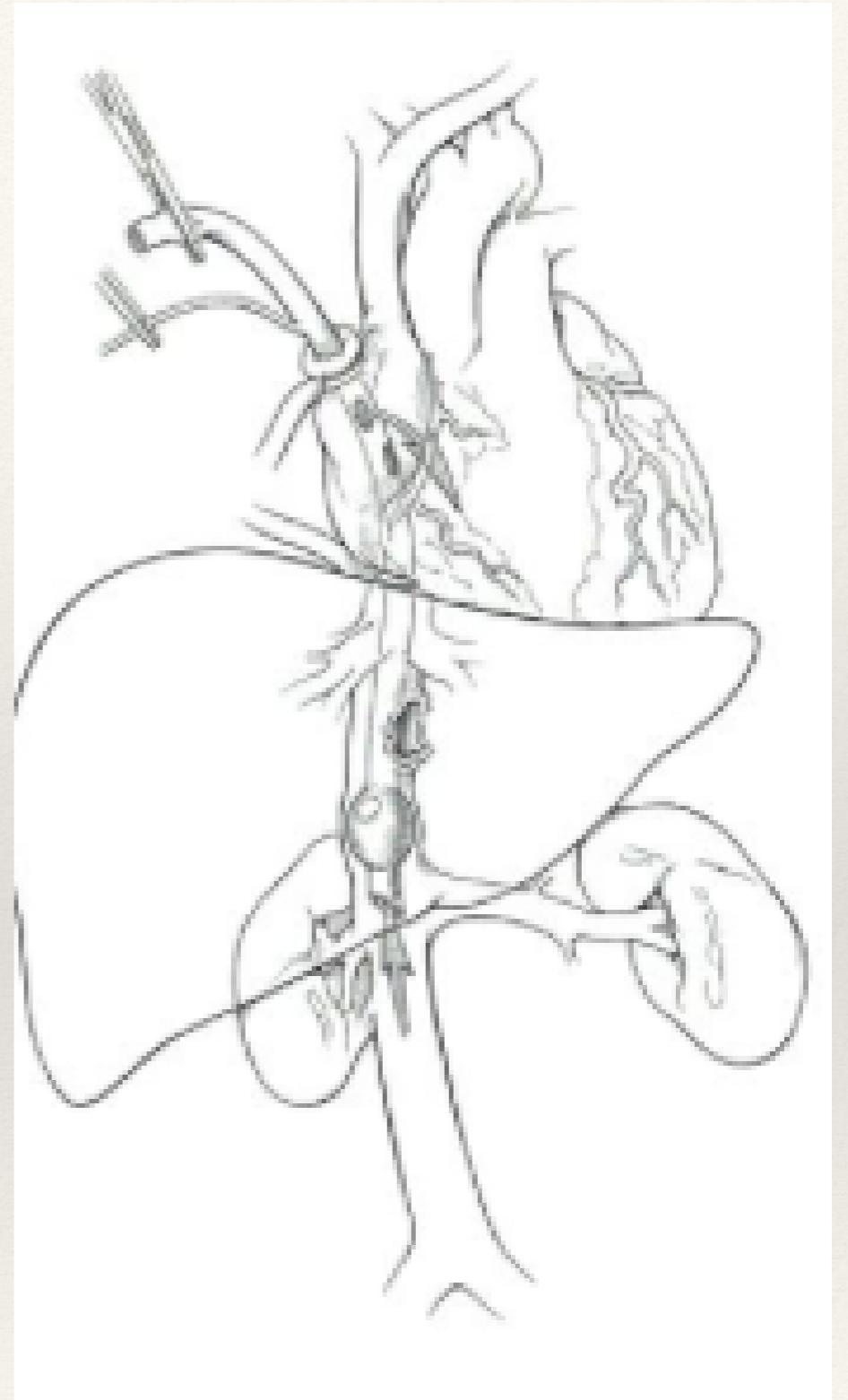
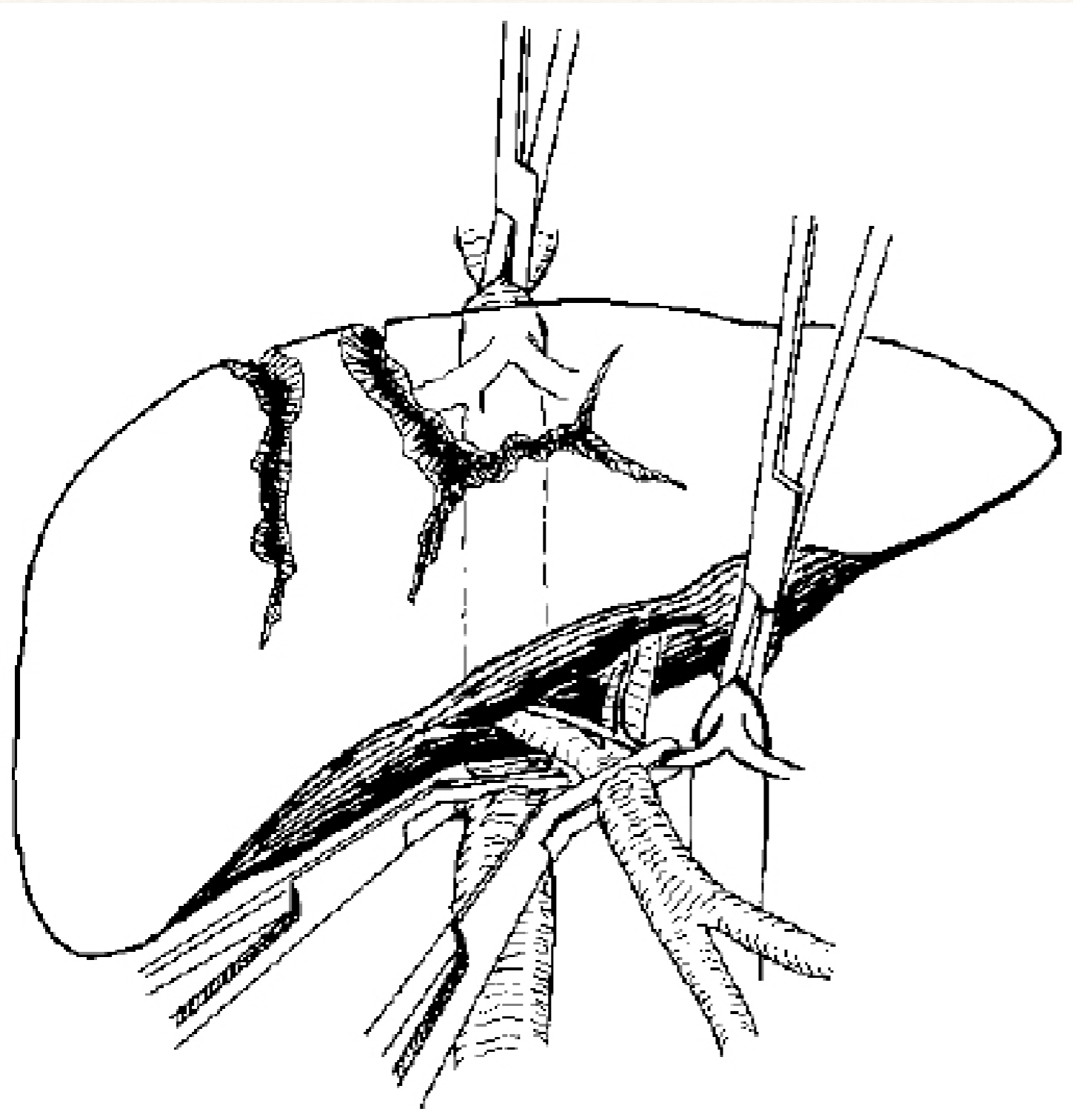














## Proximal Control

Correct the proline deficiency first then  
the coagulopathy will have a chance